

## **Splenectomy and chronic thromboembolic pulmonary hypertension**

Xavier Jaïs\*, Vincent Ioos\*, Carlos Jardim\*, Olivier Sitbon\*, Florence Parent\*, Abdul Hamid\*,  
Elie Fadel\*\*, Philippe Dartevelle\*\*, Gérald Simonneau\*, and Marc Humbert\*

(\*) UPRES EA 2705, Centre des Maladies Vasculaires Pulmonaires, Service de Pneumologie et Réanimation Respiratoire, Hôpital Antoine Bécclère, Assistance Publique-Hôpitaux de Paris, Université Paris Sud, Clamart, France.

(\*\*) UPRES EA 2705, Service de Chirurgie Thoracique, Vasculaire et de Transplantation Pulmonaire, Centre Chirurgical Marie Lannelongue, Université Paris Sud, Le Plessis Robinson, France.

Correspondence to Xavier Jaïs, MD, Centre des Maladies Vasculaires Pulmonaires, Service de Pneumologie et Réanimation Respiratoire, Hôpital Antoine Bécclère, 157 rue de la Porte-de-Trivaux, 92140 Clamart, France.

Tel : + 33 1 45 37 47 76

Fax : + 33 1 46 30 38 24

E-mail : [xavier.jais@abc.ap-hop-paris.fr](mailto:xavier.jais@abc.ap-hop-paris.fr)

This study was supported by grants from Université Paris-Sud and Legs Poix.

The corresponding author has the right to grant on behalf of all authors and does grant on behalf of all authors, an exclusive licence (or non exclusive for government employees) on a worldwide basis to the BMJ Publishing Group Ltd and its Licensees to permit this article (if accepted) to be published in THORAX editions and any other BMJGP Ltd products to explore all subsidiary rights, as set in our licence.

**ABSTRACT**

An increased prevalence of splenectomy has been reported in patients with idiopathic pulmonary arterial hypertension. Examination of small pulmonary arteries from these subjects revealed multiple thrombotic lesions, suggesting that thrombosis may contribute to this condition. Based on these findings, we hypothesized that splenectomy could be a risk factor for chronic thromboembolic pulmonary hypertension, a condition defined by the absence of thrombus resolution after acute pulmonary embolism that causes sustained obstruction of the pulmonary arteries and subsequent pulmonary hypertension. We reviewed the medical history, clinical characteristics, thrombotic risk factors and haemodynamics of 257 patients referred for chronic thromboembolic pulmonary hypertension between 1989 and 1999. In a case-control study, the prevalence of splenectomy in chronic thromboembolic pulmonary hypertension was compared to that of patients evaluated during the same period for idiopathic pulmonary hypertension (n= 276) or for lung transplantation in other chronic pulmonary conditions (n= 180). In patients with chronic thromboembolic pulmonary hypertension, 8.6% (CI 95%, [5.2-12.0%]) had a history of splenectomy, as compared to 2.5% (CI 95%, [0.7-4.4%]) and 0.56% (CI 95%, [0-1.6%]) in cases of idiopathic pulmonary arterial hypertension and other chronic pulmonary conditions, respectively (p<0.01). We conclude that splenectomy may be a risk factor for chronic thromboembolic pulmonary hypertension.

**KEY-WORDS:**

Chronic thromboembolic pulmonary hypertension,

Pulmonary arterial hypertension

Pulmonary hypertension

Splenectomy

Venous thromboembolic disease

## INTRODUCTION

Chronic thromboembolic pulmonary disease is a cause of pulmonary hypertension (1-8). The condition is defined by the absence of thrombus resolution after one or more episodes of acute pulmonary embolic event that causes sustained obstruction of the pulmonary arteries and subsequent pulmonary hypertension. The extent of vascular obstruction is a major determinant of chronic thromboembolic pulmonary hypertension. However, in many patients, disease progression involves pulmonary vascular remodeling and the development of a specific pulmonary arteriopathy in the non-obstructed pulmonary vessels. Histological findings in small pulmonary arteries of patients with chronic thromboembolic pulmonary hypertension are very close to that of idiopathic pulmonary arterial hypertension, including intimal fibrosis associated with organized thrombi and recanalization, medial hypertrophy, as well as plexiform lesions (9). Recent studies indicate that anticardiolipin antibodies and/or a lupus anticoagulant are risk factors for chronic thromboembolic pulmonary hypertension (10,11).

Pulmonary arterial hypertension may be either idiopathic or complicate the course of other conditions including connective tissue diseases, congenital systemic-to-pulmonary shunts, human immunodeficiency virus infection, portal hypertension, and appetite suppressant exposure. An increased prevalence of splenectomy has been reported in patients with so-called idiopathic pulmonary arterial hypertension, suggesting a link between splenectomy and the occurrence of this rare pulmonary vascular condition (12). Interestingly, examination of lung tissue of splenectomized patients who had undergone lung transplantation revealed multiple thrombotic lesions, supporting the hypothesis that thrombosis may play a significant role in this condition. Based on these findings, we systematically analyzed the case histories of patients who developed chronic thromboembolic pulmonary hypertension in order to test the hypothesis that splenectomy could be a risk factor for developing this severe pulmonary vascular condition.

## **METHODS**

### **Patients**

We retrospectively reviewed the charts of all 257 patients referred to our institution between 1989 and 1999 for chronic thromboembolic pulmonary hypertension. The diagnosis of pulmonary hypertension was based on hemodynamic findings (mean pulmonary arterial pressure greater than 25mmHg at rest or 30mmHg at exercise, with a pulmonary artery wedge pressure below 12mmHg). Diagnosis of chronic thromboembolic disease was based on the presence of one or more mismatched segmental or larger perfusion defects in the ventilation-perfusion lung scan and on pulmonary angiography showing pouch defects, pulmonary artery webs or bands, intimal irregularities, abrupt angular narrowing of the major pulmonary arteries, and/or complete obstruction of main, lobar, or segmental vessels at their point of origin (13). Medical history, clinical characteristics, thrombotic risk factors and hemodynamics of patients with chronic thromboembolic pulmonary hypertension were described and analyzed.

### **Case-control study**

We used a case-control design to compare the prevalence of splenectomy in patients with chronic thromboembolic pulmonary hypertension with that of patients with other chronic pulmonary diseases (n=180; 53 pulmonary fibrosis, 41 emphysema, 30 diffuse bronchiectasis, 19 histiocytosis X, and 37 miscellaneous end-stage pulmonary diseases) referred to our center between 1989 and 1999 for lung transplantation and patients with idiopathic pulmonary arterial hypertension (n=276) evaluated during the same period.

## Statistical Analysis

Quantitative variables were presented as means  $\pm$  SD and comparisons were made with use of Student's t-test. The prevalence of splenectomy was calculated for both groups and the 95% confidence intervals were determined. Chi-square test was used for statistical comparison. A p value below 0.05 was considered to indicate statistical significance.

## RESULTS

### Case summaries

Analysis of the 257 patients with chronic thromboembolic pulmonary hypertension demonstrated that 22 had a history of splenectomy (14 male,  $48 \pm 11$  year-old). Indication for splenectomy, age at the time of splenectomy, interval between splenectomy and diagnosis of chronic thromboembolic pulmonary hypertension and hemodynamics at time of diagnosis are listed in Table 1. Twelve patients (54.5%) had a known history of venous thromboembolism which occurred at least one year after splenectomy with no case of acute thromboembolic disease in the immediate post-operative period. The mean interval between splenectomy and chronic thromboembolic pulmonary hypertension diagnosis was  $16 \pm 9$  years. All patients had clinically severe pulmonary hypertension, including 14 patients (64%) in New York Heart Association functional class III or IV. Five patients (23%) had experienced at least one episode of syncope. Inherited thrombotic risk factors abnormalities (antithrombin, protein C, protein S deficiencies and mutations of factor V and factor II) were determined in 19 of the 22 patients. Only one patient had a protein S deficiency (Table 1). Antiphospholipid antibodies and lupus anticoagulant were not detected in the 18 patients tested (Table 1), as compared to the 20% prevalence found in the patients with chronic thromboembolic pulmonary hypertension and no history of splenectomy

(10). Total platelet count was within the normal range in all patients at the time of chronic thromboembolic pulmonary hypertension diagnosis.

All patients received medical treatment (warfarin, diuretics, and oxygen if needed). Eight eligible patients (36%) underwent pulmonary thromboendarterectomy for proximal chronic thromboembolic pulmonary hypertension. This proportion of operable patients was similar in non splenectomized patients with CTEPH reported in the literature (37%). Surgery was successful in 7 patients and 1 patient died of refractory right ventricular failure after surgery. Out of the 14 remaining patients, 3 were treated with continuous epoprostenol infusion for distal obstruction and 2 have undergone lung transplantation. Examination of the explanted lung tissue of these two patients revealed multiple thrombotic lesions of the pulmonary vasculature, characterized by intimal fibrosis associated with organized thrombi and recanalization of small pulmonary arteries.

### **Case-control study**

We performed a case-control design to compare the prevalence of splenectomy in patients with chronic thromboembolic pulmonary hypertension (n=257) with that of patients with idiopathic pulmonary arterial hypertension (n=276) and other pulmonary diseases (n=180) referred to our centre for lung transplant evaluation. Basic data are shown in table 2.

In patients with chronic thromboembolic pulmonary hypertension, 8.6% (CI 95%, [5.2-12.0%]) had a history of splenectomy, as compared to 2.5% (CI 95%, [0.7-4.4%]) and 0.56% (CI 95%, [0-1.6%]) in cases of idiopathic pulmonary arterial hypertension and other chronic pulmonary conditions, respectively (p<0.01; Chi square test, Figure 1).

### **DISCUSSION**

Five thousands splenectomies are performed every year in France (14). It can be therefore estimated that the prevalence of splenectomy in a general population with a mean age of 50 years would be around 0.4%, similar to that observed in patients referred for chronic pulmonary diseases in our lung transplantation unit (0.5%). Thus, the 8.6% frequency of splenectomy in chronic thromboembolic pulmonary hypertension is 20 times greater than expected in the general population. This finding supports the concept that splenectomy may promote recurrent thromboembolic disease and/or in situ thrombosis and could be a risk factor for chronic thromboembolic pulmonary hypertension. Indeed, in recent years it has become clear that embolism may not be a prerequisite for thromboembolic pulmonary hypertension and CTEPH may be a consequence of thrombosis rather than embolism. In subjects displaying idiopathic pulmonary arterial hypertension, a history of splenectomy was found in 2.5%. This is higher than the general population but markedly less than the 11.5% frequency reported by Hoepfer (12). However this apparent discrepancy may in fact reflect the continuum between proximal chronic thromboembolic pulmonary hypertension which will benefit from pulmonary endarterectomy, distal cases which should not be proposed for pulmonary endarterectomy and thrombotic forms of idiopathic pulmonary arterial hypertension. Interestingly, only 36% of splenectomized patients with chronic thromboembolic pulmonary hypertension in our series had a thromboendarterectomy highlighting the fact that most cases were distal (or had a contra-indication due to significant comorbidities). Moreover, pulmonary hypertension described in splenectomized subjects by Hoepfer et al had prominent thrombotic pulmonary arteriopathy, and, in one patient these lesions recurred after

lung transplantation. These findings tend to indicate a role of splenectomy in the development of a prothrombotic state in these individuals. The patients described in the present report developed chronic thromboembolic pulmonary hypertension 7 to 25 years after splenectomy. In 4 cases out of 22, the indication for splenectomy was chronic hemolysis (Table 1). However, chronic hemolysis per se is not a cause of thrombosis. Nevertheless, when splenectomized, these patients appear to have an increased propensity for thrombosis (15-26). Steward et al reported a series of 18 patients (9 with a history of splenectomy) with inherited stomatocytosis followed-up for more than 20 years (17). All splenectomized subjects with inherited stomatocytosis developed at least one documented thromboembolic episode 2 to twenty-six years after splenectomy, leading in 4 cases to chronic thromboembolic pulmonary hypertension. We have recently reported a similar case of distal chronic thromboembolic pulmonary hypertension treated by heart-lung transplantation after bridge therapy with intravenous epoprostenol (patient number 4 of the present series) (18). In non splenectomized subjects, no thromboembolic event has been reported (17). It is believed that splenectomy, in a chronic hemolysis status, may predispose to thromboembolic disease that might eventually lead to chronic thromboembolic pulmonary hypertension. Similarly, Hayag-Barin et al described the case of a 30-year old male with hereditary spherocytosis who presented 29 years after splenectomy with recurrent pulmonary emboli resulting in severe pulmonary hypertension (19). In addition, Chou et al reported a case of recurrent thromboembolic disease and chronic pulmonary hypertension in an adult patient with pyruvate kinase deficiency who underwent splenectomy as a child (20). Other vascular and thrombotic phenomena that have been described in patients following splenectomy for hereditary hemolytic anemia include priapism, arterial thrombosis, portal vein thrombosis, and superior mesenteric vein thrombosis (17,21)

In patients with hereditary and chronic hemolytic anemia there are some interesting data showing, in autopsy findings, an elevated frequency (44%) of obstructive pulmonary arterial lesions in

splenectomized  $\beta$ -thalassemia patients (22). One of the mechanisms involved would be a prothrombotic state due to higher thrombin formation in splenectomized patients. Abnormal erythrocytes would be paramount for the activation of mechanisms for thrombin synthesis. Of note, most patients reported in the present study had no hematological condition and splenectomy was indicated after a trauma in 15 out of 22 cases. Interestingly, only eight of these 15 patients (53%) had a history of documented venous thromboembolism which occurred in all cases at least one year after splenectomy and never immediately after the surgery. Moreover, the work-up for acquired or inherited thrombotic risk factors was negative for all of them at the exception of a single case of protein S deficiency. This finding is consistent with the published evidence for splenectomy being a risk factor for thromboembolic disease even in the absence of underlying hematological condition. Colheart et al reported a 10.7% frequency of pulmonary thromboembolic disease in a retrospective study of 150 consecutive splenectomies performed over a five-year period (23). Likewise, a review of 37,012 autopsies over 20 years analyzed 202 deceased adults who had a history of splenectomy. The number of thromboembolic complications related to death in these patients was compared with that of a matched deceased population who had not undergone splenectomy (n=403). This study showed that pulmonary embolism was the major or a contributory cause of death more often in the splenectomy group than in the control group (35.6% versus 9.7%,  $p < 0.001$ ), supporting the hypothesis that splenectomy might be a risk factor for pulmonary thromboembolic disease (24).

In our series, only 12 of the 22 splenectomized patients with chronic thromboembolic pulmonary hypertension had a known history of venous thromboembolic disease. This is consistent with recent studies indicating that symptom-free venous thromboembolic disease is common and that symptomatic pulmonary embolism is often overlooked or misdiagnosed (25,26,27).

There are some speculations on how splenectomy could play a role in promoting venous thromboembolic disease. While transient thrombocytosis is expected in the immediate post-

splenectomy setting, it is not usually associated with thrombotic events (28,29). In addition our patients developed chronic thromboembolic pulmonary hypertension several years after splenectomy, when thrombocytosis was no longer present (Table 1). A role for components of the erythrocyte membrane has been proposed in venous thromboembolic disease occurring after splenectomy (30,31). Indeed, the anionic phospholipids of erythrocyte membrane including the phosphatidylserine known to facilitate the coagulation process are localized in the inner membrane leaflet of the cell membrane in normal individuals (31). Abnormal exposure of phosphatidylserine at the outer leaflet of erythrocyte membrane, would promote an activation of the coagulation process by enzymatic complexes fixation. This hypothesis was considered by Kuypers et al who assessed phosphatidylserine expression in thalassemic patients. These authors showed that numbers of erythrocytes with modified phosphatidylserine expression was multiplied by 20 after splenectomy (30). These cells also acquired a procoagulant phenotype, as a marker of accelerated thrombin formation. The loss of filtering function of the spleen would allow abnormal red cells to remain in the peripheral circulation after splenectomy, resulting in the activation of the coagulation cascade even in the absence of chronic hemolysis.

Our study has some limitations . First, we used a retrospective design and studied three groups in which patients were not matched for age and sex. Second, trauma was the main indication for splenectomy and abdominal surgery following this trauma could be an associated factor for thromboembolic disease even if no patients had developed a documented thromboembolic disease immediately after the surgery.

Ideally, to address the relationship between splenectomy and CTEPH, a group of patients with splenectomy and no other thromboembolic risk factors should be matched with a group of patients with intact spleens and then be followed up to look at the prevalence of CTEPH. Unfortunately, our database did not allow us to perform such analysis.

However, on the basis of our present series and after careful analysis of the published medical literature, we conclude that splenectomy might be a risk factor for venous thromboembolic disease and subsequent chronic thromboembolic pulmonary hypertension.

Based on our findings, it may be relevant to discuss post splenectomy prophylaxis anticoagulation in situations at risk of thromboembolic disease such as surgery, immobilization, plaster. There is, however, a lack of evidence in the literature to support the systematic use of oral anticoagulation in this group of patients.

**REFERENCES**

1. Fedullo PF, Auger WR, Kerr KM, Rubin LJ. Chronic Thromboembolic Pulmonary Hypertension. *N Engl J Med* 2002; 345: 1465-1472.
2. Gillum RF. Pulmonary embolism and thrombophlebitis in the United States 1975-1985. *Am Heart J* 1987; 114: 1262-1264.
3. Lilienfield DE, Chan E, Ehland J. Mortality from pulmonary embolism in the United States: 1962-1984. *Chest* 1990; 98: 1067-1072.
4. Olman MA, Marsh JJ, Lang IM, Moser KM, Binder DR, Schleef RR. Endogenous fibrinolytic system in chronic large vessel thromboembolic pulmonary hypertension. *Circulation* 1992; 86: 1241-1248.
5. Lang IM, Marsh JJ, Olman MA, Moser KM. Parallel analysis of tissue-type plasminogen activator and type I plasminogen activator inhibitor in plasma and endothelial cells derived from patients with chronic pulmonary thromboemboli. *Circulation* 1994; 90: 706-712.
6. Lang IM, Marsh JJ, Olman MA, Moser KM. Expression of type I plasminogen activator inhibitor in chronic pulmonary thromboemboli. *Circulation* 1994; 89: 2715-2721.
7. Moser KM, Auger WR, Fedullo PF. Chronic major vessel thromboembolic pulmonary hypertension. *Circulation* 1990; 81: 1735-1743.
8. Lang IM, Klepetho W, Pabinger I. No increased prevalence of the factor V Leiden mutation in chronic major vessel thromboembolic pulmonary hypertension. *Thromb Haemost* 1996; 76: 476-477.
9. Moser KM, Bloor CM. Pulmonary vascular lesions occurring in patients with chronic major vessel thromboembolic pulmonary hypertension. *Chest* 1993; 103: 685-692.
10. Wolf M, Boyer-Neumann C, Parent F, Eschwege V, Jaillet H, Meyer D, Simonneau G. Thrombotic risk factors in pulmonary hypertension. *Eur Respir J* 2000; 15: 395-399.
11. Auger WR, Permpikul P, Moser KM. Lupus anticoagulant, heparin use and thrombocytopenia in patients with chronic thromboembolic pulmonary hypertension. A preliminary report. *Am J Med* 1995; 99: 392-396.
12. Hoepfer MM, Niedermeyer J, Hoffmeyer F, Flemming P, Fabel H. Pulmonary hypertension after splenectomy? *Ann Intern Med* 1999; 130:506-509.
13. Moser KM, Auger WR, Fedullo PF. Chronic major-vessel thromboembolic pulmonary hypertension. *Circulation* 1990; 81: 1735-1743.
14. Beytout J, Tournilhac O, Laurichesse H. Management of splenectomized patients. *Presse Med* 2003; 32: 3S3.

15. Hirsh J, Dacie JV. Persistent post-splenectomy thrombocytosis and thromboembolism. *Br J Haematol* 1966; 12: 44-53.
16. Hirsh J, McBride JA, Dacie JV. Thromboembolism and increased platelet adhesiveness in post-splenectomy thrombocytosis. *Aust Ann Med* 1966; 15: 122-128.
17. Steward GW, Amess JAL, Eber SW, Kingswood C, Lane PA, Smith BD, Mentzer WC. Thrombo-embolic disease after splenectomy for hereditary stomatocytosis. *Br J Haematol* 1996; 93: 303-310.
18. Jaïs X, Till S J, Cynober T, Ioos V, Garcia G, Tchernia G, Darteville P, Simonneau G, Delaunay J, Humbert M. An extreme consequence of splenectomy in Dehydrated Hereditary Stomatocytosis: Gradual Thromboembolic Pulmonary Hypertension and Lung-heart Transplantation. *Hemoglobin* 2003; 27(3): 139-147.
19. Hayag-Barin JE, Smith RE, Tucker, Jr. FC. Hereditary Spherocytosis, Thrombocytosis, and Chronic Pulmonary Emboli: A Case Report and Review of the Literature. *Am J Hematol* 1998; 57: 82-84.
20. Chou R, DeLoughery TG. Recurrent Thromboembolic Disease Following Splenectomy for Pyruvate Kinase Deficiency. *Am J Hematol* 2001; 67:197-199.
21. Bertolotti M, Loria P, Martella P, Carulli L, DeSantis M, Carulli N. Bleeding jejunal varices and portal thrombosis in a splenectomized patient with hereditary spherocytosis. *Dig Dis Sci* 2000; 45: 373-377.
22. Sonakul D, Pacharee P, Laohapand T, Fuchaoren S. Pulmonary artery obstruction in thalassemia. *Southeast Asian J Trop Med Public Health* 1980; 11: 416-423.
23. Coltheart G, Little JM. Splenectomy: a review of morbidity. *Aust N Z J Surg* 1976; 46: 32-36.
24. Pimpl W, Dapunt O, Kaindl H, Thalhamer J. Incidence of septic and thromboembolic-related deaths after splenectomy in adults. *Br J Surg* 1989; 76: 5, 517-21.
25. Meignan M, Rosso J, Gauthier H. Systematic lung scans reveal a high frequency of silent pulmonary embolism in patients with proximal deep venous thrombosis. *Arch Intern Med* 2000; 160: 159-64.
26. Ryu JH, Olson EJ, Pellikka PA. Clinical recognition of pulmonary embolism: problem of unrecognized and asymptomatic cases. *Mayo Clin Proc* 1998; 73: 873-9.
27. Darteville P, Fadel E, Mussot S, Chapelier A, Hervé P, de Perrot M, Cerrina J, Leroy-Ladurie F, Lehouerou D, Humbert M, Sitbon O, Simonneau G. Chronic thromboembolic pulmonary hypertension. *Eur Respir J* 2004; 23: 637-648.
28. Boxer MA, Braun J, Ellman L. Thromboembolic risk of postsplenectomy thrombocytosis. *Arch Surg* 1978; 113: 808-809.

29. Visudhiphan S, Ketsa-Ard K, Piankijagun A, Tumliang S. Blood coagulation and platelet profiles in persistent post splenectomy thrombocytosis. The relationship to thromboembolism. *Biomed Pharmacother* 1985; 39: 264-271.
30. Kuypers FA, Yuan J, Lewis RA, Snyder LM, *et al.* Membrane phospholipid asymmetry in human thalassemia. *Blood* 1998; 91: 3044-3051.
31. Atichartakarn V, Angchaisuksiri P, Aryurachai K, Onpun S, Chuncharunee S, Thakkestian A, Atamasirikul K. Relationship between hypercoagulable state and erythrocyte phosphatidylserine exposure in splenectomized haemoglobin E / [beta]- thalassaemic patients. *Br J Haematol* 2002; 118: 893-898.

**FIGURE LEGENDS**

Figure 1: Prevalence of splenectomy in chronic thromboembolic pulmonary hypertension (CTEPH), idiopathic pulmonary arterial hypertension (IPAH), and patients with other chronic pulmonary conditions (control). Results are indicated as means and 95% confidence interval (CI). In patients with CTEPH, 8.6% (CI 95%, [5.2-12.0%]) had a history of splenectomy, as compared to 2.5% (CI 95%, [0.7-4.4%]) and 0.56% (CI 95%, [0-1.6%]) in cases of idiopathic pulmonary arterial hypertension and other chronic pulmonary conditions, respectively ( $p < 0.01$ ; Chi square test, Figure 1).

**Table 1: Clinical and hemodynamic characteristics of patients who developed chronic thromboembolic pulmonary hypertension after splenectomy**

Patient	Indication for splenectomy	Age at Splenectomy (years)	Interval splenectomy &diagnosis of CTEPH (years)	History of VTE	Risk factors	Platelet count at time of diagnosis	mPAP (mmHg)	CI (l/mn/m <sup>2</sup> )
1	Trauma	32	3	Yes	No	414	60	2.76
2	Hodgkin	24	21	No	No	310	30	1.87
3	Gastric cancer	41	6	Yes	No	162	27	2.63
4	Stomatocytosis	31	17	No	PS	418	51	2.37
5	Spherocytosis	2	35	No	No	179	48	1.80
6	Spherocytosis	20	30	No	NA	200	63	2.90
7	AIHA	54	14	No	No	360	30	3.07
8	Trauma	33	20	No	No	285	47	2.07
9	Trauma	32	24	Yes	NA	230	53	2.50
10	Trauma	48	9	No	No	258	54	1.85
11	Trauma	56	12	Yes	NA	289	32	2.77
12	Trauma	26	25	No	No	211	57	2.80
13	Trauma	52	11	Yes	No	208	47	1.90
14	Trauma	21	21	Yes	No	336	53	3.41
15	Trauma	39	2	No	No	295	33	4.20
16	Trauma	21	30	Yes	No	188	42	2.50
17	Trauma	46	19	Yes	No	448	61	3.83
18	Trauma	53	10	No	No	239	67	1.64
19	Trauma	40	10	Yes	No	197	40	2.54
20	Trauma	20	12	Yes	No	300	47	2.24
21	Trauma	21	9	Yes	No	355	49	1.60
22	Pancreatitis	31	13	Yes	No	234	60	2.00
<b>Mean±SD</b>		34±14	16±9			278±83	48.5±11.2	2.51±0.69

*Abbreviations:*

AIHA = autoimmune hemolytic anemia

CI= cardiac index;

CTEPH= chronic thromboembolic pulmonary hypertension;

mPAP: mean pulmonary arterial pressure;

NA= not available;

PS= Protein S deficiency;

*VTE: acute venous thromboembolism.***Table 2: Basic demographics**

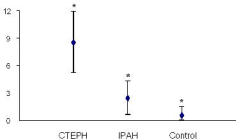
	CTEPH (n = 257)	IPAH (n = 276)	Control (n = 180)
Sex Ratio [F:M]	0.9:1	1.5:1 #	0.8:1
Age, years [mean (SD)]	51 (14) *	46 (15)	47 (9)
Number of patients with splenectomy, n (%; [95% CI])	22 * (8.6%; [5.2-12%])	7 (2.5%; [0.7-4.4%])	1 (0.6%; [0.0-1.6%])

List of abbreviations: CTEPH: chronic thromboembolic pulmonary hypertension; IPAH: idiopathic pulmonary arterial hypertension; CI: confidence interval.

#  $p < 0.05$  (comparison with CTEPH and control groups; Chi square test).

\*  $p < 0.01$  (comparison with IPAH and control groups; Chi square and unpaired Student's t-tests, as appropriate).

Prevalence of splenomegaly (%)





## Splenectomy and chronic thromboembolic pulmonary hypertension

Xavier Jaïs, Vincent Ioss, Carlos Jardim, et al.

*Thorax* published online August 5, 2005

doi: 10.1136/thx.2004.038083

---

Updated information and services can be found at:

<http://thorax.bmj.com/content/early/2005/08/05/thx.2004.038083.citation>

---

	<i>These include:</i>
<b>References</b>	Article cited in: <a href="http://thorax.bmj.com/content/early/2005/08/05/thx.2004.038083.citation#related-urls">http://thorax.bmj.com/content/early/2005/08/05/thx.2004.038083.citation#related-urls</a>
<b>P&lt;P</b>	Published online August 5, 2005 in advance of the print journal.
<b>Email alerting service</b>	Receive free email alerts when new articles cite this article. Sign up in the box at the top right corner of the online article.

---

### Topic Collections

Articles on similar topics can be found in the following collections

[Pulmonary hypertension](#) (125 articles)  
[Venous thromboembolism](#) (91 articles)  
[Cardiothoracic surgery](#) (395 articles)  
[Epidemiologic studies](#) (1094 articles)  
[Pulmonary embolism](#) (79 articles)  
[Transplantation](#) (117 articles)

---

Advance online articles have been peer reviewed, accepted for publication, edited and typeset, but have not yet appeared in the paper journal. Advance online articles are citable and establish publication priority; they are indexed by PubMed from initial publication. Citations to Advance online articles must include the digital object identifier (DOIs) and date of initial publication.

---

To request permissions go to:

<http://group.bmj.com/group/rights-licensing/permissions>

To order reprints go to:

<http://journals.bmj.com/cgi/reprintform>

To subscribe to BMJ go to:

<http://group.bmj.com/subscribe/>

## Notes

---

Advance online articles have been peer reviewed, accepted for publication, edited and typeset, but have not yet appeared in the paper journal. Advance online articles are citable and establish publication priority; they are indexed by PubMed from initial publication. Citations to Advance online articles must include the digital object identifier (DOIs) and date of initial publication.

---

To request permissions go to:

<http://group.bmj.com/group/rights-licensing/permissions>

To order reprints go to:

<http://journals.bmj.com/cgi/reprintform>

To subscribe to BMJ go to:

<http://group.bmj.com/subscribe/>