



IMAGES IN THORAX

All that wheezes is not asthma

Pyng Lee,¹ Ze-Ying Tan,¹ Thanh Pham²

¹Respiratory and Critical Care Medicine, National University Hospital, Singapore

²Department of Respiratory Medicine, Cho Ray Hospital, Ho Chi Minh City, Vietnam

Correspondence to

Professor Pyng Lee, Division of Respiratory and Critical Care Medicine, National University Hospital, Singapore 119228, Singapore; pyng_lee@nuhs.edu.sg

Received 10 December 2017

Revised 23 February 2018

Accepted 26 February 2018

Published Online First

21 March 2018

A 31-year-old man complained of intermittent wheeze, dyspnoea and hoarse voice for 2 months. He was diagnosed with asthma and prescribed inhaled corticosteroid by the general practitioner. However, his symptoms persisted despite compliance to inhaler therapy. He was a non-smoker, worked as a logger and remembered quenching his thirst at a nearby river prior to his symptoms. Physical examination revealed a well-nourished man with audible wheeze, normal vital parameters and saturating 96% on room air. Chest radiograph (CXR) was unremarkable. Flexible bronchoscopy performed for hoarse voice revealed a leech straddling the vocal cords. It was attached to the larynx (figure 1) and increasing in size during the procedure. Lidocaine (2%) was sprayed on the leech to paralyse it, blunt edge of forceps was used to separate the anterior sucker from the laryngeal mucosa followed by grasping the body for en bloc removal. A living leech 5 cm × 1 cm was successfully retrieved and haemostasis secured with topical epinephrine (1:10 000 concentration). Careful examination of the nasal passages and tracheobronchial tree did not reveal other leeches and he was discharged home with oral ciprofloxacin. Leeches (class: Hirudinea) are segmented worms found in rivers, ponds, lakes, swamps and water-logged ditches. Human infestations occur in rural populations where access to clean drinking water is restricted. The worm has suckers at both ends and preys on the host's blood. Saliva containing anaesthetic is secreted into the wound to avoid detection and hirudin

into the host's bloodstream to prevent clotting. The alimentary system has multiple sacs known as crops that store large amounts of blood. A satiated leech can grow up to 9 times its body size and detach on its own after 20 min to 2 hours. Bleeding can continue for hours to days after detachment.^{1 2} *Aeromonas* bacteria that thrive in the crops aid in blood digestion, but can cause infections in humans. Care to minimise manipulation of the leech to avoid regurgitation of infected blood into the wound should be exercised. Antimicrobial prophylaxis with ciprofloxacin during and after medical leech therapy is recommended; however, data on empirical ciprofloxacin following removal of leeches from the aerodigestive tract are needed.^{2 3}

Intermittent airway obstruction with hoarse voice and wheeze caused by a living foreign body is rarely reported. Literature shows 17 reports of leeches found in the larynx, subglottis and tracheobronchial tree.³ Airway leech may mimic bronchial asthma and should be suspected in patients who have consumed contaminated water from rivers.^{3 4} Flexible bronchoscopy was both diagnostic and therapeutic in our patient.

Contributors PL and TP: patient management and writing. Z-YT: writing and submission.

Funding The authors have not declared a specific grant for this research from any funding agency in the public, commercial or not-for-profit sectors.

Competing interests None declared.

Patient consent Obtained.

Provenance and peer review Not commissioned; externally peer reviewed.

© Article author(s) (or their employer(s) unless otherwise stated in the text of the article) 2018. All rights reserved. No commercial use is permitted unless otherwise expressly granted.

REFERENCES

- 1 Raza SN, Shabbir SM, Anwar-ul-Haq. Leech infestation and its association with water drinking habits. *J Coll Physicians Surg Pak* 2006;16:175–8.
- 2 Maetz B, Abbou R, Andreoletti JB, et al. Infections following the application of leeches: two case reports and review of the literature. *J Med Case Rep* 2012;6:364.
- 3 Ali SR, Mehta AC. Alive in the Airways. *Chest* 2017;151:481–91.
- 4 Mohammad Y, Rostum IM, Dubaybo BA. Laryngeal hirudiniasis: an unusual cause of airway obstruction and hemoptysis. *Pediatr Pulmonol* 2002;33:224–6.

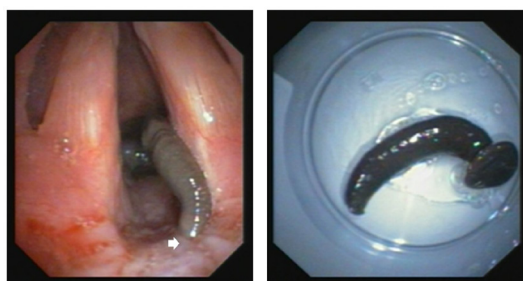
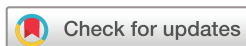

Figure 1 Bronchoscopic image of leech attached to the larynx and straddling across the vocal cords. Intact living leech after removal.



To cite: Lee P, Tan Z-Y, Pham T. *Thorax* 2018;**73**:792.

