



## PULMONARY PUZZLES

## A very strange tail

Ambika Talwar,<sup>1</sup> Anne McGown,<sup>1</sup> Tracy Langham,<sup>1</sup> Muhammad Abid,<sup>2</sup> John Pilling,<sup>3</sup>  
on behalf of the Department of Respiratory Medicine, Royal Berkshire Hospital

A young couple both presented in the autumn of 2013 with a protracted flu-like illness, right-sided pleuritic chest pain and night sweats. Neither had any significant past illnesses nor had they travelled abroad recently.

Patient X (aged 18 years) was systemically well with no extrapulmonary abnormalities on examination. Her C-reactive protein was elevated at 46 with a normal white cell count and negative blood cultures. She was not immunocompromised. Chest X-ray and thoracic ultrasound revealed a small right-sided pleural effusion. She was extremely needle phobic, and so pleural aspiration was not performed. She was treated for pneumonia with a 4-week course of oral antibiotics and clinically improved.

Patient Y (aged 20 years) presented to chest clinic 1 month later. On examination, he was septic. Chest X-ray, thoracic ultrasound and pleural aspiration confirmed that he had a right-sided empyema. He was admitted and treated with intra-

venous antibiotics and an intercostal chest drain. He was not immunocompromised.

Blood and pleural fluid cultures did not grow any organisms. He continued to spike temperatures and so underwent bronchoscopy. Bronchoalveolar lavage culture results were negative. He was discharged after 7 days with a 6-week course of oral antibiotics.

Earlier that year, in February 2013, patient Z, aged 5 weeks, who was living with this couple, displayed signs of failure to thrive, prolonged gastrointestinal upset and a discharging abscess from her thigh. She tragically died. Her chest radiograph is given in figure 1.

## QUESTIONS

1. Describe patient Z's chest radiograph.
2. Is there a unifying diagnosis for all three patients?
3. What test would you perform?

<sup>1</sup>Royal Berkshire Hospital, Reading, UK

<sup>2</sup>Thames Valley Public Health England Centre, Oxfordshire, UK

<sup>3</sup>Department of Thoracic Surgery, Guys and St Thomas's Trust, London, UK

## Correspondence to

Ambika Talwar, Respiratory Department, Royal Berkshire Hospital, London Road, Reading, UK; ambitalwar@gmail.com

Received 11 August 2014

Revised 26 September 2014

Accepted 29 September 2014

Published Online First

21 October 2014

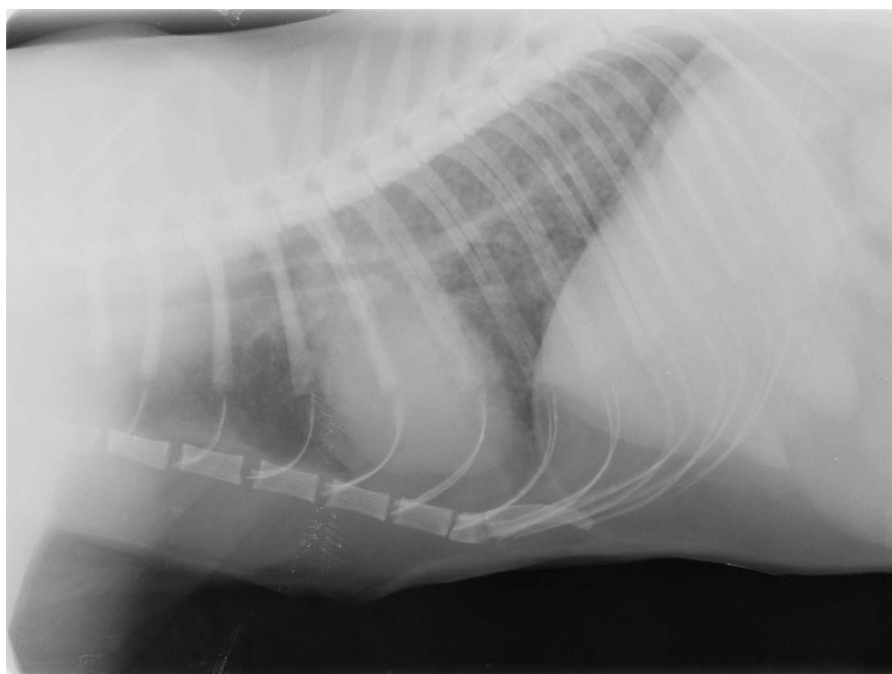


Figure 1 Chest radiograph of patient Z.



CrossMark

To cite: Talwar A, McGown A, Langham T, et al. *Thorax* 2014;**69**:1159–1160.

## ANSWERS

Patient Z's chest radiograph reveals multiple nodular opacities. Did you find this difficult to interpret? Perhaps, this is because patient Z was.... a kitten!!

She was one of a cluster of cats, some of which died from miliary *Mycobacterium bovis* following an outbreak in the area. Figure 2 shows the chest radiographs of another cat that was infected and the response to treatment.

Both our human patients were found to be IGRA-positive (patient X as part of a contact screening exercise for cat owners prior to her illness).

They were referred for right VATS pleural biopsies to confirm the diagnosis. These revealed necrotising granulomata and were culture positive for *M bovis*. DNA typing showed the same strain in the human and feline patients.

Both humans commenced a 9-month course of rifampicin, isoniazid and ethambutol; *M bovis* is pyrazinamide resistant. Both are currently doing well. At least one cat owner opted to treat his pet (figure 2).

## DISCUSSION

*M bovis* persists in cold, damp conditions. In the UK, cattle and badgers are the main maintenance hosts; humans and domestic animals are spillover hosts. Transmission to humans is commonly via consumption of unpasteurised dairy products.

Genotyping of the strains found in the cat cluster revealed similarities with the genotypes found in the local cattle/wildlife population.<sup>1</sup>

Direct transmission from animals to humans is, however, very rare; these are the first reported cases of *M bovis* transmission from domestic cats to humans.<sup>2</sup>

Current National Institute of Health and Care Excellence guidelines suggest 'inform and advise' for people in contact with TB-diseased animals rather than diagnostic tests for latent TB.<sup>3</sup> These families were screened only because of the unusually large number of cats affected.<sup>1</sup> These cases highlight the importance of finding out about pets in patients presenting with respiratory symptoms. *M bovis* infection is on the rise in UK livestock, and infection with *M bovis* should be considered in cases of unexplained respiratory symptoms.

**Acknowledgements** We are grateful to Carl Gorman of the Falkland Veterinary clinic for permission to reproduce figures 1 and 2.

**Contributors** AT wrote the case report. AM supervised the writing of the case report. MA ensured the case management and case report were submitted in accordance with public health policy. JP performed the VATS biopsy on the patients enabling tissue diagnosis of *M bovis*. TL is our TB specialist nurse who managed the patients on a day-to-day level following hospital discharge and obtained patient consent for the writing of this case for publication. Consent to publish the case and images has been obtained from the cat owner and the patients. The overall guarantor for the case is jointly AT and AM.

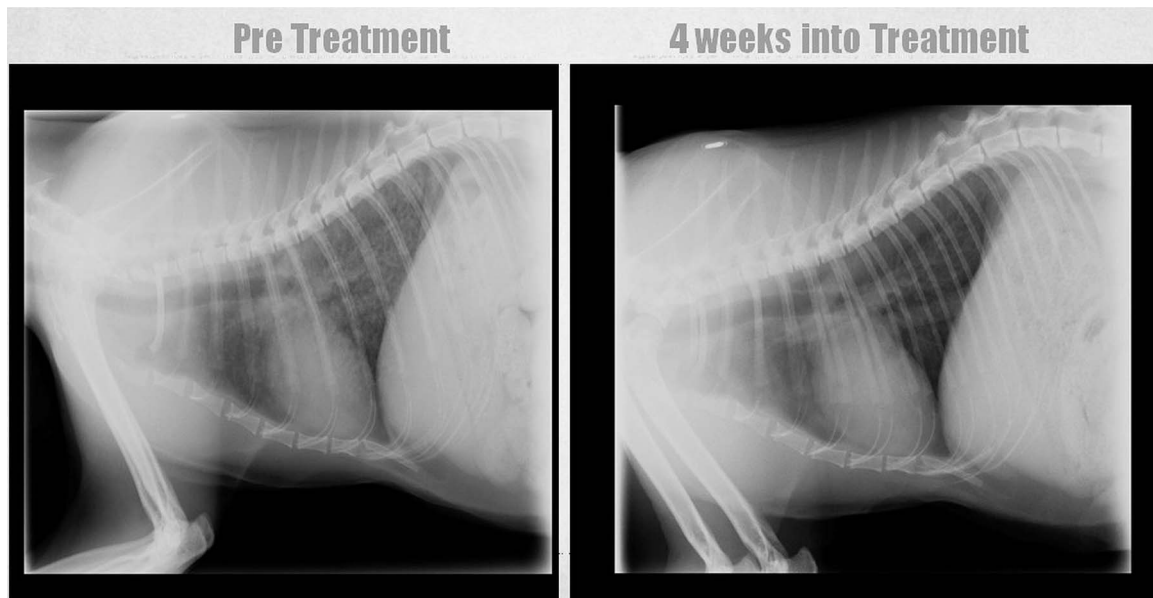
**Competing interests** None.

**Patient consent** Obtained.

**Provenance and peer review** Not commissioned; internally peer reviewed.

## REFERENCES

- 1 Roberts T, O'Connor C, Nuñez-García J, *et al*. Unusual cluster of *Mycobacterium bovis* infection in cats. *Veterinary Record* 2014;174:326.
- 2 Public Health England. *Mycobacterium bovis* and cat to human transmission in the UK. Health Protection Report 8(12). 2014. Advance Access Report. published March 27, 2014.
- 3 National Collaborating Centre for Chronic Conditions. *Tuberculosis: clinical diagnosis and management of tuberculosis, and measures for its prevention and control*. London: Royal College of Physicians, 2006.



**Figure 2** Chest radiographs of an infected cat that is currently on treatment for *Mycobacterium bovis* (*M bovis*) with azithromycin and marbofloxacin.