REFERENCES

1. **Lacasse Y,** Goldstein R, Lasserson TJ, *et al*. Pulmonary rehabilitation for chronic obstructive pulmonary disease. *Cochrane Database Syst Rev* 2006;(4):CD003793.
2. **Seymour J,** Moore L, Jolley CJ, *et al*. Outpatient pulmonary rehabilitation following acute exacerbations of COPD. *Thorax* 2010;**65**:423–8.
3. **Tu W,** Stump TE, Damush TM, *et al*. The effects of health and environment on exercise-class participation in older, urban women. *J Aging Phys Act* 2004;**12**:480–96.
4. **Corfield L,** Schizas A, Noorani A, *et al*. Non-attendance at the colorectal clinic: a prospective audit. *Ann R Coll Surg Engl* 2008;**90**:377–80.
5. **Donaldson GC,** Wedzicha JA. COPD exacerbations. 1: Epidemiology. *Thorax* 2006;**61**:164–8.

Hydatid disease versus textiloma: a diagnostic challenge

We read with great interest the well-written review by Kunst *et al*[1] discussing parasitic lung infections. In the section on hydatid disease (HD), the authors report that chest scans may reveal diagnostic features including collapse of the laminated membrane from the surrounding host tissue, the presence of daughter cysts and the presence of cyst rupture. We wish to highlight an important diagnostic challenge: differentiating between the typical tomographical presentations of HD and textilomas. Recently, Miguélez-Vara and Mariñan Gorospe[2] reported this problem, describing their difficulty in establishing a differential diagnosis between an HD recurrence and a complication of surgery (textiloma).

We report the case of a 47-year-old woman presenting with cough and chest pain and a thoracic mass detected during a radiological examination. A CT scan showed an encapsulated mass containing high-density opacities (figure 1). The patient lives in an area of endemic HD and had a history of surgery to remove a mediastinal tumour 16 years earlier for a mass of unknown histological type. The initial hypothesis for the present mass was a hydatid cyst, but surgical resection demonstrated a textiloma.

A textiloma is a mass composed of a retained surgical sponge or gauze surrounded by a foreign body reaction.[3 4] Such foreign bodies can often mimic tumours or abscesses either clinically or radiologically.[4] Textilomas generally show a high-density capsule and their contents may present an enfolded pattern, with wavy, striped high-density areas that represent the sponge.[3 4] This is very similar to observations of hydatid cysts. In HD, the detached membrane inside the cyst may be seen as a twisted, undulated structure, with a snake-like appearance, called the snake (or serpent) sign.[5]

Therefore, both conditions can present as encapsulated cysts containing a high-density undulated structure that corresponds to the sponge of a textiloma or to the detached inner membrane of a hydatid cyst. These conditions may be indistinguishable on CT, and differential diagnosis may be made by correlation with clinical features. In some cases, diagnosis may be made only after surgery.[2]

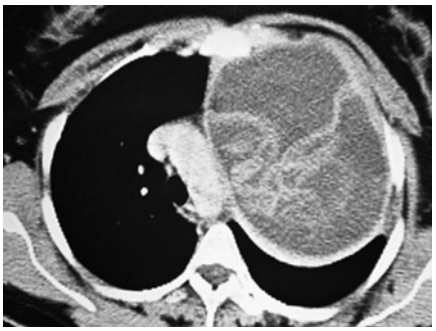

Figure 1 CT with mediastinal window settings showing a well-defined encapsulated oval mass in the right hemithorax with a thick wall and heterogeneous densities, containing wavy, striped high-density areas in the central portion.

Edson Marchiori, Gláucia Zanetti, Bruno Hochhegger, Dianne Melo Machado

Federal University of Rio de Janeiro, Rio de Janeiro, Brazil

Correspondence to Edson Marchiori, Federal University of Rio de Janeiro, Rua Thomaz Cameron, 438, Valparaiso, CEP 25685.120, Petrópolis, Rio de Janeiro, Brazil; edmarchiori@gmail.com

Competing interests None.

Provenance and peer review Not commissioned; not externally peer reviewed.

Accepted 2 December 2010
Published Online First 10 February 2011

Thorax 2011;**66**:635.
doi:10.1136/thx.2010.156935

REFERENCES

1. **Kunst H,** Mack D, Kon OM, *et al*. Parasitic infections of the lung: a guide for the respiratory physician. *Thorax* 2011;**66**:528–36.
2. **Miguélez-Vara C,** Mariñan Gorospe M. Resected asymptomatic intrathoracic textiloma 37 years after thoracotomy. *Arch Bronconeumol* 2010;**46**:492–3.
3. **Nobre LF,** Marchiori E, May F, *et al*. Thoracic textilomas after myocardial revascularisation: typical CT findings. *Br J Radiol* 2010;**83**:4–7.
4. **Manzella A,** Filho PB, Albuquerque E, *et al*. Imaging of gossypibomas: pictorial review. *AJR Am J Roentgenol* 2009;**193**(6 Suppl):S94–101.
5. **Czermak BV,** Unsinn KM, Gotwald T, *et al*. Echinococcus granulosus revisited: radiologic patterns seen in pediatric and adult patients. *AJR Am J Roentgenol* 2001;**177**:1051–6.

Gossypiboma

We thank you very much for allowing us to respond to the letter by Marchiori *et al*[1] submitted in response to our recently published paper titled 'Parasitic infections of the lung: a guide for the respiratory physician'.[2]

We agree with the authors that the condition may be a difficult diagnostic challenge, but in textilomas (gossypibomas) there is nearly always a history of previous surgery. In a fairly large series of CT scans performed on textilomas, Kopka *et al*[3] observed that in seven patients gas bubbles were found inside the textiloma with a typical pattern. These patients did not have any abscess formation; however, it is interesting to note that the radio-opaque marker inside a textiloma was seen in nine patients but did not lead to a diagnosis in all of them. The authors also found that, from in vitro studies, gas bubbles were demonstrated in all surgical sponges scanned 1 hour afterwards. It is interesting that the number of gas bubbles were not significantly reduced after 6 months. CT signs of thoracic textilomas include well-defined mediastinal or pleural-based masses with hyperdense rims, central air bubbles, with curvilinear high-density stripes occasionally seen in the early postoperative period.[4] We agree that the appearance of retained surgical sponges (textilomas/gossypibomas) can lead to misdiagnosis with lesions mimicking malignancy and hydatid disease. Textilomas have been reported in a variety of places including the maxillary sinuses, the brain and the abdomen as well as the chest, and radiologists need to be aware and vigilant of this particular clinical problem.

Heinke Kunst,[1] Arpan K Banerjee[2]

[1]Department of Respiratory Medicine, Birmingham Heartlands Hospital, Birmingham, UK; [2]Department of Radiology, Birmingham Heartlands Hospital, Birmingham, UK

Correspondence to Heinke Kunst, Birmingham Heartlands Hospital, Bordesley Green East, Birmingham B9 5SS, UK; hkunst@doctors.org.uk

Competing interests None.

Provenance and peer review Not commissioned; not externally peer reviewed.

Accepted 17 January 2011
Published Online First 10 February 2011

Thorax 2011;**66**:635.
doi:10.1136/thx.2010.157602

REFERENCES

1. **Marchiori E,** Zanetti G, Hochhegger B, *et al*. Hydatid disease versus textilomas: a diagnostic challenge. *Thorax* 2011;**66**:635.
2. **Kunst H,** Mack D, Kon OM, *et al*. Parasitic infections of the lung: a guide for the respiratory physician. *Thorax* 2011;**66**:528–36.
3. **Kopka L,** Fischer U, Gross AJ, *et al*. CT of retained surgical sponges (textilomas): pitfalls in detection and evaluation. *J Comput Assist Tomogr* 1996;**20**:919–23.
4. **Karabulut N,** Herek D, Kiroglu Y. CT of intrathoracic gossypibomas (textilomas). *Diagn Interv Radiol* 2011;**17**:122–4.

Thorax: first published as 10.1136/thx.2010.157602 on 10 February 2011. Downloaded from http://thorax.bmj.com/ on April 23, 2024 by guest. Protected by copyright.