Case reports

Commentary: "Histiocytosis X"

Dinah V Parums

Pulmonary Langerhans' cell granulomatosis (LCG) is a diffuse, smoking-related lung disease characterised pathologically by bronchiolocentric inflammation, cyst formation, and widespread vascular abnormalities, and physiologically by exercise limitation. Pulmonary fibrosis is a long term sequel. Diagnosis may be made by lung biopsy and by bronchoalveolar lavage (BAL).

The papers by Gabbay *et al*[1] and Habib *et al*[2] present two cases of LCG which recurred after double lung transplantation at two years and four years, respectively. These are the first reports of recurrent LCG in the transplanted lung. As lung transplantation is now recognised as a treatment for this disease, these two reports serve to draw our attention to what may prove to be the beginning of a series of such cases.

The titles of these two papers[1 2] also draw our attention to the remaining confusion about the terminology of this disease. This confusion has been based upon historical morphological reports. The "histiocytoses" are reactive or proliferative diseases of cells of the mononuclear phagocyte system classically seen in childhood, and they include Langerhans' cell histiocytosis (LCH) or granulomatosis (LCG), haemophagocytic syndrome (familial and reactive), sinus histiocytosis with massive lymphadenopathy (Rosai-Dorfman disease), juvenile xanthogranuloma, and malignant histiocytosis. These disorders show wide variation in their clinical presentation, prognosis, and genetic implications.[3] All are characterised by localised or generalised proliferation of histiocytes, but they differ in their morphology, histochemical and immunochemical staining patterns, and electron microscopical features. Histiocytic diseases may be generalised or involve single organs with involvement of the bone, skin, spleen, brain and lung, in order of frequency.[4 5]

The term "histiocytosis X" was meant to cover a spectrum of three diseases: eosinophilic granuloma, Hand-Schüller-Christian disease, and Letterer-Siwe disease. However, these terms are rather meaningless pathologically. Hand-Schüller-Christian disease has become a synonym for multifocal LCG. The term Langerhans' cell histiocytosis (LCH)[2] reflects the belief that this disease is a true "histiocytosis". Some prefer the term Langerhans' cell granulomatosis (LCG)[1] to avoid confusion with the term histiocytosis X because there is some evidence to support the view that the Langerhans' cell is not a member of the mononuclear phagocyte system and hence not a tissue macrophage (or histiocyte).[3 5]

Langerhans' cells are part of the widespread system of "dendritic cells" which arise from CD34+ progenitors in the bone marrow. Langerhans' cells are specialised and efficient antigen presenting cells for T cell mediated immunity. In LCG, however, the major associated cells are not T cells but mature eosinophils, hence the original name "eosinophilic granuloma".

These two case reports have elegantly demonstrated the role of immunohistochemistry in confirming the diagnosis and have relied upon the use of S100 as a marker for the Langerhans' cell. The immunophenotype and proliferation fraction have been investigated recently in 26 cases of LCG.[3] In all cases LCG cells were positive for S100 protein, CD1a, or both. In most cases LCG cells expressed the macrophage associated marker CD68 and, in two cases, they contained lysozyme. Expression of both cytoplasmic CD2 and CD3 was observed in cryostat sections. An unexpected finding was the presence of placental alkaline phosphatase in LCG cells. Langerhans' cells in normal skin were negative for both CD2 and CD3, but a proportion contained placental alkaline phosphatase.

Langerhans' cell granulomatosis has been regarded as a non-malignant, reactive condition, implying that the DNA content of the Langerhans' cells is normal. However, Isaacson *et al*[5] have recently shown that LCG cells have an aberrant phenotype and are proliferating locally. Mitoses are seen in the Langerhans' cells in LCG which might suggest that LCG is a neoplastic rather than a reactive process. The implications of these studies may be of relevance in determining future treatment regimes.

Subjects with pulmonary LCG present with either normal or predominantly restrictive pulmonary physiology; exercise impairment is common and appears to reflect pulmonary vascular dysfunction.[6] The course of pulmonary LCG is variable, difficult to predict, and ranges from spontaneous remission to progressive respiratory insufficiency and death. To identify the determinants of survival Delobbe *et al*[4] recently performed a survival analysis on 45 patients with pulmonary LCG. The patients were aged from 12 to 62 years, 32 were men, and they were almost exclusively current smokers (96%). These 45 patients were followed for a median period of six years (range 1–29) after the diagnosis. During the period of observation 33 patients (73%) survived (median follow up period 5.8 years; range 1–29) and 12 (27%) died or underwent lung

Department of Histopathology, Freeman Hospital, Newcastle upon Tyne NE7 7DN, UK
D V Parums

Correspondence to:
Dr D V Parums.

Thorax: first published as 10.1136/thx.53.4.323 on 1 April 1998. Downloaded from http://thorax.bmj.com/ on April 19, 2024 by guest. Protected by copyright.

transplantation (median follow up 8.4 years; range 1.4–16.1). The median survival was approximately 13 years. A univariate analysis showed that diminished survival was significantly associated with an older age at diagnosis, a lower forced expiratory volume in one second/forced vital capacity (FEV_1/FVC) ratio at diagnosis, a higher residual volume/total lung volume (RV/TLV) ratio at diagnosis, and steroid therapy during follow up.

Recurrent LCG may mimic obliterative bronchiolitis (OB) in the transplanted lung. The bronchiolocentricity of the disease and the association with smoking suggest that there is an immunological basis to the genesis or the progression of the disease, so the first line of treatment is for the patient to stop smoking. The involvement of Langerhans' cells in T lymphocyte mediated immune reactions raises the possibility of a role for transplant immunosuppressive therapy including cyclosporin and prednisolone in the treatment of recurrent LCG.[7] As the case report by Gabbay *et al*[1] has shown, cyclophosphamide may prove to be effective in the treatment of recurrent pulmonary LCG.

In conclusion, these two reports have shown that it is important to think of the possibility of the diagnosis of recurrent pulmonary LCG in lung transplant patients and that this disease can mimic bronchiolitis obliterans syndrome clinically. Adequate tissue for histopathological examination and the use of immunophenotypic markers will confirm the diagnosis. Clinical trials are now awaited to determine appropriate treatment regimes for recurrent LCG in the context of the transplanted lung.

1 Gabbay E, Dark JH, Ashcroft T, *et al*. Recurrence of Langerhans' cell granulomatosis following lung transplantation. *Thorax* 1998;**53**:326–7.
2 Habib SB, Congleton J, Carr D, *et al*. Recurrence of recipient Langerhans' cell histiocytosis following bilateral lung transplantation. *Thorax* 1998;**53**:323–5.
3 Hage C, Willman CL, Favara BE, *et al*. Langerhans' cell histiocytosis (histiocytosis X): immunophenotype and growth fraction. *Hum Pathol* 1993;**24**:840–5.
4 Delobbe A, Durieu J, Duhamel A, *et al*. Determinants of survival in pulmonary Langerhans' cell granulomatosis (histiocytosis X). *Eur Respir J* 1996;**9**:2002–6.
5 Lieberman PH, Jones CR, Steinman RM, *et al*. Langerhans' cell (eosinophilic) granulomatosis. A clinicopathologic study encompassing 50 years. *Am J Surg Pathol* 1996;**20**: 519–52.
6 Crausman RS, Jennings CA, Tuder RM, *et al*. Pulmonary histiocytosis X: pulmonary function and exercise pathophysiology. *Am J Respir Crit Care Med* 1996;**153**:426–35.
7 Ladisch S, Gander H. Treatment of Langerhans' cell histiocytosis—evolution and current approaches. *Br J Cancer* 1994;**70**:41–6.

Thorax 1998;**53**:323–325

Recurrence of recipient Langerhans' cell histiocytosis following bilateral lung transplantation

S B Habib, J Congleton, D Carr, J Partridge, B Corrin, D M Geddes, N Banner, M Yacoub, M Burke

Transplant Unit, Harefield Hospital, Harefield, Middlesex UB9 6JH, UK
S B Habib
J Partridge
N Banner
M Yacoub
M Burke

Royal Brompton Hospital, Sydney Street, London SW3 6NP, UK
J Congleton
D Carr
B Corrin
D M Geddes

National Heart and Lung Institute of Imperial College of Science Technology and Medicine, University of London, Dovehouse Street, London SW3 6LY, UK
B Corrin
N Banner
M Yacoub

Correspondence to:
Dr M Burke, Department of Pathology, Harefield Hospital, Harefield, Middlesex UB9 6JH, UK.

Received 23 July 1997
Returned to authors 16 October 1997
Revised version received 4 November 1997
Accepted for publication 20 November 1997

Abstract

Langerhans' cell histiocytosis may cause irreversible respiratory failure due to progressive destruction of lung parenchyma and widespread cystic change. Transplantation offers a therapeutic option. A case is described of recurrence of Langerhans' cell histiocytosis which was associated with deterioration in lung function four years following bilateral lung transplantation. Patients transplanted for Langerhans' cell histiocytosis should be followed up with this complication in mind.
(*Thorax* 1998;**53**:323–325)

Keywords: Langerhans' cell histiocytosis; lung transplantation; recurrence

Case report

An otherwise fit 27 year old Asian male martial arts instructor presented in mid 1991 with recurrent spontaneous pneumothorax. He smoked 10 cigarettes per day and was taking no medication. A diagnosis of pulmonary Langerhans' cell histiocytosis was made based on the clinical picture and on the radiological findings. Chest radiography and high resolution computed tomographic scanning showed reticular shadowing and widespread cystic changes in the lower lobes. A lung biopsy specimen showed reactive pleuritis and interstitial emphysema but no evidence of active or burnt out Langerhans' cell histiocytosis. The skull radiograph was normal and a bone scan showed non-specific changes.

Lung function deteriorated over the next two years, with reduction in forced expiratory volume in one second (FEV_1) to 0.88 litres (22% predicted) and of forced vital capacity (FVC) to 2.04 litres (44% predicted). In April 1993 he underwent double lung transplantation with internal mammary artery revascularisation. The diagnosis of Langerhans' cell histiocytosis was confirmed on histological examination of the explanted lungs, showing florid active disease as well as cystic change consistent with burnt out Langerhans' cell histiocytosis. The active lesions consisted of collections of non-pigmented mitotically active Langerhans' cells interspersed with eosinophils and lymphocytes.

Postoperative recovery was complicated by pneumonia due to *Pseudomonas aeruginosa* and cytomegalovirus pneumonitis, both conditions responding to appropriate therapy. Immunosuppression consisted of cyclosporin and azathioprine with initial oral prednisolone which was slowly withdrawn over the first year. At his first annual assessment he was clinically stable. Selected mammary artery angiography showed

Thorax: first published as 10.1136/thx.53.4.323 on 1 April 1998. Downloaded from http://thorax.bmj.com/ on April 19, 2024 by guest. Protected by copyright.

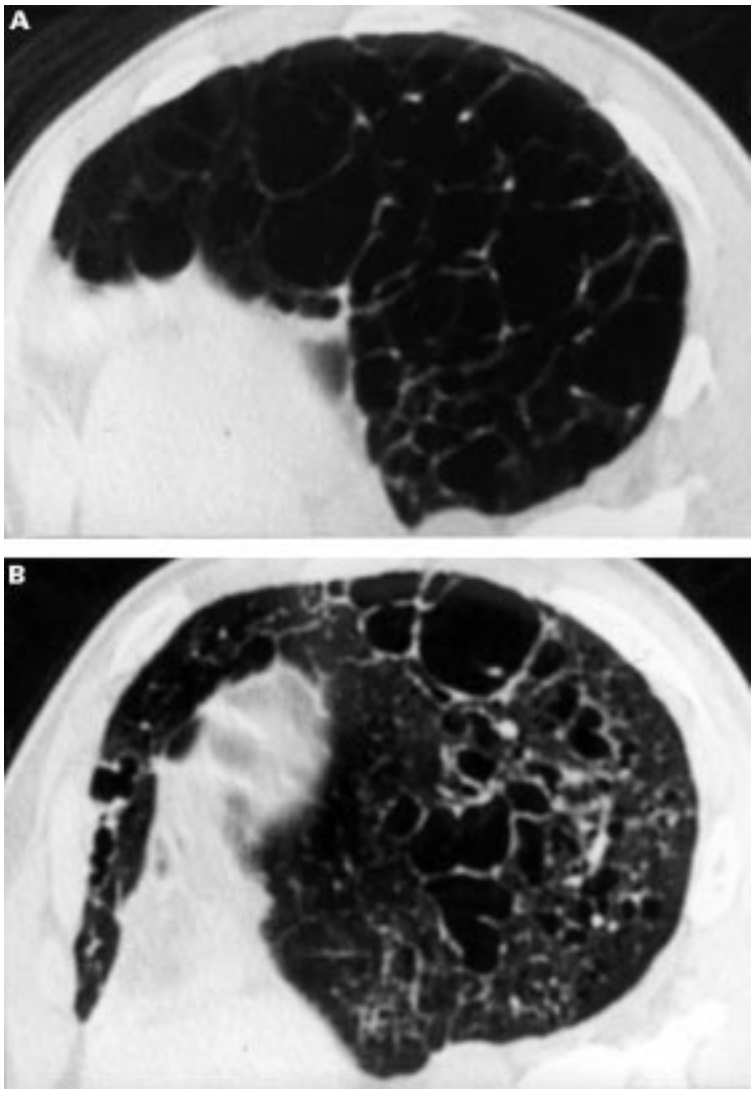

Figure 1 Representative high resolution computed tomographic views of the left base of (A) the recipient lung and (B) the donor lung 23 months after double lung transplantation. Both views show multiple parenchymal cystic spaces.

a patent anastomosis into the bronchial circulation, chest radiography was unremarkable and respiratory function tests were normal, with an FEV_1 of 3.31 litres (87% predicted) and an FVC of 3.91 litres (88% predicted). He had stopped smoking after his transplant.

However, 11 months later his respiratory function had deteriorated, with an FEV_1 of 2.72 litres (72% predicted) and an FVC of 3.63 litres (79% predicted). Bronchoscopic examination showed normal airways, the bronchoalveolar lavage fluid was normal, and the transbronchial biopsy specimen—which included bronchiolar wall as well as lung parenchyma—showed no evidence of rejection, infection, or obliterative bronchiolitis. Lung function failed to improve after a three day course of intravenous methylprednisolone and subsequent oral prednisolone. A technetium-99 diethylene triamine pentaacetic acid (^{99}Tc-DPTA) lung ventilation scan showed an area of abnormal accumulation of contrast in the right lung base. This corresponded with ill defined shadowing seen on the chest radiograph. There was no central deposition of the ^{99}Tc-DPTA in the major airways. High resolution computed tomographic scanning of the lungs revealed widespread cystic changes in both lung fields involving the mid and lower zones suggestive of recurrent Langerhans' cell histiocytosis (fig 1). This was confirmed on a transbronchial biopsy specimen from the right lower lobe. There were interstitial, peribronchiolar and perivascular clusters of S100 positive Langerhans' cells with eosinophils and lymphocytes, similar to the findings in the explanted lungs (fig 2). He did not tolerate a course of chemotherapy (doxorubicin, vincristine and etoposide), given in an attempt to arrest disease activity. His lung function deteriorated despite treatment with 15 mg prednisolone in addition to cyclosporin and cyclophosphamide but is now stable. Four years after transplantation his FEV_1 is 2.19 litres (51% of predicted) and his FVC is 3.53 litres (77% predicted).

Discussion

Langerhans' cell histiocytosis is a heterogeneous group of conditions of unknown aetiology characterised by an abnormal proliferation of antigen presenting cells of bone marrow derivation known as Langerhans' cells.[1] Isolated lung involvement is most commonly seen in young adults, many of whom are cigarette smokers. Light microscopy shows scattered discrete nodules that are frequently bronchiolocentric. The nodules are formed of focal collections of Langerhans' cells characterised as such by their morphology (nuclei with fine chromatin and grooves or folds), immunophenotype (S100 and CD1 positive) and ultrastructure (cytoplasmic Birbeck granules), interspersed with eosinophils and small lymphocytes.[1–3] The outcome is highly variable, ranging from rapid spontaneous resolution to irreversible respiratory failure. The infiltrate leads to progressive destruction of lung parenchyma and the development of widespread cystic change.[1 2] Initially many patients are asymptomatic but progressive dyspnoea may occur as the cysts enlarge and coalesce. There is a high incidence of pneumothorax. As there is no definitive treatment, pulmonary Langerhans' cell histiocytosis has recently been added to the list of indications for lung transplantation.[4] The potential for recurrence of disease in the donor organ has long term implications for graft function and survival.

There are a number of noteworthy features in our case. Firstly, the disease typically affects the upper and middle lobes and spares the costophrenic angle[5 6] but in our patient the radiographic changes were most prominent in the lower lobes, both initially and on recurrence. Secondly, it is reported that this condition is rare in Asian patients[7] but our patient was born in Pakistan of Asian parents and moved to the UK at six years of age. Lastly, respiratory function studies in Langerhans' cell histiocytosis often shows an obstructive pattern, reflecting its bronchiolocentricity but overlapping with the obliterative bronchiolitis

Thorax: first published as 10.1136/thx.53.4.323 on 1 April 1998. Downloaded from http://thorax.bmj.com/ on April 19, 2024 by guest. Protected by copyright.

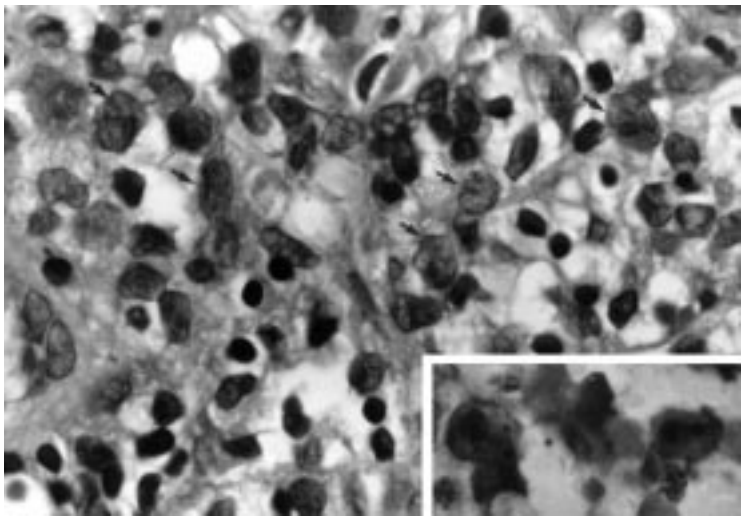

Figure 2 Transbronchial lung biopsy specimen taken 23 months after double lung transplantation showing interstitial aggregates of Langerhans' cells with large nuclei having fine chromatin and delicate folds and grooves (arrows), and pale-staining cytoplasm with indistinct cell borders. Stain: haematoxylin and eosin. Original magnification ×400. Inset: Immunostaining for S100 protein shows strong membrane and cytoplasmic positivity of the Langerhans cells. Stain: streptavidin-biotin. Original magnification ×1000.

syndrome[8] which remains the most serious long term complication of lung transplantation.[9] A contribution by the bronchiolitis obliterans syndrome to deteriorating lung function in our patient cannot be excluded despite histological confirmation of disease recurrence.

Although the aetiology of pulmonary Langerhans' cell histiocytosis is unknown, its bronchiolocentricity and tendency to regress following cessation of cigarette smoking suggests a reactive immune response in the bronchioles mediated by the Langerhans' cell, possibly through cytokine production.[10] The suggested antigen is unknown but is presumed to be inhaled. The recurrence of the disease after transplantation suggests either that extrapulmonary factors play a role in pathogenesis or that, in this instance, the disease may be truly neoplastic. The recent demonstration that Langerhans' cells in pulmonary Langerhans' cell histiocytosis may proliferate locally, showing an abnormal phenotype, lends some support to the latter theory.[11] Why the disease should recur in exactly the same pulmonary distribution before and after transplantation in our patient is unclear.

Recent reports have suggested a possible role for cyclosporin in the treatment of Langerhans' cell histiocytosis[12] as it is known to induce cytokine mediated cellular activation selectively. Although the disease recurred in our patient despite standard immunosuppressive therapy following transplantation, which included cyclosporin, it is possible that cyclosporin slowed down the rate of progression of the disease.

In summary, this report documents recurrent Langerhans' cell histiocytosis after double lung transplantation. Such recurrence may be associated with clinical deterioration. We suggest that other patients transplanted for this condition be followed up with this complication in mind.

1 Travis WD, Borok Z, Roum JH, *et al*. Pulmonary Langerhans' cell granulomatosis (histiocytosis X). *Am J Surg Pathol* 1993;**17**:971–86.
2 Hance J. Pulmonary immune cells in health and disease: dendritic cells and Langerhans' cells. *Eur Respir J* 1993;**6**:1213–20.
3 Basset F, Corrin B, Spencer H, *et al*. Pulmonary histiocytosis X. *Am Rev Respir Dis* 1978;**118**:811–20.
4 Egan TM, Detterbeck FC, Keagy BA, *et al*. Single lung transplantation for eosinophilic granulomatosis. *South Med J* 1992;**85**:551–3.
5 Lacronique J, Roth C, Battesti JP, *et al*. Chest radiological features of pulmonary histiocytosis X: a report based on 50 adult cases. *Thorax* 1982;**37**:104–9.
6 Brauner MW, Grenier P, Mouelhi MM, *et al*. Pulmonary histiocytosis X: evaluation with high resolution CT. *Radiology* 1989;**172**:255–8.
7 Prophet D. Primary pulmonary histiocytosis X. *Clin Chest Med* 1982;**3**:643–53.
8 Cooper JD, Billingham ME, Egan T, *et al*. A working formulation for the standardization of nomenclature and for clinical staging of chronic dysfunction in lung allografts. *J Heart Lung Transplant* 1993;**12**:713–6.
9 Hosenpud JD, Novick RJ, Bennett LE, *et al*. The Registry of the International Society for Heart and Lung Transplantation: 13th official report, 1996. *J Heart Lung Transplant* 1996;**15**:655–74.
10 De Graaf JH, Tamminga RYJ, Dam-Meiring A, *et al*. The presence of cytokines in Langerhans' cell histiocytosis. *J Pathol* 1996;**180**:400–6.
11 Hage C, Willman CL, Favara BE, *et al*. Langerhans' cell histiocytosis: immunophenotype and growth fraction. *Hum Pathol* 1993;**24**:840–5.
12 Ladisch S, Gander H. Treatment of Langerhans' cell histiocytosis: evolution and current approaches. *Br J Cancer* 1994;**70**:41–6.

Thorax: first published as 10.1136/thx.53.4.323 on 1 April 1998. Downloaded from http://thorax.bmj.com/ on April 19, 2024 by guest. Protected by copyright.

Recurrence of Langerhans' cell granulomatosis following lung transplantation

E Gabbay, J H Dark, T Ashcroft, D Milne, G J Gibson, M Healy, P A Corris

Abstract

A case is presented of pulmonary Langerhans' cell granulomatosis which recurred following lung transplantation and responded to cyclophosphamide. This suggests that the primary abnormality in this condition lies in the Langerhans' cell or precursor dendritic cell.

(*Thorax* 1998;**53**:326–327)

Keywords: Langerhans' cell granulomatosis; lung transplantation; cyclophosphamide

Pulmonary Langerhans' cell granulomatosis, also known as eosinophilic granuloma of lung, is a disorder of unknown aetiology characterised by the focal interstitial proliferation of Langerhans' cells[1] which surround the terminal bronchioles and alveolar ducts. They may have marked destructive tendencies leading to cavities which can coalesce to form large bullous defects surrounded by scarring. As the disease progresses there may result a combination of fibrosis and focal emphysema culminating in the development of honeycomb lung.

The natural history is variable. Spontaneous resolution occurs in 25%, stabilisation with mild loss in pulmonary function occurs in 50%, and progressive disease in 25%.[2] Death from respiratory failure or cor pulmonale occurs in approximately 5%.[2] Extrapulmonary manifestations such as diabetes insipidus and cystic bone lesions may occur.

Lung transplantation has been performed for patients with Langerhans' cell granulomatosis.[3] To our knowledge there have been no reported cases of symptomatic recurrence in the transplanted lung. We report a case of a young man transplanted for Langerhans' cell granulomatosis in whom there was documented evidence of recurrence of disease in the transplanted lung which responded to treatment with cyclophosphamide.

Case report

A 32 year old man presented with a four year history of progressive dyspnoea and cough . He was cyanosed on room air and had clinical features of pulmonary hypertension. Chest examination revealed inspiratory crackles and the chest radiograph showed interstitial shadowing with small thick walled cysts and prominent pulmonary arteries. He had been a lifelong non-smoker. Diabetes insipidus had been diagnosed at the age of 12 and treated with nasal desmopressin. Lung physiology revealed a restrictive defect with a vital capacity of 3.08 litres (60% predicted) and a carbon monoxide transfer factor of 2.26 mmol/min/kPa (20% predicted). On air he had a Po_2 of 7.8 kPa, Pco_2 of 5.6 kPa, and Sao_2 of 90%. Pulmonary systolic artery pressure was estimated at 96 mm Hg by Doppler echocardiography.

A diagnosis was made of Langerhans' cell granulomatosis with associated pulmonary hypertension. He deteriorated despite prednisolone, oxygen, diltiazem and warfarin and underwent bilateral sequential lung transplantation. Histological examination of his explanted lungs revealed extensive scarring and interstitial fibrosis with focal inflammatory infiltrates of histiocytic appearing cells which demonstrated immunohistochemical reactivity for S100 antigen. There was, in addition, focal air space dilatation and emphysema and intimal fibrosis in the pulmonary arteries confirming the diagnosis of Langerhans' cell granulomatosis with associated pulmonary hypertension.

The immediate post-transplantation course was uncomplicated and shortly afterwards his requirement for nasal desmopressin was reduced, presumably as a result of immunosuppressive therapy. His course until two years after transplantation was uneventful with progressive improvement in lung function and arterial blood gas tensions until stable levels were achieved. Routine triple therapy immunosuppression (cyclosporin A, azathioprine, prednisolone) was maintained until 12 months after transplantation but azathioprine was then discontinued due to a persistently low white cell count.

Routine two year transbronchial biopsy specimens revealed interstitial infiltration by large histiocytic like cells mingled with lymphocytes and eosinophils. The histiocytic appearing cells showed characteristic features of Langerhans' cells with eccentric and grooved nuclei and pink granular cytoplasm which again demonstrated immunohistochemical reactivity for S100 antigen. Over the next six months he developed progressively restrictive lung function associated with dyspnoea and increased requirement for nasal desmopressin. A high resolution computed tomographic scan demonstrated changes compatible with interstitial fibrosis. Repeat transbronchial biopsy specimens, now 30 months after transplantation, demonstrated interstitial fibrosis with large aggregates of Langerhans' cells centred around terminal bronchioles (fig 1). There was no evidence of acute rejection, infection, or obliterative bronchiolitis. A diagnosis of recurrent Langerhans' cell granulomatosis was therefore made.

He was commenced on cyclophosphamide 50 mg per day and maintained on cyclosporin and prednisolone. His symptoms and lung function improved and his requirement for nasal desmopressin was reduced. After 12 months he remains well on cyclophosphamide 50 mg per day.

Department of Respiratory Medicine
E Gabbay
G J Gibson
M Healy
P A Corris

Department of Cardiopulmonary Transplantation
J H Dark

Department of Histopathology
D Milne

Freeman Hospital, Newcastle upon Tyne NE7 7DN, UK

Correspondence to:
Dr P A Corris.

Received 11 June 1996
Returned to authors
8 October 1996
Revised version received
6 December 1996
Accepted for publication
6 January 1997

Thorax: first published as 10.1136/thx.53.4.323 on 1 April 1998. Downloaded from http://thorax.bmj.com/ on April 19, 2024 by guest. Protected by copyright.

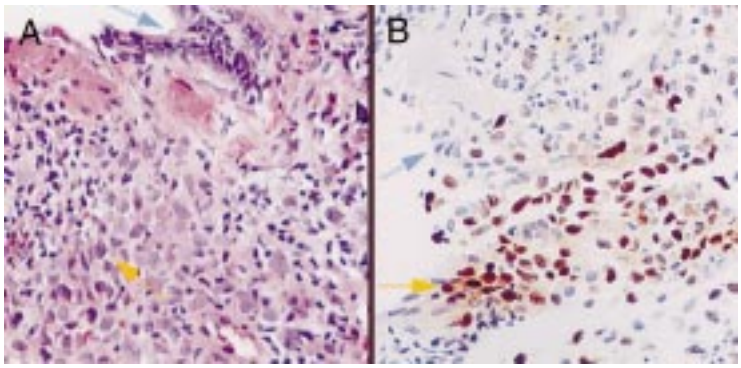

Figure 1 (A) Transbronchial biopsy specimen showing accumulation of large mononuclear cells in the bronchiolar wall; blue arrow = bronchiolar epithelium, yellow arrow = mononuclear cells (stain: haematoxylin and eosin, magnification ×240). (B) Transbronchial biopsy specimen showing S100 positive cells in the bronchiolar wall; blue arrow = bronchiolar epithelium, yellow arrow = S100 staining cells (magnification ×900).

Discussion

Langerhans' cell granulomatosis is a rare interstitial disorder of unknown origin with variable clinical presentation, natural history, and response to therapy. Lung transplantation has been successfully performed for refractory cases associated with progressive respiratory failure.[3] We describe the first case of symptomatic recurrent Langerhans' cell granulomatosis following bilateral sequential lung transplantation.

Langerhans' cells are normally present in the human lung. They are morphologically similar to and most probably derived from dendritic cells and are distinguished from histiocytes by characteristic cytoplasmic immunostaining with S100 antigen.[4] Dendritic cells are derived from bone marrow stem cells and arrive in the lung by the capillary bed where they differentiate into Langerhans' cells. Langerhans' cells are also seen with interstitial pneumonitis and other lung diseases but it is the formation of large aggregates which distinguishes Langerhans' cell granulomatosis and leads to the destruction seen.

In our patient the presence of focal aggregates of Langerhans' cells in association with clinical, physiological, and radiological deterioration confirms recurrence of disease. The associated increased requirement for nasal desmopressin is compatible with development of new granulomas in the pituitary/hypothalamus although this was not formally assessed by MRI scanning.

Langerhans' cells are potent immune accessory cells whose normal role is to present antigen to lymphocytes.[5] However, the initiating factor in Langerhans' cell granulomatosis is unknown although the condition is more common in smokers. Recurrence of the disease after transplantation supports the view that the primary abnormality lies in the Langerhans' cells or precursor dendritic cells.

There are no controlled trials of treatment of Langerhans' cell granulomatosis. Many patients are asymptomatic and require no therapy other than advice to stop smoking and observation. For symptomatic patients corticosteroids are often effective.[6] Cytotoxic drugs such as cyclophosphamide have been used in patients not responding to corticosteroids and those with systemic disease.[7] We elected to use cyclophosphamide as the patient was already on prednisolone and, in addition to recurrent pulmonary disease, there was also evidence of systemic activity with increased requirement for nasal desmopressin. There was an improvement in lung function and reduction in the requirement of nasal desmopressin, confirming its efficacy.

We have successfully performed lung transplantation on four other patients with Langerhans' cell granulomatosis and reviewed the pathology of all biopsy specimens. In one other case one biopsy specimen showed aggregates of S100 staining cells but only to a mild degree and not associated with any symptoms or changes in chest radiographs or pulmonary physiology. Large aggregates of Langerhans' cells have not been found in any other patients who have undergone lung transplantation at our institution including the three other patients transplanted for Langerhans' cell granulomatosis.

In summary, recurrent focal aggregates of Langerhans' cells were found in two patients transplanted for Langerhans' cell granulomatosis. In one case this was associated with clinical, physiological, and radiological evidence of disease recurrence. Initiation of treatment with cyclophosphamide was associated with rapid improvement in symptoms and lung physiology. Recurrence of Langerhans' cell granulomatosis in transplanted lungs has implications for the pathogenesis of the disease in keeping with the primary abnormality lying with the Langerhans' or dendritic cells themselves.

1 Hance AJ, Cadronel J, Soler P, *et al.* Pulmonary and extrapulmonary Langerhans' cell granulomatosis (histiocytosis X). *Semin Respir Med* 1988;**9**:349–68.
2 Costabel U, Corrin B. Rare interstitial lung disorders. In: Brewis RAL, Corrin B, Geddes DM, Gibson GJ, eds. *Respiratory medicine.* 2nd ed. London: WB Saunders, 1995: 1453–73.
3 Egan TM, Detterbeck FC, Keagy BA, *et al.* Single lung transplantation for eosinophilic granulomatosis. *Southern Med J* 1989;**85**:551–3.
4 Beckstead JH, Wood GS, Turner RR. Histiocytosis X cells and Langerhans' cells: enzyme histochemical and immunologic similarities. *Hum Pathol* 1984;**15**:826–33.
5 Hance AJ. Pulmonary immune cells in health and disease: dendritic cells and Langerhans' cells. *Eur Respir J* 1993;**6**:1213–20.
6 Schonfeld N, Frank W, Wenig S, *et al.* Clinical and radiologic features, lung function and therapeutic results in pulmonary histiocytosis X. *Respiration* 1993;**60**:38–44.
7 Greenberger JS, Crocker AC, Vawter G, *et al.* Results of treatment of 127 patients with systemic histiocytosis X. *Medicine* 1981;**60**:311–5.

Thorax: first published as 10.1136/thx.53.4.323 on 1 April 1998. Downloaded from http://thorax.bmj.com/ on April 19, 2024 by guest. Protected by copyright.