

the most frequent clinical manifestation was enteritis. As the authors point out, the subtype more commonly reported to be associated with empyema is *S typhi* which has been reported in case reports from India. The spectrum of salmonella infection in the UK is, however, changing, with an increasing incidence of *S enteritidis*.

Jeanfaivre *et al* (pp 106–7) document a case of bilateral eosinophilic pleural effusions due to infection with *Toxocara canis*. Eosinophilic effusions are exceedingly rare and this case demonstrates a most unusual manifestation of *Toxocara*. We found one other case in the literature of an eosinophilic effusion complicating recovery after acute hepatitis A infection.

These cases, although fascinating, will have little influence on clinical practice for most of us. There is, however, further fuel for debate

on the association between lung cancer and empyema which is as yet poorly understood.

- 1 Witz J, Roeslin N. Postpneumonectomy empyema does not improve survival in bronchogenic carcinoma. *Ann Thorac Surg* 1983;36:529–31.
- 2 Daido K, Arita K, Doi M, Nambu S, Asaoku H, Nagashima A, *et al*. A clinical study on intrathoracic malignant lymphoma with chronic tuberculous pyothorax. *Jap J Thor Dis* 1991;29:866–72.
- 3 Ichiba S, Shimizu N, Kawasaki S, Aoe M, Kajitani N, Hara K, *et al*. A case of malignant lymphoma arising from the chest wall in chronic empyema. *Jap J Thorac Surg* 1991;44:739–42.
- 4 Fukayama M, Ibuka T, Hayashi Y, Ooba T, Koike M, Mizutani S. Epstein-Barr virus in pyothorax-associated pleural lymphoma. *Am J Pathol* 1993;143:1044–9.
- 5 Myoui A, Aozasa K, Iuchi K, Mori T, Yamamoto S, Kuratsu S, *et al*. Soft tissue sarcoma of the pleural cavity. *Cancer* 1991;68:1550–4.
- 6 Roviato G, Sartori F, Calabro F, Varoli F. The association of pleural mesothelioma and tuberculosis. *Am Rev Respir Dis* 1982;126:569–71.
- 7 Wolfe M, Armstrong D, Louria D, Blevins A. Salmonellosis in patients with neoplastic disease. *Arch Intern Med* 1971;128:546–54.

Thorax 1996;51:108–109

Myasthenia gravis presenting with stridor

J A Hanson, C J Lueck, D J Thomas

Abstract

The case is described of a 72 year old woman who presented with a two year history of exertional stridor in whom the diagnosis of myasthenia gravis was delayed. Although an uncommon cause, myasthenia gravis should be included in the differential diagnosis of stridor.

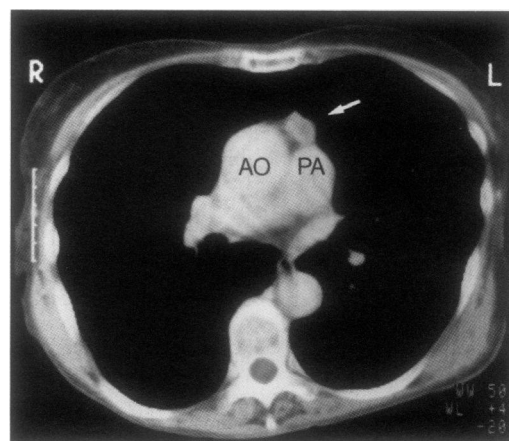
(Thorax 1996;51:108–109)

Keywords: stridor, myasthenia gravis, malignant thymoma.

There is general awareness that myasthenia gravis causes respiratory complications, particularly ventilatory muscle weakness. However, extrathoracic airways obstruction due to vocal cord paresis is rarely reported and probably underrecognised.¹ Cases of mild laryngeal dysfunction may be completely overlooked without inspiratory lung function studies. We describe a patient who presented with exertional stridor in whom the diagnosis of myasthenia gravis was delayed by two years.

Case report

A 72 year old woman gave a two year history of exertional breathlessness accompanied by stridor. At rest her breathing was silent, but after starting to walk she developed noisy inspiration which limited her exercise tolerance to a few hundred yards. A year later she had developed chewing difficulties, with fatigue of the jaw muscles and slowness of swallowing.



Computed tomographic scan of superior mediastinum showing 2 cm thymoma lying anterior to main pulmonary artery (PA) and ascending aorta (AO).

These symptoms had caused a decline in her general state to the point where she had been admitted to a psychogeriatric unit where she was diagnosed as having depression. It was only when she developed slurring of speech, with the need to elevate her lower jaw manually when chewing, that she was referred to a neurologist. She had a past history of mild hypertension, smoked 20 cigarettes daily, and was taking nifedipine and paroxetine. On direct questioning she admitted to previous episodes of transient diplopia.

General and neurological examination at rest was normal. Shoulder girdle weakness developed with fatigue, and minimal exertion precipitated stridor. A Tensilon test showed that stridor improved, as did swallowing, following anticholinesterase administration. Electromyographic findings were suggestive of disordered neuromuscular transmission, particularly in the jaw muscles. Acetylcholine receptor antibodies were strongly positive at 136×10^{-10} mmol/l and striated muscle antibodies were positive. The results of lung function studies suggested extrathoracic airways obstruction with a reduced peak inspiratory

Department of
Neurology,
St Mary's Hospital,
London W2 1NY, UK
J A Hanson
C J Lueck
D J Thomas

Correspondence to:
Dr D J Thomas.

Received 3 August 1994
Returned to authors
11 November 1994
Revised version received
29 December 1994
Accepted for publication
5 January 1995

flow rate of 0.73 l/s (predicted >2.66 l/s). The inspiratory mouth pressure was reduced at 25 cm H₂O. Fiberoptic laryngoscopy showed partially abducted vocal cords with sluggish movement, but no structural abnormality. Routine blood tests including arterial gas tensions, thyroid function, and erythrocyte sedimentation rate were normal. A scan revealed a small thymoma (figure).

She was initially treated with pyridostigmine, 60 mg qds, and propantheline, 15 mg tds, but she deteriorated and required the addition of corticosteroids and plasma exchange therapy. She underwent thymectomy as soon as her general condition permitted. The thymic glandular tissue contained a malignant thymoma with invasion of its fibrous capsule, but low mitotic rate and no evidence of nuclear atypia. Postoperatively her respiratory symptoms improved considerably, with resolution of stridor, allowing reduction of the corticosteroid and pyridostigmine doses.

Discussion

Myasthenia gravis can affect striated muscle anywhere in the body, including the intrinsic muscles of the larynx. Laryngeal muscles have a high density of neuromuscular junctions but symptoms of stridor and dysphonia, due to weakness of vocal cord abduction and adduction, are uncommon. In the series of 147 patients with myasthenia gravis reported by Calcaterra *et al*² only four presented with stridor. The connection with myasthenia may not be appreciated, particularly if stridor is a presenting feature. Our patient was felt for some months to have a psychiatric condition because of her general debility and eating disorder.

It was the development of the characteristic symptom of holding up the lower jaw whilst chewing that first suggested the true diagnosis.^{2,3}

Extrathoracic airways obstruction is probably an underrecognised feature of myasthenia gravis. In 1966 Friedman and Goffin first documented vocal cord weakness in a patient with myasthenia.⁴ Schmidt-Nowara *et al* reported a myasthenic patient with paroxysmal stridor.¹ By analysing both respiratory muscle and upper airway function they showed that the airways obstruction was due to vocal cord paresis. They pointed out that, whilst ventilatory insufficiency can be monitored by spirometry, the presence of extrathoracic airways obstruction is easily missed without inspiratory lung function studies. The frequency of this problem may therefore be underestimated.

We are aware of five reports of stridor as a presenting feature of myasthenia gravis in adults since 1972, and in two of these a precipitating factor was identified (exposure to chlorine gas and general anaesthesia with suxamethonium).^{1,5-8}

- 1 Schmidt-Nowara WW, Marder EJ, Feil PA. Respiratory failure in myasthenia gravis due to vocal cord paresis. *Arch Neurol* 1984;41:567-8.
- 2 Calcaterra TC, Stern F, Herrmann C Jr, Mulder DG. The otolaryngologist's role in myasthenia gravis. *Trans Am Acad Ophthalmol Otolaryngol* 1972;76:308-12.
- 3 Neal GD, Clarke LR. Neuromuscular disorders. *Otolaryngol Clin North Am* 1987;20:195-201.
- 4 Friedman S, Goffin FB. Abductor vocal weakness in myasthenia gravis: report of a case. *Laryngoscope* 1966;76:1520-3.
- 5 Job A, Raman R, Gnanamuthu C. Laryngeal stridor in myasthenia gravis. *J Laryngol Otol* 1992;106:633-4.
- 6 Fairley JW, Hughes M. Acute stridor due to bilateral vocal fold paralysis as a presenting sign of myasthenia gravis. *J Laryngol Otol* 1992;106:737-8.
- 7 Foulks CJ. Myasthenia gravis presenting as laryngeal stridor after exposure to chlorine gas. *South Med J* 1981;74:1423-4.
- 8 Colp C, Kriplani L, Nussbaum M. Vocal cord paralysis in myasthenia gravis following anaesthesia. *Chest* 1980;77:218-20.