Case reports

Bordetella bronchiseptica pneumonia in a patient with AIDS

Javier de la Fuente, Carmen Albo, Avelino Rodríguez, Bernardo Sopeña, Cesar Martínez

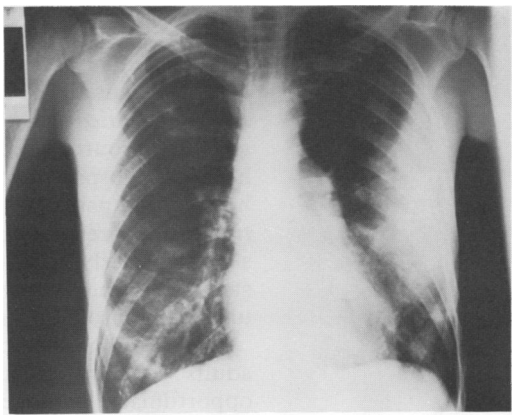

Chest radiograph obtained on admission showing lingula consolidation and diffuse bilateral pulmonary infiltrates.

Abstract

***Bordetella bronchiseptica* is recognised as a respiratory tract pathogen in many mammalian species, but has rarely been implicated in human infection. A case is reported of pneumonia caused by *B bronchiseptica* in a patient suffering from acquired immunodeficiency syndrome (AIDS).**

(*Thorax* 1994;**49**:719–720)

Bordetella bronchiseptica is a common respiratory tract commensal of wild and domestic animals, occasionally responsible for outbreaks of fatal tracheobronchitis, pneumonia, and septicaemia. It has rarely been implicated in infections in humans.[1] We report a case of pneumonia caused by this organism in a patient with AIDS which was successfully treated with ciprofloxacin.

Case report

A 28 year old man, an intravenous heroin user, was admitted in June 1992 with a four day history of high fever, cough, pleuritic chest pain, and progressive dyspnoea. Three years earlier a Western blot for antibodies to HIV was positive. The patient's medical history revealed pulmonary tuberculosis six years previously (for which he was treated with a nine month course of isoniazid, rifampicin, and ethambutol), and oro-oesophagical candidiasis four months before admission. Two months before admission he had suffered from pneumococcal pneumonia which was treated with amoxycillin-clavulanic acid for 18 days. Three weeks before admission he had been in contact with dogs and cats at a detoxification farm. He had been taking zidovudine 500 mg daily for four months. He was not taking any other medication.

On physical examination he was cachectic with moderate respiratory distress and a temperature of 39°C, pulse 110/min, blood pressure 95/60 mm Hg, and tachypnoea of 28/min. Chest auscultation revealed decreased breath sounds, bilateral basal crackles, and a pleural friction rub in the left hemithorax. Lymphadenopathy was present in lateral/cervical, supraclavicular, and inguinal nodes.

The total peripheral leucocyte count was $2{\cdot}8 \times 10^9$/l, with 70% polymorphonuclear neutrophils, 13% band forms, 10% lymphocytes, and 7% monocytes. The CD4 count was 73/mm^3 (normal value >400/mm^3). The haemoglobin and platelet count were 8·4 g/dl and 51×10^9/l respectively. Arterial blood gases obtained while the patient was breathing room air revealed pH 7·52, Pa_{O_2} 6·5 kPa, Pa_{CO_2} 3·8 kPa. Chest radiography (figure) revealed diffuse bilateral pulmonary infiltrates with lingular consolidation.

Plasma sodium and lactate dehydrogenase levels were 126 mEq/l and 653 IU/l, respectively. A Gram stain of sputum contained >25 neutrophils and <10 epithelial cells per low power field and abundant, pleomorphic Gram negative coccobacilli. Culture (Charcoal blood medium) grew *B bronchiseptica*, and smears for acid-fast bacilli, fungi, direct immunofluorescence for *Pneumocystis carinii* and fluorescent antibody test for *Legionella* were all negative. Three blood cultures and sputum culture in Löwenstein medium remained negative. Empirical antimicrobial therapy was commenced with intravenous cefotaxime and vancomycin and oral cotrimoxazole for four days without a response. Based on minimum inhibitory concentrations, the initial antibiotic regimen was changed to intravenous ciprofloxacin, 200 mg twice daily. Four days later the patient became afebrile, and cough and dyspnoea disappeared. After the eighth day ciprofloxacin was given orally for three more weeks. Arterial blood gases and the chest radiograph gradually improved. Sputum cultures taken on the day of discharge and one month later were negative.

Discussion

Bordetella bronchiseptica is a pleomorphic, motile, non-fermentative Gram negative

Infectious Disease Section
J de la Fuente
B Sopeña
C Martínez

Internal Medicine Service
C Albo
A Rodríguez

Hospital Xeral-Cies, Vigo, Spain

Reprint requests to: Dr J de la Fuente Aguado, Nicaragua 10, 3 B, 36203 Vigo, Spain.

Received 24 June 1993
Returned to authors 13 August 1993
Revised version received 20 October 1993
Accepted for publication 26 October 1993

coccobacillus first described in 1910.[2] It causes respiratory infections in a wide variety of wild and laboratory animals.[1]

Although the transmission of bacteria from animals to humans has been documented in animal caretakers and children causing a mild upper respiratory tract and pertussis-like illness respectively, close contact with ill animals is not essential to contract this infection.[3] *B bronchiseptica* has been isolated from sputum and other sources and has been considered a harmless hospital acquired organism. Most hospitalised patients harbouring *B bronchiseptica* in their respiratory tract are elderly with serious underlying diseases requiring tracheostomies or endotracheal intubation, and have undergone prolonged courses of antibiotics.[3]

Clinical *B bronchiseptica* infection in healthy adults is a very unusual event. Its role as an opportunistic pathogen in the immunocompromised host, however, has been increasingly recognised. In a recent review Woolfrey and Moody described 25 cases of human infections due to *B bronchiseptica*, most of which involved the respiratory tract.[4]

Bordetella bronchiseptica pneumonia has been reported in 11 patients, of whom six were included in the above review.[4-9] In nine patients there was immunosuppression due to underlying disease or treatment: three cases of AIDS, two of chronic lymphocytic leukaemia, one of heart transplantation, one of Crohn's disease, one of alcoholism and malnutrition, and one Hodgkin's disease. *Bordetella bronchiseptica* was recovered more often from sputum and bronchoalveolar lavage fluid, although occasionally it was isolated from lung tissue. The chest radiograph usually showed patchy infiltrates even though airspace consolidation and cavitation were described. Despite treatment with antibiotics the prognosis was poor and three patients died.[4 6]

The virulence of *B bronchiseptica* is largely based on its capacity to impair ciliary function and to produce an adenylate cyclase which diminishes the bactericidal activity of neutrophils and macrophages.[4] The latter, besides altering underlying immune status, may be responsible for the disparity observed between in vitro antibiotic sensitivity and clinical response. The use of antibiotics capable of penetrating phagocytes has therefore been proposed,[4] and ciprofloxacin, which is taken up rapidly by macrophages,[10] has a good activity against *B bronchiseptica*.[4] It was clinically tested in four cases before ours: in two patients with AIDS ciprofloxacin failed to eradicate *B bronchiseptica* from the respiratory tract,[6 8] but a heart transplant patient[5] and another patient with AIDS[9] had an excellent response.

Our patient may have acquired *B bronchiseptica* at a detoxification farm. He was successfully treated with ciprofloxacin with sputum sterilisation without any short term relapse. We believe that *B bronchiseptica* should be added to the long list of opportunistic pathogens implicated in respiratory infections of immunocompromised hosts. A previous history of exposure to ill animals should raise clinical suspicion.

1 Goodnow RA. Biology of *Bordetella bronchiseptica*. *Microbiol Rev* 1980;**44**:722–38.
2 Ferry NS. Preliminary report of the bacterial findings of canine distemper. *Am Vet Rev* 1910;**37**:499–503.
3 Gardner P, Griffin WB, Swartz MN, Kunz LJ. Nonfermentative gram-negative bacilli of nosocomial interest. *Am J Med* 1970;**48**:735–49.
4 Woolfrey BF, Moody JA. Human infections associated with *Bordetella bronchiseptica*. *Clin Microbiol Rev* 1991;**4**:243–55.
5 Chauncey JB, Schaberg DR. Instertitial pneumonia caused by *Bordetella bronchiseptica* in a heart transplant patient. *Transplantation* 1990;**49**:917–9.
6 Amador C, Chiner E, Calpe JL, Ortiz V, Martinez C, Pasquau F. Pneumonia due to *Bordetella bronchiseptica* in a patient with AIDS. *Rev Infect Dis* 1991;**13**:771–2.
7 Decker GR, Lavelle JP, Kumar PN, Pierce PF. Pneumonia due to *Bordetella bronchiseptica* in a patient with AIDS. *Rev Infect Dis* 1991;**13**:1250–1.
8 Ng VL, Boggs JM, York MK, Golden JA, Hollander H, Hadley WK. Recovery of *Bordetella bronchiseptica* from patients with AIDS. *Clin Infect Dis* 1992;**15**:376–7.
9 Cuesta J, Hermosilla T, Gros B, Zabala S, Garcia MC. Neumonia por *Bordetella bronchiseptica* en un paciente con enfermedad de Crohn. *An Med Intern (Madrid)* 1991;**8**:525–6.
10 Easmon CFS, Crane JP. Uptake of ciprofloxacin by macrophages. *J Clin Pathol* 1985;**38**:442–4.