Thorax 1989;**44**:298–302

Differential lung function in an infant with the Swyer-James syndrome

A AVITAL, D L SHULMAN, E BAR-YISHAY, N NOVISKI, J SCHACHTER, Y KRAUSZ, S GODFREY

From the Pulmonary Function Laboratory and Departments of Paediatrics, Anaesthesia, and Medical Biophysics and Nuclear Medicine, Hadassah University Hospital, Jerusalem, Israel

ABSTRACT A previously healthy two year old boy had an adenoviral infection at the age of 13 months and developed hyperlucency of the left lung, chronic respiratory distress, and failure to thrive. Bronchodilators and steroid treatment had no effect. Radionuclide lung scans using an intravenous bolus of xenon-133 both before and after treatment showed substantially reduced function on the hyperlucent side and modestly reduced function on the other side. Fibreoptic bronchoscopy showed no structural abnormalities. Partial forced expiratory flow volume (PEFV) curves, generated from end inspiration by rapid compression of the chest wall with an inflatable jacket, were obtained from the total respiratory system and from each lung separately by inflating a Fogarty catheter in the contralateral mainstem bronchus. Expiratory flow rates and volumes during both tidal breathing and PEFV manoeuvres were considerably decreased in the hyperlucent lung. PEFV curves from the "healthy" right lung and from the total respiratory system were similar in shape and showed a moderately obstructive pattern. The right lung ventilated about four times as much as the left when measured by bronchospirometry and about three times as much when measured by the radionuclide technique. The lung scans appeared to reflect adequately the functional abnormality in this infant with the Swyer-James syndrome.

Introduction

Swyer and James[1] originally described a six year old boy with one hyperlucent lung after repeated episodes of bronchitis and bronchopneumonia. The chest radiograph showed translucency of the right lung with a substantial decrease in its vascular markings. The right hemithorax and lung were smaller than the left and fluoroscopy showed the heart to be shifted to the right on inspiration, with some restriction of respiratory excursion of the right hemidiaphragm. About the same time Macleod[2] reported nine adults with increased unilateral translucency and decreased vascular markings. The cause of the unilateral hyperlucent lung syndrome has been thought to be viral infection, especially infection with adenovirus or measles virus,[3–5] often with bronchiolitis obliterans.[6 7]

Lung function tests performed on older children who could cooperate and adults with unilateral hyperlucent lung syndrome generally show an obstructive pattern[5 8] with a variable reversible component. The contribution of the hyperlucent lung to total lung function has been measured in adults by bronchospirometry[9–12] and ventilation-perfusion lung scanning, the latter showing poor perfusion and ventilation on the affected side.[12 13] To the best of our knowledge, the extent of regional or total functional impairment of the respiratory system has not been evaluated in young children with unilateral hyperlucent lung syndrome. Infants and preschool children are unable to cooperate in conventional pulmonary function testing but total and regional lung function has been evaluated indirectly by the use of radionuclide imaging and washout curves.[14 15]

Bronchospirometry and divided lung function tests were introduced in 1932 by Jacobaeus and coworkers[16] and have been used in adults, especially before lung surgery.[17–19] Recently, a new technique for obtaining partial forced expiratory flow-volume (PEFV) curves in infants and young children was developed in our laboratory.[8 20] This technique requires the application

Address for reprint requests: Professor S Godfrey, Department of Pediatrics, Hadassah University Hospital, POB 24035 Jerusalem, Israel.

Accepted 11 January 1989

Thorax: first published as 10.1136/thx.44.4.298 on 1 April 1989. Downloaded from http://thorax.bmj.com/ on April 23, 2024 by guest. Protected by copyright.

of pressure to the chest wall at end inspiration, causing a sudden, maximal expiratory flow to residual volume. Taking advantage of the new technique, we were able to study the function of each lung separately in an infant with Swyer-James syndrome and to compare the results with those obtained by a radionuclide technique.

Case history

The boy, now aged three years, was born after 40 weeks' gestation by forceps delivery with a birth weight of 3350 g. His mother is a nurse and assured us that he was healthy until the age of 13 months except for a few mild upper respiratory tract infections, from which he recovered completely. At that age he was admitted to another hospital with a history of high fever, cough, and dyspnoea for the previous week. Examination on admission showed respiratory distress with dyspnoea, grunting, pharyngitis, conjunctivitis, and bilateral otitis media. Crepitations, prolonged expiration, and wheezes were heard over both lungs. The liver was enlarged 7 cm and the spleen 4 cm below the costal margin. His chest radiograph showed infiltrates around both hila and in the right middle lobe and left lower lobe with the development later of hyperinflation of the left lower lobe. The child was hypoxaemic with an arterial oxygen tension (Pao_2) of 6·5 kPa. His white blood cell count was $8·3 \times 10^9$/l with 60% neutrophils, liver enzyme activities (serum aspartate transaminase and lactate dehydrogenase) were modestly increased, and blood cultures and paracentesis fluid from his ear were sterile. He was initially treated with antibiotics, though the results of the investigations indicated a viral infection and subsequently the adenovirus titres rose from 1/20 to 1/960 within two weeks.

He was referred to our department at the age of 15 months for further investigation. The child was tachypnoeic (60 breaths/min) with decreased breath sounds over the left lung and diffuse crepitations and wheeze, more pronounced over the left lung. Chest radiography showed a smaller and hyperlucent left lung. A therapeutic trial of steroids, theophylline, and inhaled salbutamol was undertaken for two weeks, with no appreciable improvement. Over the next six months he had repeated trials of alternate morning oral prednisone and inhaled nebulised budesonide with no evidence of improvement. The following special investigations were performed.

Special investigations

METHODS

Xenon radionuclide lung scans

A lung scan was performed as described for infants and young children,[14 15] except that we used xenon-133 instead of nitrogen-13. In brief, the infant lay supine over a gamma camera; ^{133}Xe was injected as a bolus via a peripheral vein while the lungs were scanned for three minutes and the data stored on a computer. The computer image of each lung field was divided subsequently into an upper and a lower zone and exponential analysis of the washout of ^{133}Xe from each zone by ventilation was performed. The perfusion of each zone was normalised by dividing the peak counts by the area of the image of the zone and expressing this as a fraction of the normalised whole lung peak count. The normal value for this index in our laboratory is 1·02 (SD 0·04), based on measurement of 113 healthy lung zones in 33 children under three years (K Uwyyed, personal communication). An index of adequacy of washout was obtained by calculating the height/area of the washout curves for each zone. If ventilation and perfusion are reasonably well matched this index is the fractional ventilation, but otherwise it reflects both ventilation-perfusion matching and fractional ventilation. The mean value for this in our laboratory for a normal child of this age is 3·73 (SD 0·32) (K Uwyyed, personal communication). The tests were first performed when the boy was 16 months old, before any trial of treatment, and again when he was 22 months, after prolonged treatment with corticosteroids.

Fibreoptic bronchoscopy and divided lung function

Because of the rapid development of unilateral hyperlucency we decided to undertake fibreoptic bronchoscopy to exclude any treatable cause of local obstruction and to obtain sputum for culture. The bronchoscopy was performed after premedication with chloral hydrate and pethidine, lignocaine being used for topical anaesthesia. Oxygen was delivered to a face mask, through which an infant bronchoscope (Olympus BF3CF) was passed. Arterial oxygen saturation, monitored throughout by pulse oximetry, never fell below 90%. At bronchoscopy there were purulent secretions in the left bronchial tree and *Haemophilus influenzae* was cultured subsequently. There were no signs of foreign body aspiration or granulation tissue.

Having obtained informed parental consent, we carried out divided pulmonary function studies after the completion of routine bronchoscopy to define the functional abnormality more exactly. A Fogarty catheter (41-023-5F, outside diameter 1·6 mm) was introduced through the nose into the trachea and the infant was prepared for the study of forced expired flow-volume relationships with the use of the inflatable jacket system.[20] The infant breathed through a face mask held in place by silicone putty, to which a pneumotachograph was attached. The tubing of the

Thorax: first published as 10.1136/thx.44.4.298 on 1 April 1989. Downloaded from http://thorax.bmj.com/ on April 23, 2024 by guest. Protected by copyright.

Fogarty catheter passed through the putty seal. As the infant breathed quietly the tidal flow-volume loops were observed on an oscilloscope. At end inspiration the jacket was rapidly inflated by opening the tap and the chest and abdomen were compressed, producing a rapid expiration from end inspiration to near residual volume. The pressure was then released and tidal breathing was allowed for at least 30 seconds before the next partial expiratory flow-volume (PEFV) manoeuvre.

After periods of quiet breathing PEFV curves were generated with the Fogarty catheter lying deflated in the trachea, then with the balloon inflated alternately in the left and right main bronchus, and finally with the Fogarty catheter completely removed. In each case the position of the balloon was checked before the test by the bronchoscope, which was withdrawn completely before the compression. Different jacket pressures in the range 20–80 mm Hg were used to obtain the maximum flow and seven to 10 flow-volume loops were obtained for each site. To ensure that the infant was not unduly distressed by occlusion of the better functioning (right) lung, the balloon was occluded for only one or two respiratory cycles in the right main bronchus, sufficient to allow the performance of the PEFV manoeuvre after one or two "normal" breaths. For the analysis of quiet breathing records were obtained over 30 second periods from both lungs together and from the better functioning right lung, but over only one 15 second period from the poorer functioning left lung.

All data recorded on the tape were subsequently analysed with the help of a computer (PDP 11/23). Each PEFV curve was displayed with the preceding one or two tidal breaths superimposed to determine the level of functional residual capacity (FRC). Curves

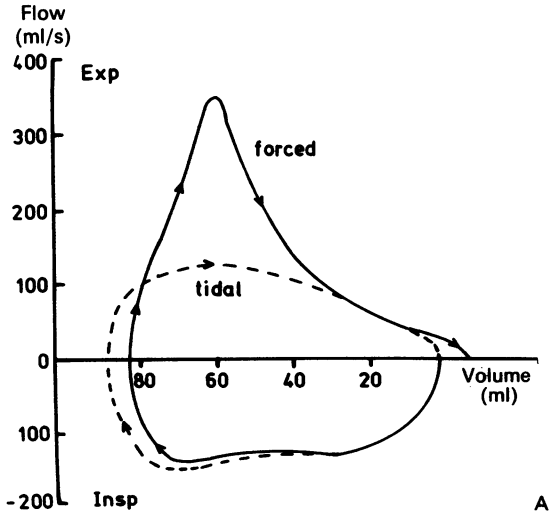

A

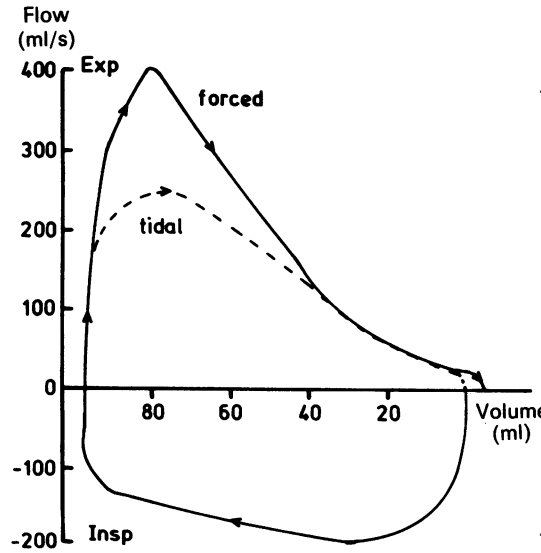

B

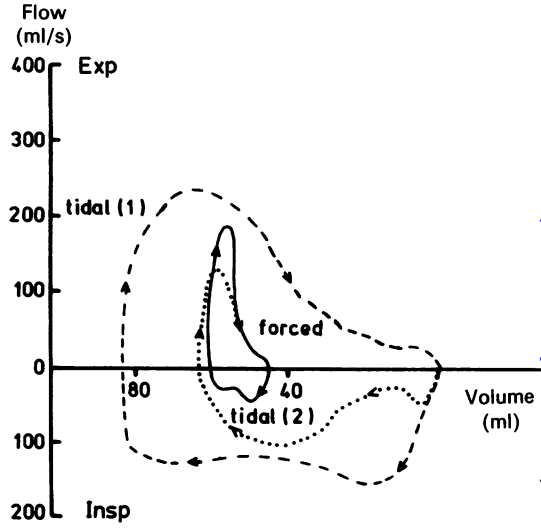

C

Partial forced expiratory flow-volume loops from both lungs together (A), from the relatively normal right lung (B), and from the hyperlucent left lung (C). In (A) and (B) the tidal flow-volume loop preceding the forced expiration is shown as the dashed line and the forced flow-volume loop by the solid line with inspiration below and forced expiration above the zero flow line. The tidal and forced flow-volume loops overlap considerably. In (C) the tidal flow-volume loop preceding the occlusion of the right bronchus is shown by the dashed line (tidal 1), the tidal flow-volume loop after occlusion by the dotted line (tidal 2), and the forced flow-volume loop by the solid line.

Thorax: first published as 10.1136/thx.44.4.298 on 1 April 1989. Downloaded from http://thorax.bmj.com/ on April 23, 2024 by guest. Protected by copyright.

Results of xenon-133 studies of the right and left lungs before and after anti-asthma treatment

Zone	Before treatment		After treatment	
	Right	Left	Right	Left
	Normalised peak counts (perfusion)			
Upper	1·2	0·9	1·5	0·7
Lower	1·2	0·6	1·4	0·4
	Height/area of washout curve (ventilation)			
Upper	2·5	0·9	2·7	1·1
Lower	2·5	0·7	2·6	0·5

were considered technically acceptable if they met published criteria.[8 21]

Results

Xenon studies

The results of ^{133}Xe scanning are shown in the table. There were no major differences between the studies carried out before and after treatment and no evidence of any change in function as a result of the medication, except that the differences between the lungs were greater after treatment. In both studies the normalised peak counts (representing perfusion) were somewhat increased over the whole of the "healthy" right lung, but were diminished over the hyperlucent left lung, especially over the left lower zone. The washout index of ^{133}Xe ("ventilation") was moderately reduced on the right (68% predicted) and substantially decreased on the left (21% predicted), especially over the left lower zone. The right lung had about three times as much perfusion and ventilation as the left lung.

Divided lung function tests

The bronchoscopy and divided lung function tests were performed when the child was 24 months, two months after the second radionuclide study. The mean tidal volume of both lungs together was 75 (SD 4) ml and total minute ventilation 2·02 l/min. The mean tidal volume of the right lung was 71 (3) ml and that of the left lung 17 (2) ml, with corresponding minute ventilation of 1·94 and 0·53 l/min respectively.

There was no difference in the PEFV curves obtained with the Fogarty catheter deflated in the trachea and with it removed entirely. In both cases the curves showed a severely obstructive pattern, being convex with respect to the volume axis and with the flow rate at low lung volumes during tidal expiration lying close to the PEFV curve (figure A).

The PEFV curves obtained from the right lung and the hyperlucent left lung are shown in the figure (B and C). All the flow-volume loops in the figure were lined up with the FRC of the preceding breath, shown as zero on the volume scale. In the case of both lungs together the FRC was that of the breath preceding the squeeze, and in the case of the individual lungs it was the FRC of the breath preceding the occlusion of the contralateral bronchus. The forced expired flows obtained from the right lung (figure B) at low lung volumes were the same as those of the total respiratory system and similarly indicated a severely obstructed pattern. When the bronchus of the better functioning right lung was occluded the volume became unstable and there was an apparent increase in FRC of about 60 ml (figure C, dotted line). The PEFV curve from the left (hyperlucent) lung was very abnormal, with extremely low flow rates and volume.

Discussion

The infant in this investigation showed typical features of the Swyer-James syndrome, which in this case followed an adenovirus infection. It has generally been accepted that the disease causes an obliterative bronchiolitis of the hyperlucent lung[6 7] with a consequent decrease in function, but that for some reason the other lung escapes significant damage. Our radionuclide lung function studies with ^{133}Xe (table) supported this idea as the right lung was functioning relatively well. In the divided lung function tests the hyperlucent lung, as expected, functioned very poorly and contributed something less than a quarter of the minute ventilation with a tidal volume less than the predicted anatomical dead speace of 23 ml. Even in the "healthy" right lung, however, the PEFV curve had a very obstructive appearance, suggesting that the disease had been more generalised although affecting one lung more than the other. The reason for the apparent increase in FRC when the relatively healthy right main bronchus was occluded is uncertain; the possibility that some air leaked past the balloon and was trapped in the "healthy" lung on expiration cannot be excluded.

As the radionuclide test is far easier to perform than the divided lung function tests, we may ask what degree of concurrence there was between the results of the two tests. In previous studies using ^{13}N we found the normal range for fractional ventilation after an inhaled bolus was 2·08–3·90/min.[14] We pointed out, however, that the index should be age dependent as the alveolar ventilation per unit lung volume is greater in infants than in older children or adults. We calculated that the index should be about 4·00/min in the newborn and 3·85/min for children aged 1–5 years. Our current studies using an intravenous bolus of ^{133}Xe indicate a similar age corrected normal mean value of 3·73 (SD 0·32)/min. Thus the washout index (height/area) appears to reflect fractional ventilation, at least in healthy lung zones. When there is serious ventilation-perfusion mismatching there should be a greater discrepancy between true fractional ventilation and the intravenous bolus washout index. The

Thorax: first published as 10.1136/thx.44.4.298 on 1 April 1989. Downloaded from http://thorax.bmj.com/ on April 23, 2024 by guest. Protected by copyright.

right lung of the present patient had a washout index about 68% of the predicted rate, which was certainly abnormal but probably underestimated the true fractional ventilation to some degree because of ventilation-perfusion mismatching. It is interesting therefore that the ventilation of the right lung calculated from the ^{133}Xe scan was about three times that of the left and the direct measurement of ventilation in the divided lung function tests showed that the ventilation of the right lung alone was about four times that of the left. Even so, the similarity of these estimates of relative ventilation is encouraging.

In conclusion, in this infant with Swyer-James syndrome both the isotopic lung scan and the divided lung function tests showed both lungs to be affected, one being much worse than the other. The natural history of the disease and the evidence of adenoviral infection point to bronchiolitis obliterans as the underlying pathological process, although we did not feel justified in undertaking a lung biopsy. The total lack of objective evidence of any response to corticosteroids and bronchodilators is important because we have seen several such patients, referred to us with a diagnosis of asthma resistant to treatment. Divided lung function tests add to our understanding of the pathophysiological disturbances and can be performed in patients undergoing fibreoptic bronchoscopy. In view of the good agreement between the results of the radionuclide studies and the divided lung function tests, however, we do not believe that there is a need for divided lung function tests in routine paediatric clinical practice.

References

1 Swyer PR, James GCW. A case of unilateral pulmonary emphysema. *Thorax* 1953;**8**:133–6.

2 Macleod WM. Abnormal transradiancy of one lung. *Thorax* 1954;**9**:147–53.

3 Macpherson RI, Cumming GR, Chernick V. Unilateral hyperlucent lung: a complication of viral pneumonia. *J Can Ass Radiol* 1969;**20**:225–31.

4 Fraser RG, Paré JAP. *Diagnosis of diseases of the chest*. 2nd ed. Vol 3. Philadelphia: Saunders, 1979:1297–475.

5 Spigelblatt L, Rosenfeld R. Hyperlucent lung: long term complication of adenovirus type 7 pneumonia. *J Can Med Ass* 1983;**128**:47–9.

6 Reid L, Simon G. Unilateral lung transradiancy. *Thorax* 1962:**17**:230–9.

7 Reid L, Simon G. The role of alveolar hypoplasia in some types of emphysema. *Br J Dis Chest* 1964;**58**:158–68.

8 Shulman DL, Bar-Yishay E, Beardsmore CS, Beilin B, Godfrey S. Partial forced expiratory flow-volume curves in young children during ketamine anesthesia. *J Appl Physiol* 1987;**63**:44–50.

9 Dark CS, Chrispin AR, Snowden BS. Unbilateral lung transradiancy: a physiological study. *Thorax* 1960; **15**:74–81.

10 Nairn JR, Prime FJ. A physiological study of Macleod's syndrome. *Thorax* 1967;**22**:148–55.

11 Kent DC. Physiological aspects of idiopathic unilateral hyperlucent lung with a review of the literature. *Am Rev Respir Dis* 1964;**90**:202–12.

12 Warrell DA, Hughes JMB, Rosenzweig DY. Cardiopulmonary performance at rest and during exercise in seven patients with increased transradiancy of one lung (Macleod's syndrome). *Thorax* 1970;**25**:587–97.

13 Gordon I, Helms P. Investigating the small lung: which imaging procedure? *Arch Dis Child* 1982;**57**:696–701.

14 Ronchetti R, Stocks J, Freedman N, Glass H, Godfrey S. Clinical application of regional lung function studies in infants and small children using ^{13}N. *Arch Dis Child* 1975;**50**:595–603.

15 Godfrey S, McKenzie S. The place of radioisotopic lung function studies in paediatrics. *Arch Dis Child* 1977;**52**:859–64.

16 Jacobaeus JC, Frenckner P, Bjorkman S. Some attempts at determining the volume and function of each lung separately. *Acta Med Scand* 1932;**79**:174–207.

17 Carlens E. A new flexible double-lumen catheter for bronchospirometry. *J Thorac Surg* 1949;**18**:742–6.

18 Gaensler EA, Maloney JF, Bjork VO. Bronchospirometry II: experimental observations and theoretical considerations of resistance breathing. *J Lab Clin Med* 1952;**39**:935–53.

19 Clark JB, Maher-Loughnan GP. A method of measuring maximum breathing capacities in individual lungs by bronchospirometry. *Tubercle* 1955;**36**:198–204.

20 Taussig LM, Landau LI, Godfrey S, Arad I. Determinants of forced expiratory flows in newborn infants. *J Appl Physiol* 1982;**53**:1220–7.

21 Godfrey S, Bar-Yishay E, Arad I, Landau LI, Taussig LM. Flow-volume curves in infants with lung disease. *Pediatrics* 1983;**72**:517–22.

Thorax: first published as 10.1136/thx.44.4.298 on 1 April 1989. Downloaded from http://thorax.bmj.com/ on April 23, 2024 by guest. Protected by copyright.