

## Metastatic meningioma of the lung

JLTM AUMANN, JMM VANDENBOSCH, JRJ ELBERS, SJSC WAGENAAR

*From the Department of Pulmonary Disease and Pathology, St Antonius Hospital, Nieuwegein, The Netherlands*

A difficult diagnostic problem may be caused by the presence of multiple pulmonary nodules on a chest radiograph. The differential diagnosis includes infection, primary or metastatic tumour (benign or malignant), and the expression of systemic disease such as rheumatoid arthritis and sarcoidosis. This case report describes a patient with multiple lung tumours considered to be due to metastatic meningioma.

### Case report

A 45 year old woman with a long history of allergic asthma was admitted to the St Antonius hospital in April 1984 for investigation of multiple pulmonary nodules that had increased in size on serial chest radiographs.

Five years earlier she had been admitted to hospital because of frontal headaches. There was bilateral papilloedema. An electroencephalogram showed a left frontal area of reduced activity and a left carotid angiogram showed a frontal parasagittal mass. Computed tomography showed a large mass from the frontal bone with oedema, complete compression of the anterior horns, and displacement of structures to the right. There was no evidence of necrosis. A left frontal temporal craniotomy was performed and a large meningioma of the transitional type with invasion of the falx was removed. There were no postoperative complications and up to June 1985 no neurological symptoms suggesting a cerebral relapse have recurred.

On admission to hospital in 1984 the patient was in good health and symptom free. Physical examination showed no abnormalities and, in particular, no neurological dysfunction. Results of routine laboratory tests were normal. The serum concentration of carcinoembryonic antigen was 0.7 ng/ml. No acid fast bacilli of pathogenic bacteria or fungi were found in the sputum or bronchial secretions. A tuberculin test gave a positive result. The chest radiograph and tomograms showed multiple nodular, well demarcated densities, especially in the middle and lower lung fields, varying from 0.2 to 1 cm in diameter but uniform in density. There was no calcification and no cavitation. The pleura, mediastinum, and heart showed no abnormalities. Intravenous pyelography, mammography, and ultrasound examination of the breast and thyroid revealed no tumour. Appearances at bronchoscopy and the results of bronchoalveolar lavage were normal. The cytological appearances of bronchial secretions and the histological appearances of biopsy

material from the right main bronchus and the carina of the right middle lobe were normal.

A left thoracotomy with open lung biopsy was performed. On the surface and in the depth of the lung there were multiple firm, whitish, and well circumscribed nodules ranging from 0.5 to 1 cm in diameter. One nodule from the upper lobe and three from the lower lobe was excised. Tissue samples were frozen in liquid nitrogen for enzyme histochemical and immunohistochemical studies and fixed in glutaraldehyde for electron microscopy. Light microscopy showed sharply demarcated nests of tumour cells located in the interstitial space. They were often located around small veins but an association with bronchioles or arteries could not be shown. The cells were arranged in whorls, bands, and small clusters (fig A-C). The tumour cells were spindle shaped or elongated with an eosinophilic cytoplasm and indistinct cytoplasmic borders. The nuclei were oval and small. In some nests a psammoma body was seen. Examination using Grimelius stain gave a negative result. Electron microscopy showed interdigitating cell processes, numerous typical desmosomes, and absence of basement membranes (fig D). The results of enzyme and immunohistochemical studies in our patient and in a classical meningioma of the transitional type were identical with respect to acid phosphatase, alkaline phosphatase,  $\beta$  glucuronidase, non-specific esterase, ATPase, vimentin, keratin, neurofilament, S100, and 123-C3. On the basis of the findings from light microscopy and electron microscopy and from the histochemical and enzyme histochemical studies a diagnosis of pulmonary metastatic meningioma was made, although a so called pulmonary chemodectoma could be ruled out with certainty.

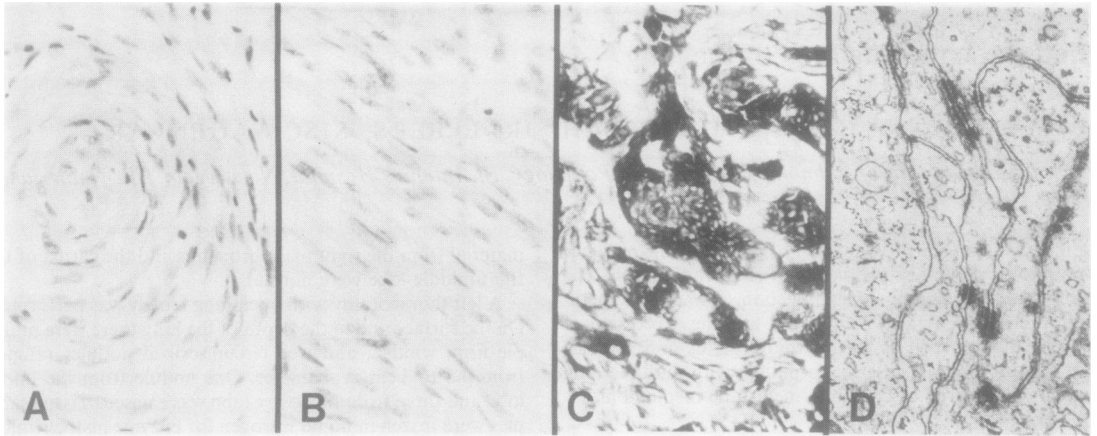
### Discussion

Lung tumours with the histological appearance of meningiomas are very uncommon and are of different origins. On the basis of histological appearances a so called pulmonary chemodectoma cannot be ruled out with certainty. This tumour may also be multiple but is smaller in size (2 mm). Kuhn and Askin<sup>1</sup> and Churg and Warnock<sup>2</sup> pointed to the puzzling ultrastructural similarity between these tumours and meningiomas. We have found no published account of immunohistochemical and enzyme histochemical studies on pulmonary chemodectoma. Perhaps these techniques applied to classical examples of pulmonary chemodectoma could be of further help in differentiating these pulmonary lesions. Primary lung meningioma is extremely rare.<sup>3,4</sup> Light and electron microscopic findings are the same as in our case, but these primary tumours are not multiple.

Reports of extracranial metastasis from apparently

Address for reprint requests: Dr JMM van den Bosch, Department of Pulmonary Disease, St Antonius Hospital, PO Box 2500, 3430 EM Nieuwegein, The Netherlands.

Accepted 11 November 1985



*A and B—Arrangement of tumour cells in whorls and sheets. (Haematoxylin and eosin,  $\times 165$ .) C—Tumour cells positive for adenosine triphosphatase. D—Electron micrograph showing typical desmosomes, cell processes, and absence of basement membranes. ( $\times 8300$ .)*

benign meningiomas are rare.<sup>5 6</sup> Only a few cases of intrapulmonary metastasis have been reported. In these cases previous intracranial surgery had usually been performed.

In our patient, review of the histological appearances of the primary tumour revealed no signs of malignancy. The multiplicity and the appearance of the pulmonary nodules after the craniotomy are, however, strongly suggestive of metastasis.

We thank Dr KP Dingemans, Department of Pathology, University of Amsterdam, for performing the electron microscopical examinations.

#### References

- 1 Kuhn C, Askin FB. The fine structure of so-called minute pulmonary chemodectomas. *Hum Pathol* 1976;6:681-91.
- 2 Churg AM, Warnock ML. So called "minute pulmonary chemodectoma." *Cancer* 1976;37:1759-69.
- 3 Kennitz P, Spormann H, Heinrich P. Meningioma of lung: first report with light and electron microscopic findings. *Ultrastruct Pathol* 1982;3:359-65.
- 4 Chumas JC, Lorelle CA. Pulmonary meningioma: a light- and electron-microscopic study. *Am J Surg Pathol* 1982;6:795-801.
- 5 Glasauer FE, Yuan RH. Intracranial tumors with extracranial metastases: case report and review of the literature. *J Neurosurg* 1963;20:474-93.
- 6 Shuangshoti S, Hongsaprabhas C, Netsky MG. Metastasizing meningioma. *Cancer* 1970;26:832-41.



## Metastatic meningioma of the lung.

J L Aumann, J M van den Bosch, J R Elbers, et al.

*Thorax* 1986 41: 487-488

doi: 10.1136/thx.41.6.487

---

Updated information and services can be found at:

<http://thorax.bmj.com/content/41/6/487.citation>

---

*These include:*

### **Email alerting service**

Receive free email alerts when new articles cite this article. Sign up in the box at the top right corner of the online article.

---

### **Notes**

---

To request permissions go to:

<http://group.bmj.com/group/rights-licensing/permissions>

To order reprints go to:

<http://journals.bmj.com/cgi/reprintform>

To subscribe to BMJ go to:

<http://group.bmj.com/subscribe/>