

Thorax 1985;40:312-313

Short reports

Radiographic changes in humidifier fever

K ANDERSON, CP McSHARRY, G BOYD

From the Department of Respiratory Medicine, Glasgow Royal Infirmary

The association of air conditioning and humidification systems with hypersensitivity pneumonitis has been reported frequently since Banaszak *et al* first described an office outbreak in 1970,¹ when diffuse nodular infiltrates were observed in the chest radiographs of all four patients. Further reports from North America of similar radiological abnormalities^{2,3} associated with hypersensitivity to thermophilic actinomycetes of the farmer's lung type were followed by detailed descriptions of outbreaks of humidifier fever in the United Kingdom⁴⁻⁸ where no radiological changes were found and where hypersensitivity to thermophilic organisms was not identified.

This report and information presented recently by Robertson and colleagues⁹ is the first evidence from Britain of chest radiographic abnormalities consistent with hypersensitivity pneumonitis associated with contamination of an air conditioning system but with no detection of antibodies to thermophilic actinomycetes.

Case report

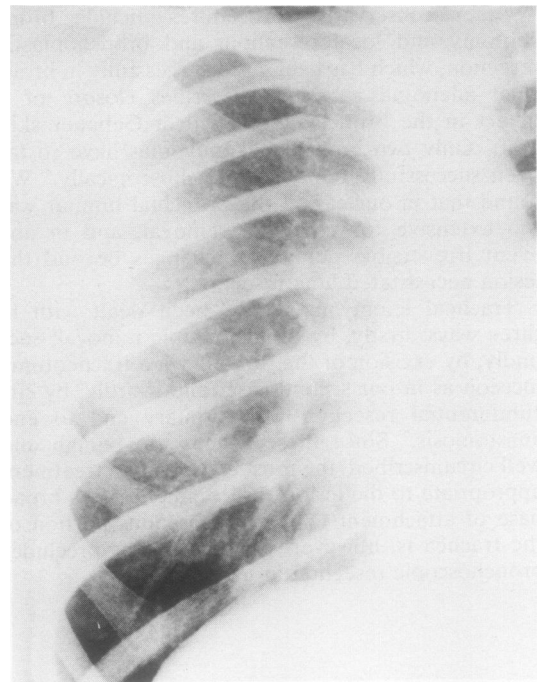
A 29 year old previously fit, non-smoking, caucasian, male electronics engineer presented with a six month history of progressive dyspnoea provoked by mild exertion. Initially this was accompanied by a dry cough but later it became productive of mucopurulent sputum. Two or three times a week he complained of feverishness with muscle, joint, and back ache. On one occasion a temperature of 38.3° was recorded. These symptoms occurred at the end of a working day and settled overnight. His general health was otherwise good but he lost up to 15 kg body weight during the period of this illness. There was no history of atopy or of wheeze. There were no pets in the home and he had no hobbies requiring contact with organic materials. He worked in an air conditioned environment where humidification was achieved by spraying water into the airstream within the humidifier unit from a constantly recirculated closed circuit supply.

Physical examination revealed nothing remarkable apart from fine crackles audible over both lung fields on auscultation. No wheezing was present. There was no cyanosis, no palpable lymphadenopathy, and no clubbing of the fingers. The blood pressure was 115/76 mm Hg and no

abnormality was found on examination of the cardiovascular system, abdomen, or central nervous system.

The chest radiograph at this first visit showed haziness and fine mottling bilaterally, which was most prominent in the mid zones (fig). The vital capacity was found to be reduced at 72% of the predicted normal value; the transfer coefficient was low (table).

After this visit he went on holiday and noted rapid improvement in his symptoms. He returned for the second assessment three weeks later. At this visit his symptoms had resolved and the chest radiograph showed normal appearances. His symptoms recurred on the first day back at work. He was moved to temporary accommodation outside the main factory building and his symptoms regressed



Chest radiographic appearances of the right lung at the first visit. Reticulonodular shadowing was present equally in the two lungs.

Address for reprint requests: K Anderson, Department of Respiratory Medicine, Glasgow Royal Infirmary, Glasgow G31.

Accepted 21 January 1985

Vital capacity (VC), transfer coefficient (Kco), and serum immunoglobulin concentrations

Visit No Days after 1st visit	1 0	2 19	3 26	4 45	5 73	6 136	7 199
VC (% predicted)	72	89	90	102	100	93	97
Kco (mmol min ⁻¹ kPa ⁻¹ l ⁻¹)	1.27	1.43	1.33	1.4	1.4	1.52	1.6
IgA (g/l)	2.7	—	—	—	—	—	—
IgG (g/l)	37.3	23.4	—	—	16.4	18.0	—
IgM (g/l)	1.8	—	—	—	—	—	—
IgG against <i>Naegleria gruberi</i>	3+	2+	—	—	1+	2+	—

Conversion: SI to traditional units—Kco: 1 mmol min⁻¹ kPa⁻¹ l⁻¹ = 0.33.

once more. He received oral prednisolone for eight weeks, starting at the third visit (table).

The haemoglobin concentration was 16.4 g/dl and the white cell count $4.9 \times 10^9/l$. The erythrocyte sedimentation rate was 25 mm in one hour. Serum protein electrophoresis showed a polyclonal increase in gammaglobulin and immunoelectrophoresis showed an appreciable increase in serum IgG (table). RAST tests showed no increase in specific IgE directed against common allergens. Further serological tests showed no antibody to *Micropolyspora faeni* or *Aspergillus fumigatus*. IgG antibody to *Naegleria gruberi* was found in serum obtained at the first visit. Serum was also tested against extracts obtained from humidifier systems associated with previous outbreaks of humidifier fever in the UK (Dr Peter Austwick, Cardiothoracic Institute, London). Positive results were obtained with three extracts (BN151 (3+), BN258 Chester (3+), and BN297 Stockport (3+)) and negative results were obtained with two (Bts No 1 and Aberdeen filter dust). Serial measurements of pulmonary function and serum immunoglobulin concentrations are shown in the table.

Discussion

This case occurred with several others during a typical outbreak of humidifier fever. The circumstantial evidence, clinical observations, and laboratory findings leave no doubt about the diagnosis.

This is the first case associated with radiological abnormalities where the predominant antibody response has been shown to be associated with *N gruberi* and to similar antigens isolated from other outbreaks in the UK. There was no evidence of a reaction to *M faeni* or to other thermophilic organisms of the farmer's lung type as described in outbreaks reported from the United States, where radiological abnormalities were commonly found.

The radiological changes which occurred in this case may reflect a particularly intense immunological reaction in the lung, as suggested by the very high levels of total circulating IgG. It has been suggested that the solubility of the

antigen might explain the lack of radiological change in the UK cases^{10,11} but such changes can apparently occur in humidifier fever even when the main causal agent is soluble antigen rather than the particulate antigenic material associated with thermophilic organisms of the farmer's lung type. Radiological changes presumably reflect the overall intensity of the antigenic load and also the level of the individual's innate immunological responsiveness. They might also indicate additional effects from antigenic material present in the humidifier system that has not so far been identified.

References

- Banaszak EF, Thiede WJ, Fink JH. Hypersensitivity pneumonitis due to contamination of an air conditioner. *N Engl J Med* 1970;**283**:271-6.
- Fink JN, Banaszak EF, Thiede WH, *et al.* Interstitial pneumonitis due to hypersensitivity to an organism contaminating a heating system. *Ann Intern Med* 1971;**74**:80-3.
- Hodges GR, Finke JN, Schlueter DP. Hypersensitivity pneumonitis caused by a contaminated cool-mist vapouriser. *Ann Intern Med* 1974;**80**:501.
- Campbell IA, Cockcroft AE, Edwards JH. Humidifier fever in an operating theatre. *Br Med J* 1979;ii:1036-7.
- Cockcroft AE, Edwards JH, Bevan C, *et al.* An investigation of operating theatre staff exposed to humidifier fever antigens. *Br J Ind Med* 1981;**38**:144-51.
- Edwards JH. Microbial and immunological investigations and remedial action after an outbreak of humidifier fever. *Br J Ind Med* 1980;**37**:55-62.
- Friend JA, Palmer KN, Gaddie J, *et al.* Extrinsic allergic alveolitis and contaminated cooling water in a factory machine. *Lancet* 1977;i:197.
- Pickering CAC, Moore WKS, Lacey J, *et al.* Investigation of a respiratory disease associated with an air conditioning system. *Clin Allergy* 1976;**6**:109-18.
- Robertson AS, Burge PS, Wieland A. Extrinsic allergic alveolitis due to antigens from a humidifier at 15°C. *Thorax* 1985;**40**:229.
- Salvaggio J, Pharuphak P, Stanford R, *et al.* Experimental production of granulomatous pneumonitis. *J Allergy Clin Immunol* 1975;**56**:346-8.
- Medical Research Council. Symposium on humidifier fever. *Thorax* 1977;**32**:653-63.



Radiographic changes in humidifier fever.

K Anderson, C P McSharry and G Boyd

Thorax 1985 40: 312-313

doi: 10.1136/thx.40.4.312

Updated information and services can be found at:
<http://thorax.bmj.com/content/40/4/312.citation>

References

These include:

Article cited in:

<http://thorax.bmj.com/content/40/4/312.citation#related-urls>

Email alerting service

Receive free email alerts when new articles cite this article. Sign up in the box at the top right corner of the online article.

Notes

To request permissions go to:

<http://group.bmj.com/group/rights-licensing/permissions>

To order reprints go to:

<http://journals.bmj.com/cgi/reprintform>

To subscribe to BMJ go to:

<http://group.bmj.com/subscribe/>