Thorax 1982;**37**:540–541

Short reports

Two-dimensional echocardiographic features of Björk-Shiley aortic prosthetic valve dehiscence

R WANG, WT LEE, CK MOK

From the Departments of Medicine and Surgery, University of Hong Kong, Hong Kong

Dehiscence of the valve is a serious complication of prosthetic heart valve replacement. It has grave consequences unless promptly diagnosed and corrected by surgery. We report the case of a symptomless patient with near-complete detachment of the aortic prosthesis, diagnosed by radiography and two-dimensional echocardiography. This was confirmed at surgery and the dehisced prosthetic valve was successfully replaced. To the best of our knowledge, the two-dimensional echocardiographic features of a dehisced Björk-Shiley aortic prosthesis have never been reported.

Case report

A 14-year-old boy was first admitted to Queen Mary Hospital on 8 May 1980 with aortic regurgitation, heart failure, and fever. There were no marfanoid features. The initial diagnosis was infective endocarditis. He was treated for heart failure and antibiotics were given after six blood samples had been taken for culture. The fever persisted and the blood cultures were sterile. In view of the high erythrocyte sedimentation rate, raised antistreptolysin O titre and the presence of first-degree atrioventricular block, rheumatic carditis was diagnosed. The boy was given steroids and responded well.

Five months later he still complained of dyspnoea on exertion and cardiac catheterisation confirmed the presence of very severe aortic regurgitation. Aortic valve replacement with a 23-mm Björk-Shiley prosthesis was performed on 1 October 1980. At operation the ascending aorta appeared normal. The aortic valve was tricuspid. All the cusps were thick and small. There was no evidence of previous infective endocarditis. Histopathological examination of the excised valve cusps showed some accumulation of mucinous ground substance with no inflammatory changes. The pathogenesis of the aortic regurgitation remained obscure. The patient had an uneventful recovery but on 26 May 1981 a soft early diastolic murmur was detected for the first time after surgery. He was completely symptom free, and clinically the paraprosthetic leak was minimal. When he was seen again one month later, peripheral signs of severe aortic regurgitation were evident. He admitted only to a slight decrease in exercise tolerance over the preceding month. His chest radiograph on admission showed that the aortic prosthesis was in a peculiar "end-on" position. Fluoroscopy revealed an excessive cyclic excursion of the sewing ring of the aortic prosthesis. Two-dimensional echocardiographic examinations were performed with a Varian 3000 80° phased-array sector scanner. The parasternal area and apical position were examined as described by Tajik *et al.*[1] The most striking finding was a considerable prolapse of the Björk-Shiley aortic prosthesis into the left ventricular outflow tract. This was seen in all the views taken—the long-axis view, the short-axis view (fig) and the apical four-chamber view. The findings suggested a near-total detachment of the prosthesis. An emergency reoperation was performed on 27 June 1981. The Björk-Shiley aortic prosthesis had almost completely dehisced except for two stitches at the right lateral corner. The tissue on the annulus was oedematous and gelatinous. The prosthesis was removed and the annulus was cleared of the gelatinous material. A new 23-mm Björk-Shiley aortic prosthesis was inserted, with interrupted Teflon pledget-supported sutures. Histological examination of the aortic ring biopsy specimen showed

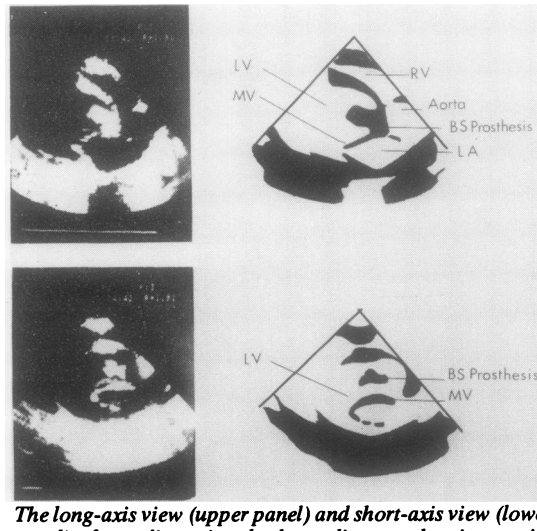

The long-axis view (upper panel) and short-axis view (lower panel) of two-dimensional echocardiogram showing aortic prosthesis prolapsed into the left ventricular outflow tract. RV = right ventricle; LV = left ventricle; MV = mitral valve; LA = left atrium; BS = Björk-Shiley prosthesis.

Address for reprint requests: Dr R Wang, Department of Medicine, University of Hong Kong, Queen Mary Hospital, Hong Kong.

appreciable mucoid degeneration with no inflammatory changes. The patient again had an uneventful recovery. Repeated two-dimensional echocardiographic examination showed a normal position of the aortic prosthetic valve.

Discussion

After insertion of prosthetic heart valves dehiscence of the prosthesis may occur for various reasons. Initially, the breaking and loosening of sutures from the sewing bed is usually limited to a small area. The rate of progression to complete dehiscence and embolisation of the prosthesis is unpredictable. It may be insidious, slow and self-limiting, or acute and rapid. Mild paraprosthetic leak is usually well tolerated, whereas severe leak and complete dehiscence are detrimental. The only way to prevent a catastrophic outcome is a timely operation. Thus it is important to have some means of following and assessing the patients with paraprosthetic leak. Clinical assessment is helpful but not conclusive. Cardiac catheterisation and angiography are valuable, but periodic assessments by these invasive techniques are impracticable and not without risk. Two-dimensional echocardiography has yielded unique information on valvular disease as it delineates the movement of the diseased valve in relation to other intracardiac structures in a real-time fashion. It is the "gold standard" for detection of prolapsed mitral, tricuspid, or aortic valve leaflets.[2] It is also useful in the evaluation of patients with bioprosthetic valves.[3] So far it has not been proved to be of value in the assessment of mechanical prosthetic valves.[4] There is excessive reflection of echoes from the metal cage, occluder, and sewing ring, making identification of individual components impossible. Two-dimensional echocardiography, however, as the present case illustrates, is probably a valuable diagnostic tool in the assessment of a dehisced prosthetic valve, when identification of abnormal movement of the prosthesis as a whole is important. It is superior to fluoroscopy because, apart from showing the excessive excursion of the aortic prosthesis, it delineates the anatomical boundaries traversed by the prosthetic valve. Thus clear visualisation of the aortic prosthesis prolapsing into the left ventricular outflow tract provides an accurate preoperative assessment of the degree of detachment of the prosthesis and guides the timing of reoperation.

References

1 Tajik AJ, Seward JB, Hagler DJ, Mair DD, Lie JT. Two-dimensional real-time ultrasonic imaging of the heart and great vessels. *Mayo Clin Proc* 1978;**53**:271–303.

2 Morganroth J, Jones RH, Chen CC, Naito M. Two-dimensional echocardiography in mitral, aortic and tricuspid valve prolapse. *Am J Cardiol* 1980;**46**:1164–77.

3 Schapira JN, Martin RP, Fowles RE, *et al.* Two-dimensional echocardiographic assessment of patients with bioprosthetic valves. *Am J Cardiol* 1979;**43**:510–9.

4 Kloter MN, Mintz GS, Segal BL, Parry WR. Clinical uses of two-dimensional echocardiography. *Am J Cardiol* 1980;**45**: 1061–82.