Thorax 1982;**37**:492–495

Implications of histologically reported residual tumour on the bronchial margin after resection for bronchial carcinoma

MR LAW, ME HODSON, SC LENNOX

From the Brompton Hospital and Cardiothoracic Institute, London

ABSTRACT A group of 64 cases with histologically reported residual tumour on the bronchial margin after resection for bronchial carcinoma has been examined. Carcinoma in situ of the bronchial mucosa was described in nine cases, invasive carcinoma of the bronchial mucosa in 29, peribronchial malignancy in 18, and lymphatic permeation in eight. Survival with peribronchial malignancy and lymphatic permeation was poor. Nevertheless, the finding of earlier workers that residual mucosal tumour at the margin of the resected bronchus may not adversely affect survival has been confirmed. The reason for the prolonged survival of some patients despite reported tumours of the bronchial stump mucosa may be that such reports are sometimes artefactual, and two possible mechanisms for this are discussed.

The proximal spread of carcinoma of the bronchus has been classified by Cotton.[1] This classification is used to describe residual tumour on the bronchial margin after surgical resection (table 1). The primary tumour may spread proximally either along the bronchial mucosa or along the outer bronchial wall (outside the cartilage) and peribronchial tissues. The outer bronchial wall and peribronchial tissues may also be invaded by nearby metastasised structures (usually a peribronchial lymph node). The primary tumour may also spread proximally by permeation of lymphatic vessels. Tumour may therefore be detected histologically on the mucosa or in the outer bronchial wall and peribronchial tissues of the margin of the resected bronchus, or permeation by tumour cells of submucosal or peribronchial lymphatics in the bronchial margin may be seen.

The effect on the patient's survival of histologically reported tumour at the margin of the resected bronchus, and by implication on the bronchial stump, has been studied by several workers. It has attracted interest because of reports that residual tumour at this site need not adversely affect survival, particularly in patients with mucosal malignancy.[2–5]

Methods

From a series of 1000 patients undergoing lobectomy or pneumonectomy at Brompton Hospital during 1966–75 cases were selected in which tumour on the margin of the resected bronchus was reported histologically. The form of tumour (according to the classification in table 1) was described in every case. Patients with small-cell tumours or with extrapulmonary spread (other than mediastinal lymph node metastasis) were not included. Actuarial survival curves for the three main groups—those with mucosal, peribronchial, and lymphatic malignancy at the bronchial margin—were constructed.

The survival of a group of 90 patients (from the same period) with mediastinal lymph node metastases but no tumour at the bronchial margin and of a group of 296 patients (from a shorter period) with no spread apparent at surgery was also examined, and survival curves were constructed.

Table 1 *Classification of tumours on the margin of the resected bronchus*

A	Inner bronchial wall, including mucosa carcinoma in situ direct extension of primary tumour
B	Outer bronchial wall and peribronchial tissues direct extension of primary tumour invasion from nearby metastasised lymph nodes
C	Lymphatic permeation alone submucosal or peribronchial lymphatics

Address for reprint requests: Dr MR Law, Brompton Hospital, Fulham Road, London SW3 6HP.

Thorax: first published as 10.1136/thx.37.7.492 on 1 July 1982. Downloaded from http://thorax.bmj.com/ on April 16, 2024 by guest. Protected by copyright.

Table 2 *The four types of bronchial margin involvement by tumour, showing histology, mediastinal node metastasis, and survival*

Type of tumour at bronchial margin	*No*	*Histology*		*Patients with mediastinal node metastasis (all died within 2 years)*	*Patients without mediastinal node metastasis*	
		Squamous	*Adenocarcinoma*		*No*	*Survival*
Carcinoma in situ	9	9	0	1	8	6 survived 5 y
Mucosal	29	29	0	3	26	9 survived 5 y
Peribronchial	18	12	6	3	15	None survived 3 y
Lymphatic permeation	8	5	3	4	4	3 died in 2 y, one has survived 10 y

Results

There was a total of 64 cases with histologically reported tumour at the margin of the resected bronchus. Details are summarised in table 2.

Carcinoma-in-situ change in the bronchial mucosa was described in nine patients, of whom six survived five years. The other three died of metastases but did not have local recurrence. Invasive carcinoma of the bronchial mucosa (direct extension of the primary tumour along the inner bronchial wall) was found in 29 patients. Three of these 29 had mediastinal lymph node metastases and died within two years. Of the remaining 26, nine have survived five years. Eighteen cases had peribronchial malignancy. This appeared to be caused by extension of the primary tumour in five cases and by invasion from nearby metastasised structures, almost invariably peribronchial lymph nodes, in the remainder. Only two of the 18 survived two years, and none three years. In eight cases the lymphatics at the margin of the resected bronchus (either submucosal or peribronchial) were seen to be invaded by tumour cells in the absence of any other malignancy of the bronchial margin. Seven of the eight were associated with metastases to hilar or mediastinal lymph nodes. Four of these seven patients died in the first year and three in the second year. One patient who had no apparent lymph node metastasis has, however, survived ten years.

Survival curves for the three groups with mucosal, peribronchial, and lymphatic malignancy of the bronchial margin, with the survival curves for the 296 patients with no spread apparent at surgery and the 90 patients with mediastinal lymph node metastasis but no other spread, are shown in figure 1. The survival of the 26 patients with tumour of the mucosa at the margin of the resected bronchus (if the three patients who also had mediastinal lymph node metastasis are omitted) was much better than the survival of patients with residual tumour in other forms, and almost as good as when no spread had been apparent at surgery. The difference in survival between the two groups with tumour of the mucosa at the bronchial margin and with no apparent spread was not significant; but the survival of those with tumour of the mucosa at the bronchial margin was significantly better than the survival of those with both mediastinal lymph node metastasis and the other forms of malignancy at the bronchial margin (in each case $p < 0.05$ at six months and < 0.01 at 12 months and thereafter with Student's t test, standard errors being calculated for the survival probabilities of each group at six-monthly intervals to five years).

Of the 26 patients with mucosal bronchial margin involvement, only seven subsequently developed a macroscopic recurrence of tumour at the bronchial stump, and none developed a bronchopleural fistula.

Discussion

The effect of tumour at the margin of the resected bronchus has been previously studied.[2-5] Carcinoma in situ is by definition non-invasive, and has been reported not to affect survival[2]; this was confirmed in the present study. The poor survival associated with peribronchial malignancy at the bronchial margin has been seen previously[2 3] and in the present series no patient survived three years.

Permeation by tumour cells of lymphatics at the margin of the resected bronchus is generally associated with metastasis to the hilar and mediastinal nodes to which these lymphatics drain. Survival is poor; 14 patients with lymphatic permeation from the series of Soorae and Stevenson[2] all died within 18 months, and in the present series seven out of eight patients died within two years. One patient without reported lymph node metastasis has, however, survived 10 years, suggesting that tumour cells in the lymphatic vessels of the bronchus are not necessarily deposited as lymph node metastases.

Mucosal malignancy (direct extension of the primary tumour along the inner bronchial wall) is

Thorax: first published as 10.1136/thx.37.7.492 on 1 July 1982. Downloaded from http://thorax.bmj.com/ on April 16, 2024 by guest. Protected by copyright.

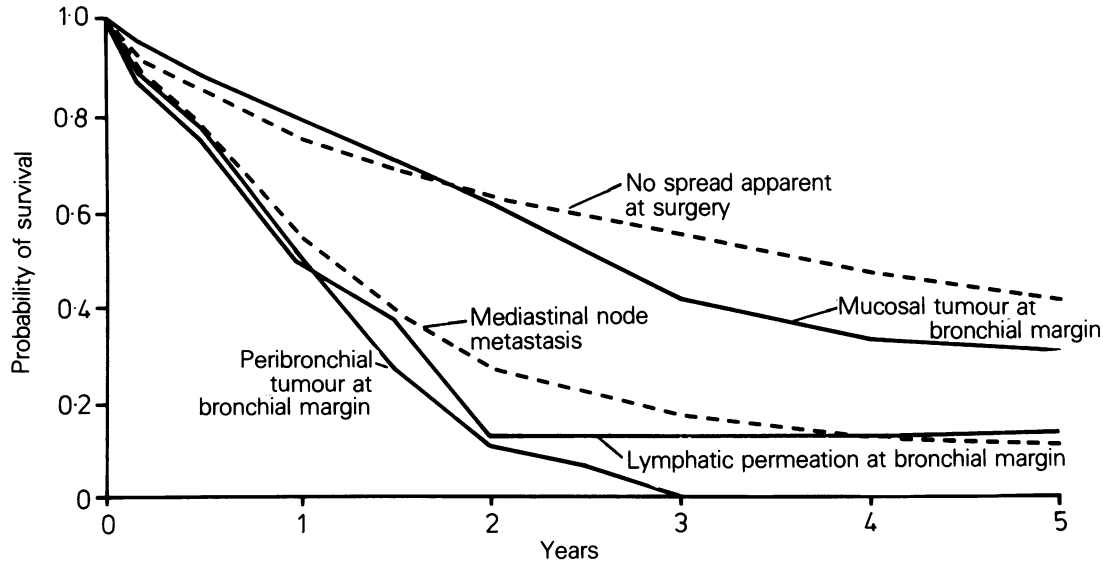

Fig 1 *Actuarial survival curves of 26 patients with mucosal tumour, 18 with peribronchial tumour, and eight with lymphatic tumour of the bronchial margin, with survival curves of 90 patients with mediastinal lymph node metastasis and 296 with no spread apparent at surgery.*

associated with much better survival. Soorae and Stevenson[2] found seven five-year survivors out of 34 cases with mucosal tumour; Shields[3] found eight out of 31. In the present series nine patients out of 26 have survived five years, and we have shown that survival does not significantly differ from that of a group with no extrapulmonary spread of tumour apparent at operation. Subsequent recurrence of tumour on the bronchial stump occurred in only seven cases, and bronchopleural fistula did not occur.

The explanation generally offered for this long survival despite apparent incomplete resection of tumour has been that an immunological reaction might destroy residual microscopic malignancy after the main bulk of the tumour has been removed.[2-4] This seems improbable, however; recorded instances of long survival despite incomplete resection of other tumours are scarce.

Prolonged survival might in some cases be explained by the extension of microscopic tumour to the point of surgical division of the bronchus but not beyond it; or tumour confined to the distal 1–2 mm of the bronchial stump may become necrotic with proliferation of avascular fibrous tissue during healing. An alternative explanation for prolonged survival is that a histological report of tumour at the margin of the resected bronchus may reflect an artefact, and may not imply the presence of tumour on the bronchial stump. Two mechanisms can be proposed whereby a surgical division of the bronchus proximal to the tumour might be reported histologically as having passed through tumour.

The first mechanism depends on the fact that the bronchus is an elastic structure, and when surgically divided tends to retract in a concertina-like fashion and to close over the lumen (fig 2). When the bronchus is divided the distance between the point of division and the tumour in the bronchus is therefore reduced. A ring of bronchus is cut from the bronchial margin and incorporated into paraffin, and sections are taken for histological examination. The distal end of this ring may contain tumour because the resected bronchial margin has been brought closer to the tumour. The distal and proximal ends of the ring of bronchus may be confused, and sections may be taken from the distal end. Tumour of the bronchial margin will be reported from these sections.

The second mechanism derives from the fact that resected lung is kept in formalin for fixation before sections are taken. Shrinkage may occur in formalin, and as well as accentuating the first mechanism the shrinkage may be irregular and produce distortion of the bronchial margin (fig 3). A complete ring of bronchus is required for histological examination for malignancy of the bronchial margin. It is necessary to cut more distally than the original surgical division to obtain a complete ring because of the distor-

Thorax: first published as 10.1136/thx.37.7.492 on 1 July 1982. Downloaded from http://thorax.bmj.com/ on April 16, 2024 by guest. Protected by copyright.

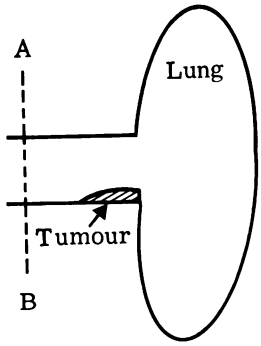

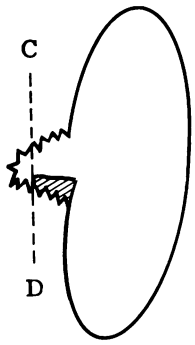

Fig 2 *Diagram of tumour in the bronchus before and after surgical division. The distance between the line of surgical division, A–B, and the tumour becomes reduced by retraction of the bronchial wall. A ring of bronchus cut along the line C–D (from which sections for histological examination are to be taken) contains tumour.*

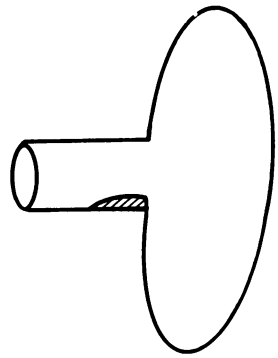

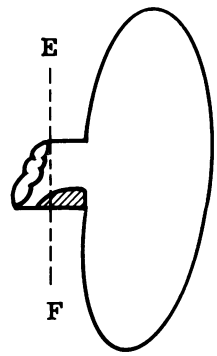

Fig 3 *Diagram of excised lung before and after fixation in formalin. The shrinkage in formalin causes distortion of the bronchial margin. The ring of bronchus (from which sections for histological examination are to be taken) must be cut more distally, along the line E–F, for a complete ring to be obtained, and contains tumour.*

tion of the bronchial margin. Again the distal end of the ring of bronchus may contain tumour.

A histological report describing tumour on the margin of the resected bronchus may really indicate tumour within a centimetre or so of the margin but not necessarily on the actual margin and by implication in the bronchial stump. The survival curve for mucosal malignancy (fig 1) may combine both the unaffected survival of patients who have no residual tumour and the poor survival of those who genuinely have tumour in the stump.

We would like to express our thanks to the physicians and surgeons of the Brompton Hospital whose patients we studied. We would also like to thank Miss S Hockley for secretarial assistance and Miss M Rehahn, Brompton Hospital statistician, for help with the statistical analysis.

References

[1] Cotton RE. The bronchial spread of lung cancer. *Br J Dis Chest* 1959;**53**:142–50.
[2] Soorae AS, Stevenson HM. Survival with residual tumour on the bronchial margin after resection for bronchogenic carcinoma. *J Thorac Cardiovasc Surg* 1979;**78**:175–80.
[3] Shields TW. The fate of patients after incomplete resection of bronchial carcinoma. *Surg Gynecol Obstet* 1974;**139**:569–72.
[4] Jeffery RM. Tumour remaining in the bronchial stump following resection. *Ann R Coll Surg Engl* 1972;**51**:55–9.
[5] Hughes RK, Tildon TT. Prognosis of residual invasive cancer at the margin of bronchial resection. *Ann Thorac Surg* 1966;**2**:102–5.

Thorax: first published as 10.1136/thx.37.7.492 on 1 July 1982. Downloaded from http://thorax.bmj.com/ on April 16, 2024 by guest. Protected by copyright.