

Acquired hypertrichosis lanuginosa and carcinoma of the bronchus

C D SHEE AND V A L GRAHAM

From the Department of Medicine, St Thomas' Hospital, London

Hypertrichosis lanuginosa is a rare entity characterised by an excess growth of fine lanugo hair on the hair-bearing surfaces of the body. The condition is usually congenital but acquired hypertrichosis lanuginosa may arise in association with neoplasia as in the patient described.

Case report

A 57-year-old man presented with a four-month history of cough, weight loss, and profuse growth of fine hair. He was a cigarette smoker with a history of Raynaud's phenomenon for 12 years and diarrhoea for one year. His only drug treatment had been diphenoxylate for the severe diarrhoea. On examination there was a growth of downy hair up to 5 cm long which covered the patient's entire face and body with the exception of his palms and soles (fig). There was slight gynecomastia and sclerodactyly.

Chest radiography showed a mass in the right lower lobe which, after needle aspiration biopsy, was shown to be the result of a well-differentiated adenocarcinoma. Barium examination showed a tubular, rather featureless small bowel. Jejunal biopsy and malabsorption tests were normal. The ESR was 78 mm in one hour. The following investigations were normal: oestrogens, 17-oxosteroids, 17-oxogenic steroids, plasma cortisol and ACTH, prolactin, gastrin, 5-hydroxyindole acetic acid (5 HIAA), vasoactive intestinal peptide (VIP), and porphyrins. Plasma testosterone was low at 1.5 and 1.8 $\mu\text{g/l}$ (normal range 3-8). Luteinising hormone level (LH) was 200 units/l (10-50) and follicle-stimulating hormone (FSH) was also raised to 12.3 units/l (0.5-2.5).

The patient received a palliative course of radiotherapy with no improvement. He died at home one month after discharge. Unfortunately a necropsy was not performed.

Discussion

The development of a profuse growth of lanugo hair in an adult is rare and may be associated with underlying carcinoma.¹ Only four previous cases have been reported with carcinoma of the bronchus (table).²⁻⁵ Hirsutism, particularly prominent on the face and hands, caused our patient extreme embarrassment.

Diarrhoea, an uncommon non-metastatic complication of lung cancer, was present in this patient,

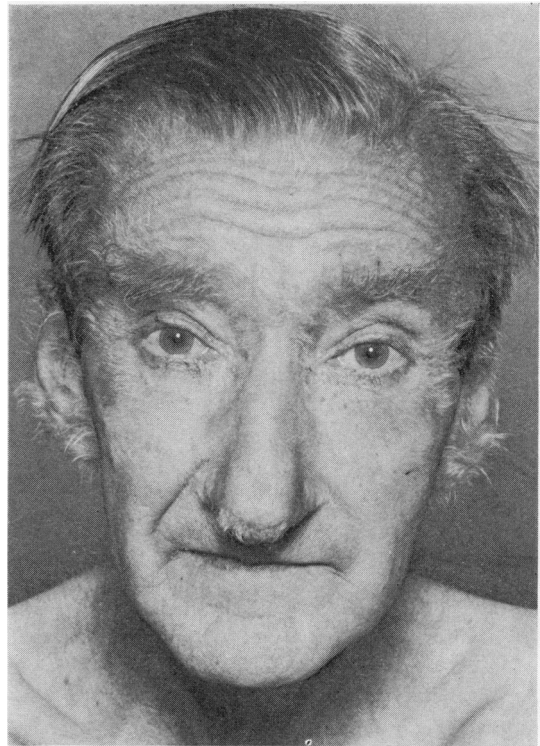


Figure Photograph showing fine lanugo hair on the forehead and ears. The lower face had recently been shaved.

and it was described in some of the cases reviewed by Wadskov.¹ In 1950 Le Marquand and Bohn⁶ reported a patient with hypertrichosis lanuginosa, without diarrhoea, who, in retrospect almost certainly suffered from Zollinger-Ellison syndrome. Hypergastrinaemia may be associated with diarrhoea; our patient's gastrin, VIP and 5 HIAA levels were normal. In view of

Table Reported cases of acquired hypertrichosis lanuginosa with bronchial carcinoma

Reference	Age (yr)	Sex	Histology
2	69	M	Undifferentiated
3	44	M	Small cell
4	43	F	Undifferentiated
5	63	M	Undifferentiated
Present case	57	M	Adenocarcinoma

Address for reprint requests: Dr CD Shee, Department of Medicine, St Thomas' Hospital, London SE1 7EH.

the sclerodactyly, barium findings, and history of Raynaud's phenomenon, diarrhoea in this patient may have been caused by mild scleroderma with bowel involvement.

Review of all published cases of acquired hypertrichosis lanuginosa shows no consistent endocrine picture and, when measured, the sex hormone levels have usually been normal. This patient may have been producing a substance that cross-reacted with the LH and FSH assays but failed to stimulate testosterone production. The cause of the syndrome is unknown but it is possible that, in this case, the tumour produced a trophic substance normally present in foetal life, thereby stimulating production of lanugo hair.

We would like to thank Dr NF Jones and Dr DJ McBrien for permission to report this case.

References

- 1 Wadskov S, Bro-Jorgensen A, Sondergaard J. Acquired hypertrichosis lanuginosa. *Arch Dermatol* 1976; **112**:1442-4.
- 2 Fretzin DF. Malignant down. *Arch Dermatol*. 1967; **95**:294-7.
- 3 Hensley GT, Glynn KP. Hypertrichosis lanuginosa as a sign of internal malignancy. *Cancer* 1969; **24**:1051-6.
- 4 Rzempoluch E, Szczurek Z, Osiecki Z. Hypertrichosis lanuginosa acquisita in the course of bronchial carcinoma. *Przeg Derm* 1976; **63**:199-203.
- 5 Anderson G. *Paramalignant syndromes in lung cancer*. London: Heinemann Medical Books, 1973.
- 6 Le Marquand HS, Bohn GL. Recurrent peptic ulcers with general hypertrichosis. *Proc R Soc Med* 1950; **44**:155-7.



Acquired hypertrichosis lanuginosa and carcinoma of the bronchus.

C D Shee and V A Graham

Thorax 1981 36: 153-154
doi: 10.1136/thx.36.2.153

Updated information and services can be found at:

<http://thorax.bmj.com/content/36/2/153.citation>

References

These include:

Article cited in:

<http://thorax.bmj.com/content/36/2/153.citation#related-urls>

Email alerting service

Receive free email alerts when new articles cite this article. Sign up in the box at the top right corner of the online article.

Notes

To request permissions go to:

<http://group.bmj.com/group/rights-licensing/permissions>

To order reprints go to:

<http://journals.bmj.com/cgi/reprintform>

To subscribe to BMJ go to:

<http://group.bmj.com/subscribe/>