

Serial  $^{67}\text{Ga}$  lung scanning in pulmonary eosinophilic granuloma\*

SHAHROKH JAVAHERI,† BARRY W LEVINE, AND KENNETH A McKUSICK

From Boston City Hospital and Massachusetts General Hospital, Boston, MA, USA

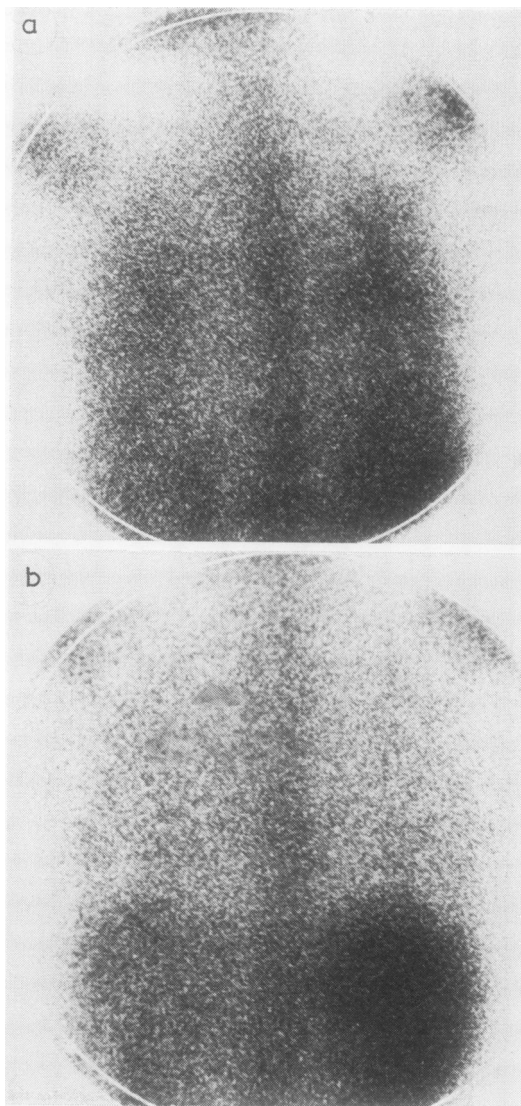
Chest radiographs and pulmonary function tests are used as non-invasive techniques for the clinical management and guide to treatment in patients with diffuse interstitial pulmonary disease. The serial use of these tests may not give a true indication of the pathological activity of the disease process in the lung. Pulmonary function tests often remain abnormal despite inactivity of the pathological reaction, and may be insensitive to subtle changes in activity that may occur in progressive pulmonary fibrosis (Niden *et al*, 1976). Considering the associated morbidity and mortality of repeated lung biopsy, a sensitive non-invasive technique that could be used serially to detect pathological activity may prove important for clinical management of these patients.

Gallium-67 ( $^{67}\text{Ga}$ ) lung scanning has been used in the detection and progression of pulmonary malignancies, infection, sarcoidosis (McKusick *et al*, 1973), and idiopathic pulmonary fibrosis (Line *et al*, 1976). The definitive value of serial  $^{67}\text{Ga}$  lung scanning for detecting activity in interstitial lung disease remains to be established. This is the first reported case of pulmonary eosinophilic granuloma in which serial  $^{67}\text{Ga}$  lung scans, simultaneous chest radiographs, and pulmonary function tests were obtained over a period of eight months. These serial studies support the concept that uptake of  $^{67}\text{Ga}$  by pulmonary parenchyma parallels the active inflammatory process.

## Case report

A 27-year-old woman was in excellent health until she developed a non-productive cough and exertional dyspnoea seven months before admission. Her chest radiograph was normal. Her cough and shortness of breath continued, and repeat chest radiographs showed bilateral basal streaky infiltrates. An open lung biopsy was performed, and the diagnosis of eosinophilic granuloma was established. A  $^{67}\text{Ga}$  lung scan (fig a), performed 48 hours after intravenous injection of 5 mCi of  $^{67}\text{Ga}$  citrate, showed diffuse increased activity in both lungs slightly greater on the right, without concentration in parahilar regions.

She was treated with prednisone, 60 mg daily. A  $^{67}\text{Ga}$  lung scan obtained at one month was normal (fig b), after which the steroid dose was gradually reduced. The repeat  $^{67}\text{Ga}$  lung scan remained normal eight months after treatment. Initial pulmonary function



$^{67}\text{Ga}$  scan. Posterior view. (a) Diffuse uptake of  $^{67}\text{Ga}$ , suggesting active inflammatory process. (b) Normal  $^{67}\text{Ga}$  scan of lungs one month after starting treatment.

\*Supported by NIH Training Grant HL05767.

†Supported in part by a grant from the John A Hartford Foundation.

tests (table) showed a moderate restrictive defect manifested by reductions in lung volumes but normal maximum peak expiratory flow rate and  $\text{FEV}_1/\text{VC}$ . Although lung volumes improved gradually, the vital capacity and pulmonary gas exchange, as manifested by alveolar-arterial  $\text{PO}_2$  difference and diffusing capacity for carbon monoxide remained abnormal. Serial chest radiographs showed persistence of the reticulonodular pattern with minimal improvement during the eight months of follow-up.

## Discussion

$^{67}\text{Ga}$  has been shown to concentrate in cellular elements affected in active inflammatory processes. Since normal lung has almost no inflammatory cells in the interstitium or alveolus, the uptake of  $^{67}\text{Ga}$  by lungs is minimal—less than 3% of the dose administered. An observable uptake of  $^{67}\text{Ga}$  by the lung is abnormal. The intracellular localisation of  $^{67}\text{Ga}$  has been suggested to be in the lysosomal compartment of the inflammatory cellular elements, and Hoffer *et al* (1977) have presented evidence that lactoferrin may be a cellular protein to which  $^{67}\text{Ga}$  binds. Pathologically, the “early” lesion of eosinophilic granuloma is characterised by a granulomatous process containing predominantly large, irregularly-shaped histiocytes. Eosinophils, lymphocytes, plasma cells, and polymorphonuclear leucocytes are also present in the inflammatory granulomatous process (Spencer, 1977).

The initial chest radiograph, pulmonary function tests, and  $^{67}\text{Ga}$  lung scan on our patient, when the disease was active as shown on biopsy, were all abnormal. These abnormalities were probably all secondary to an active eosinophilic granulomatous process. As eosinophilic granuloma progresses and the lesions age, increasing amounts of collagen fibre are formed, and the granulomatous process is replaced by a mass of hyaline fibrous tissue (Spencer, 1977). At that stage, in the absence of active inflammation,  $^{67}\text{Ga}$  uptake by the lung may return to normal, while pulmonary function tests and chest radiographs may indicate restrictive disease. The initial positive  $^{67}\text{Ga}$  lung scan indicated an active inflammatory process and the subsequent negative scans suggested an ab-

sence of the eosinophilic granulomatous activity. This is in accord with other studies reported in patients with interstitial lung diseases other than eosinophilic granuloma (McKusick *et al*, 1973; Line *et al*, 1976; Niden *et al*, 1976). Line *et al* (1976) showed that  $^{67}\text{Ga}$  lung activity correlated with the recovery of active inflammatory cells by bronchoalveolar lavage in patients with idiopathic pulmonary fibrosis.  $^{67}\text{Ga}$  lung scans in sarcoidosis (McKusick *et al*, 1973; Niden *et al*, 1976) performed before and after institution of corticosteroids also support the concept of the direct relation of pulmonary  $^{67}\text{Ga}$  activity to the level of granulomatous activity. In serial tests a reduced uptake would suggest decreased activity of the disease process.

Serial  $^{67}\text{Ga}$  lung scans may be useful when steroids are used as therapeutic agents. When the  $^{67}\text{Ga}$  lung scan becomes normal, suggesting that the pathological activity has subsided, the steroid dose may be reduced. A repeated normal  $^{67}\text{Ga}$  lung scan assures the inactivity of the disease process.

## References

- Hoffer, P B, Huberty, J, and Khayam-Bashi, H (1977). The association of Ga-67 and lactoferrin. *Journal of Nuclear Medicine*, **18**, 713–717.
- Line, B R, Fulmer, J D, Jones, A E, Reynolds, H Y, Roberts, W C, and Crystal, R G (1976).  $^{67}\text{Ga}$  scanning in idiopathic pulmonary fibrosis: Correlation with histopathology and bronchoalveolar lavage. *American Review of Respiratory Disease*, **113**, no 4 pt 2, 224.
- McKusick, K A, Soin, S J, Ghiladi, A, and Wagner, H N (1973).  $^{67}\text{Ga}$  accumulation in pulmonary sarcoidosis. *Journal of the American Medical Association*, **223**, 688.
- Niden, A H, Mishkin, F S, and Khurana, M M L (1976).  $^{67}\text{Ga}$  citrate lung scans in interstitial lung disease. *Chest*, **69**, 266–268.
- Spencer, H (1977). *Pathology of the Lung*, 3rd edn. Saunders, Philadelphia.

Requests for reprints to Sh Javaheri, MD, FGH 3, Boston City Hospital, 818 Harrison Avenue, Boston MA 02118.

## Pulmonary function tests

Date	$\text{FEV}_1$	VC (l)	TLC (l)	Room air		Room air	100% $\text{O}_2$	DLCO <sub>ss</sub>
				$\text{PaO}_2$ (mmHg)	$\text{Paco}_2$	$\text{PAO}_2 - \text{PaO}_2$ (mmHg)		
*5/77	1.4	1.7 (52)	2.9 (68)	86	35	24	179	8 (42)
8/77	1.6	2.1 (64)	3.8 (90)	73	35	34	78	—
10/77	2	2.3 (70)	3.9 (93)	78	28	23	91	—
1/78	1.9	2.3 (70)	3.8 (90)	89	35	27	73	8 (42)

\*Before starting treatment.

TLC = Total lung capacity; VC = Vital capacity;  $\text{FEV}_1$  = Forced expiratory volume in one second.

Values in parentheses represent % predicted.

DLCO<sub>ss</sub> = Steady state diffusing capacity for carbon monoxide (ml/min/mmHg). Values in parentheses represent % predicted.

$\text{PO}_2$ ,  $\text{CO}_2$  = Partial pressure of oxygen or carbon dioxide in blood or alveolar air (A) in mmHg.