Thorax, 1977, **32**, 497–500

Squamous-cell carcinoma of the pleura

J. R. RÜTTNER AND S. HEINZL

From the Institute of Pathology, University Hospital of Zürich, Switzerland

Rüttner, J. R., and Heinzl, S. (1977). *Thorax*, **32,** 497–500. **Squamous-cell carcinoma of the pleura.** There are few reports of primary malignant tumours of the pleura other than mesothelioma. Reports of squamous-cell carcinoma of the pleura are especially rare. Epidermoid carcinoma of the pleura may occur in connection with persistent empyema drained by a pleurocutaneous fistula or long-standing extrapleural pneumothorax without fistula.

In a review of carcinomas developing after chronic drainage of cutaneous sinuses and fistulae, McAnally and Dockerty (1949) reported a case of chronic empyema treated with thoracotomy followed by cutaneous fistula and carcinoma 27 years later. Bruce *et al.* (1960) reported five patients with pulmonary tuberculosis in whom epidermoid carcinoma of the pleura followed extrapleural pneumothorax without fistula. Carcinoma occurred five to 10 years after the initial pneumothorax. All but one of these patients died after pleurectomy (Dahlström, 1973).

In 1960, Peabody observed a case of carcinoma in a bronchopleurocutaneous fistula 12 years after pneumonectomy for bronchiectasis.

A case of squamous-cell carcinoma in a bronchopleurocutaneous fistula appearing 26 years after surgical drainage of an empyema was described by Deaton (1962). Ender (1966) described a highly differentiated carcinoma of the pleura occurring in a 43-year-old woman 17 years after extrapleural pneumothorax.

A 43 years' history of purulent pleural drainage after pneumonia preceded a further case of carcinoma mentioned by Cattaneo and Klassen (1973).

Case reports

CASE 1: EPIDERMOID CARCINOMA IN EMPYEMA CAVITY WITH PLEUROCUTANEOUS FISTULA

This 49-year-old Italian man was first seen in 1941 with tuberculous pleurisy and right-sided empyema. The empyema was surgically drained and followed by massive pleural fibrosis. In 1944, a thoracoplasty with decortication was performed because of persistent empyema and pleurocutaneous fistula. In 1962, tuberculous peritonitis occurred and was successfully treated.

On 29 August 1970, the patient was transferred from Italy to the Department of Surgery, University Hospital of Zürich, for surgical removal of the empyema and the cutaneous fistula. On 1 September decortication of the right lung was performed.

Histopathology

Fibrosis and focal calcification were seen in the pleural tissue. The fistulous tract was lined by hyperplastic squamous epithelium with focal papillary hyperplasia. No definite malignant changes were observed.

Six months later, in March 1971, the pleurocutaneous fistula recurred. The cutaneous fistula, with adjacent parts of the chest wall, and the empyema cavity were surgically removed.

The fibrous wall of the empyema showed nonspecific inflammatory changes and foreign-body granulomata around cholesterol crystals. The wall was lined by hyperplastic keratinising squamous epithelium. The latter showed gradual transition into solid cords of malignant cells which invaded the skeletal musculature of the chest wall. The epidermoid neoplasia (Fig. 1) could be traced back to the fistulous tract.

A thorough examination failed to detect any further primary epidermoid carcinoma, especially a peripheral pulmonary cancer. He was followed up for three years after the operation and during this time there was no relapse.

CASE 2: EPIDERMOID CARCINOMA FOLLOWING EXTRAPLEURAL PNEUMOTHORAX, WITHOUT FISTULA

A 43-year-old white Italian woman presented with

Thorax: first published as 10.1136/thx.32.4.497 on 1 August 1977. Downloaded from http://thorax.bmj.com/ on April 18, 2024 by guest. Protected by copyright.

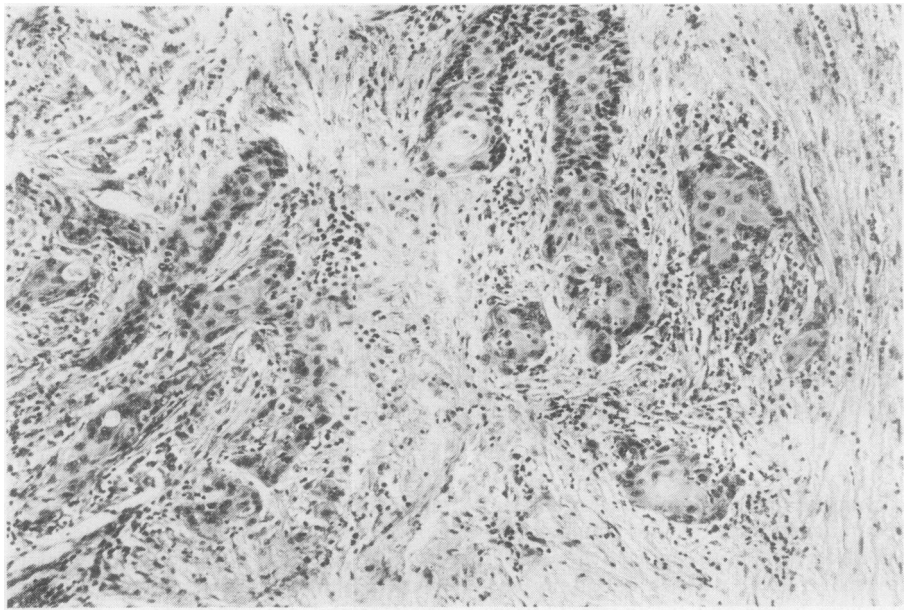

Fig. 1 *Case 1. Epidermoid carcinoma invading the fibrous wall of the empyema cavity. Haematoxylin and eosin stain, ×100.*

left tuberculous pleurisy in 1947. At the age of 22, cavernous pulmonary tuberculosis with haemoptysis had occurred; this was treated in an Italian provincial hospital with extrapleural pneumothorax which was repeatedly refilled. Subsequently she developed a persistent cough and airways obstruction due to chronic bronchitis. The patient was transferred from Italy to the Department of Surgery, University Hospital of Zürich on 22 November 1972. Physical examination of the chest revealed dullness to percussion over the left lung. The chest radiograph showed extensive pleural thickening on the left side (Fig. 2). Clinically, there were no signs of active tuberculosis. On 24 November a decortication of the left lung which was coated by a mass of fibrous tissue was performed. The extrapleural space contained purulent fluid.

Histopathology

On one side the excised fibrous tissue was covered by stratified, well-differentiated squamous epithelium showing areas of papillary architecture. Focally, the epithelium was undifferentiated and infiltrating the fibrous tissue with proliferating cords. These were composed of pleomorphic, partially keratinising squamous cells with atypical mitoses and many pyknotic nuclei. Some inflammatory foci of non-specific character were present, but no tuberculous changes could be detected (Fig. 3).

Postoperatively, no evidence of another primary neoplasm was found. On 15 December 1972, the patient returned in good health to Italy. Since then no recurrence has been observed.

Discussion

The occurrence of carcinoma in chronic inflammatory sinuses, pilonidal sinuses, and fistulae is well known although the true cause of this type of cancer is not yet understood (McAnally and Dockerty, 1949; Bruce *et al.*, 1960; Bauer, 1963; Brown and Rivera, 1968; Horn and Templeton, 1971). The malignant transformation of squamous-cell epithelium of a cutaneous fistula into epidermoid carcinoma does not differ basically from the development of carcinoma from non-neoplastic epithelium in other locations. A common feature of these neoplasms is the long latent period between the appearance of a fistula and the growth of a malignant tumour. For epidermoid carcinomas in empyema cavities with pleurocutaneous fistulae, a latent period of 11–47 years has been reported. Provided an early diagnosis is made, surgical treatment may prove successful.

Epidermoid carcinoma of the pleura occurring after extrapleural pneumothorax without fistula,

Thorax: first published as 10.1136/thx.32.4.497 on 1 August 1977. Downloaded from http://thorax.bmj.com/ on April 18, 2024 by guest. Protected by copyright.

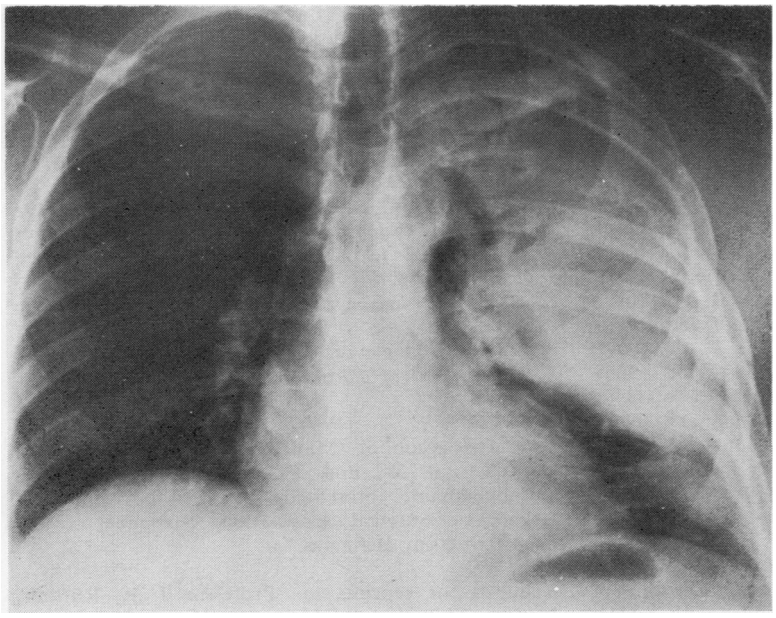

Fig. 2. *Case 2. Chest radiograph showing massive pleural thickening over the left lung.*

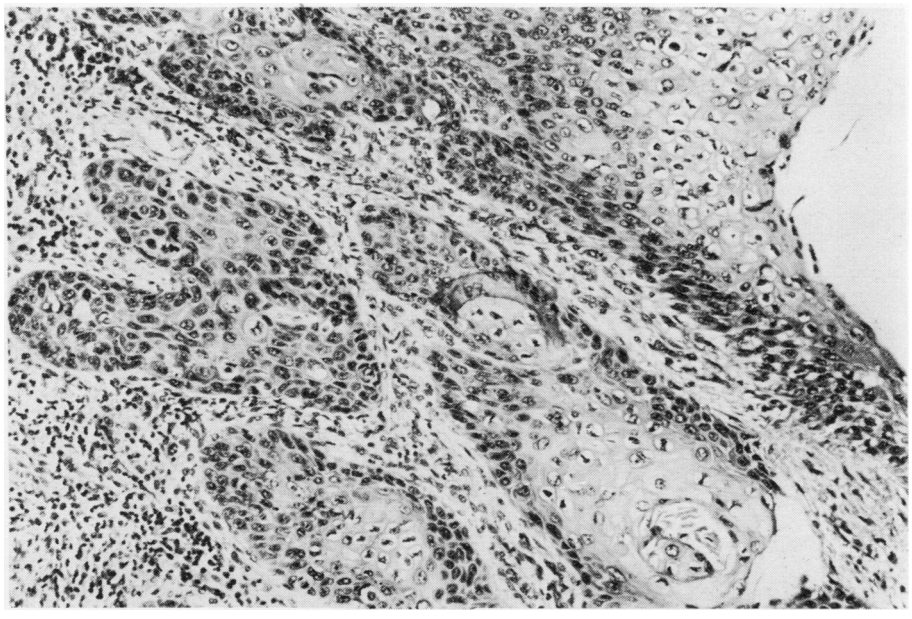

Fig. 3 *Case 2. Keratinising epidermoid carcinoma invading the fibrous wall of the extrapleural pneumothorax. H and E ×100.*

as seen in our case 2, is very rare. Today extrapleural pneumothorax is rarely performed since chemotherapy and/or surgery have successfully replaced this kind of treatment for lung tuberculosis. In cases without cutaneous fistulae it is debatable whether the neoplasm originates from metaplasia of pleural mesothelial cells or whether it is due to displacement of epidermal fragments after open thoracotomy or repeated needle punctures for refilling the pneumothorax.

Thorax: first published as 10.1136/thx.32.4.497 on 1 August 1977. Downloaded from http://thorax.bmj.com/ on April 18, 2024 by guest. Protected by copyright.

The findings of Ender (1966) and Merlier and Orcel (1956) strongly support the suggestion that carcinomatous transformation is preceded by metaplasia of pleural mesothelial cells in a chronically irritated and inflamed pleura.

References

Bauer, K. H. (1963). *Das Krebsproblem*, 2nd edition. Springer Verlag, Heidelberg.

Brown, H. W., and Rivera, J. (1968). Epidermoid carcinoma arising in a pilonidal sinus. Report of a case and review of the literature. *International Surgery*, **50,** 435–440.

Bruce, T., Dahlström, G., and Uggla, L. G. (1960). Squamous epithelial cancer of the pleura following extrapleural pneumothorax for pulmonary tuberculosis. *Acta Tuberculosea Scandinavica*, **38,** 261–266.

Cattaneo, S. M., and Klassen, K. P. (1973). Carcinoma of the chest wall complicating chronically draining empyema. *Chest*, **64,** 673–674.

Dahlström, G. (1973). Personal communication.

Deaton, W. R., Jr. (1962). Carcinoma arising in a chronic empyema cavity. Case report with review of the literature. *Diseases of the Chest*, **42,** 563–566.

Ender, A. (1966). Ein Beitrag zum primären Pflasterzellkarzinom der Pleura nach extrapleuralem Pneumothorax. Juris-Verlag. Thesis University of Zürich.

Horn, C. V., and Templeton, A. C. (1971). Carcinoma developing in a drainage sinus of chronic osteomyelitis of the humerus. *British Journal of Surgery*, **58,** 399–400.

McAnally, A. K., and Dockerty, M. B. (1949). Carcinoma developing in chronic draining cutaneous sinuses and fistulas. *Surgery, Gynecology and Obstetrics*, **88,** 87–96.

Merlier, M., and Orcel, L. (1956). Pachypleurite chronique avec revêtement épithélial des deux feillets de la plèvre. *La Semaine des Hôpitaux de Paris. Archives d'Anatomie Pathologique*, **32,** 127–128.

Peabody, J. W., Jr. (1960). Quoted by W. R. Deaton, Jr. Discussion of 'Malignant lesions of the chest wall' by J. W. Polk, A. H. Bailey, and W. W. Buckingham, presented before the Southern Thoracic Surgical Association, November 17–19, 1960, Nassau, Bahamas.

Requests for reprints to: Professor J. R. Rüttner, Institute of Pathology, University Hospital of Zürich, Switzerland.

Thorax: first published as 10.1136/thx.32.4.497 on 1 August 1977. Downloaded from http://thorax.bmj.com/ on April 18, 2024 by guest. Protected by copyright.