Thorax (1975), **30**, 278.

Intramural diverticulosis of the oesophagus

R. DARRAGH MONTGOMERY, KARL MENDL, and S. F. STEPHENSON

East Birmingham Hospital, Birmingham, B9 5ST

Montgomery, R. D., Mendl, K., and Stephenson, S. F. (1975). *Thorax,* **30,** 278–284. **Intramural diverticulosis of the oesophagus.** Four cases of intramural diverticulosis of the oesophagus are described, and the findings are reviewed in 12 previously reported cases. Evidence is presented that this condition is a true pulsion diverticulosis due to deranged motor activity and raised intraluminal pressure. It may occur in cases of diffuse oesophageal spasm, or it may follow inflammation, stricture or surgery. The course is benign, complications being those of the underlying disorder.

Intramural diverticulosis of the oesophagus was first described by Mendl, McKay, and Tanner in 1960. A total of 11 single case reports has since been published (Hodes, Atkins, and Hodes, 1966; Culver and Chaudhari, 1967; Troupin, 1968; Zatzkin, Green, and LaVine, 1968; Creely and Trail, 1970; Weller and Lutzker, 1971; Cramer, 1972; Lane, 1972; Weller, 1972; Mendl, Montgomery, and Stephenson, 1973; Wightman and Wright, 1974). We now present the findings in four further cases and review the published data with particular reference to the clinical features and pathogenesis.

CASE REPORTS

CASE 1 A man aged 41 had a right radical pneumonectomy in July 1965 for extensive unilateral lung disease which was thought to be carcinoma. Histology showed that this was an inflammatory lesion of the allergic granuloma—Wegener's granulomatosis group.

There was no recurrence, but five months later he had a sudden severe episode of oesophageal blockage lasting for about two hours. In June 1967 this recurred and persisted for five days. On admission he had substernal discomfort and complete dysphagia.

A barium swallow showed numerous intramural diverticula, about 2 mm in depth and of pinhead size, involving the middle third of the oesophagus, mainly on its left anterior wall (Fig. 1). During fluoroscopy, long-lasting tonic contractions occurred repeatedly in a segment about 7 cm long in the lower oesophagus; a food particle could be seen lodged in the upper part of this segment. The mucosal folds were thickened and indistinct, suggesting lower oesophagitis.

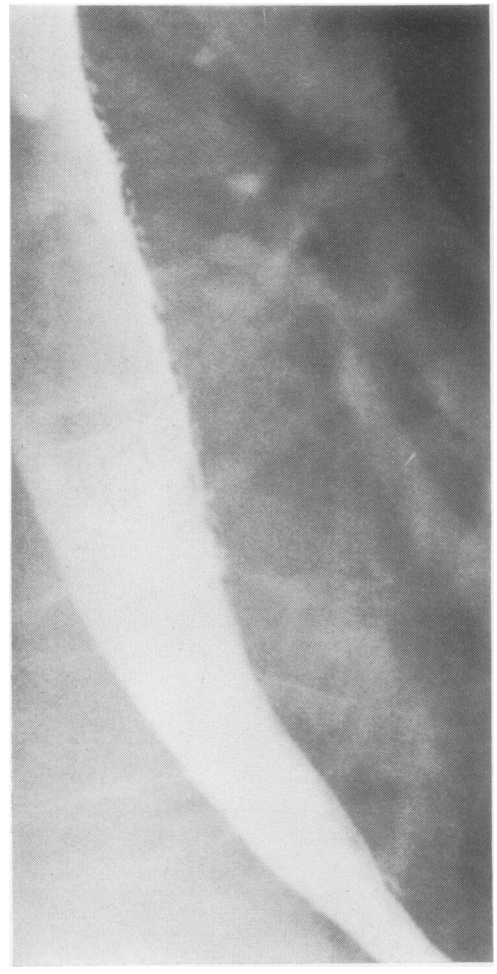

FIG. 1. *Case* 1. *Barium study of mid-oesophagus showing multiple intramural diverticula.*

Thorax: first published as 10.1136/thx.30.3.278 on 1 June 1975. Downloaded from http://thorax.bmj.com/ on April 19, 2024 by guest. Protected by copyright.

On oesophagoscopy the mucosa was mildly congested. There was some distortion due to the previous pneumonectomy. There was a smooth narrowing of the lower oesophagus which was readily dilated with bougies.

A biopsy revealed mucosa with underlying fibrous tissue, muscle fibres, and focal infiltration of lymphocytes. The epithelium was hypertrophied and was thrown into folds, which sent down processes into the underlying fibrous tissue. Some of these processes revealed a central lumen which in one case was filled with desquamated epithelial cells (Fig. 2). These appeared to be the mouths of small diverticula. No mucous glands were present in the specimen.

Other biopsies showed epithelial hyperplasia and mild chronic inflammatory cell infiltration.

Following bouginage swallowing returned to normal. During five years' follow-up there was no significant dysphagia nor any recurrence of lung disease, although the patient had spells of depression and cancer phobia with anorexia and vague chest pains. In spite of the absence of relevant symptoms, repeat radiographs in 1968 showed no improvement in the appearance of intramural diverticulosis and diffuse lower oesophageal spasm.

CASE 2 A man aged 65 was in long-stay care due to paraplegia dating from early childhood. He had been bedridden since 1967. In January 1970 he began to complain of substernal pain on swallowing. A barium study showed multiple intramural diverticula confined to the lower 4 cm of the oesophagus (Fig. 3). There was sustained spasm of this segment. There was also a sliding hiatus hernia and a deformed duodenal cap. Endoscopy showed intense inflammation of the lower oesophagus, but the lumen was widely patent.

During the next three years the dysphagia fluctuated, but the main complaint was of postprandial pain, sometimes radiating to the interscapular area. His forced recumbency was thought to be an aggravating factor. Treatment was based on weight reduction and antacids. A barium

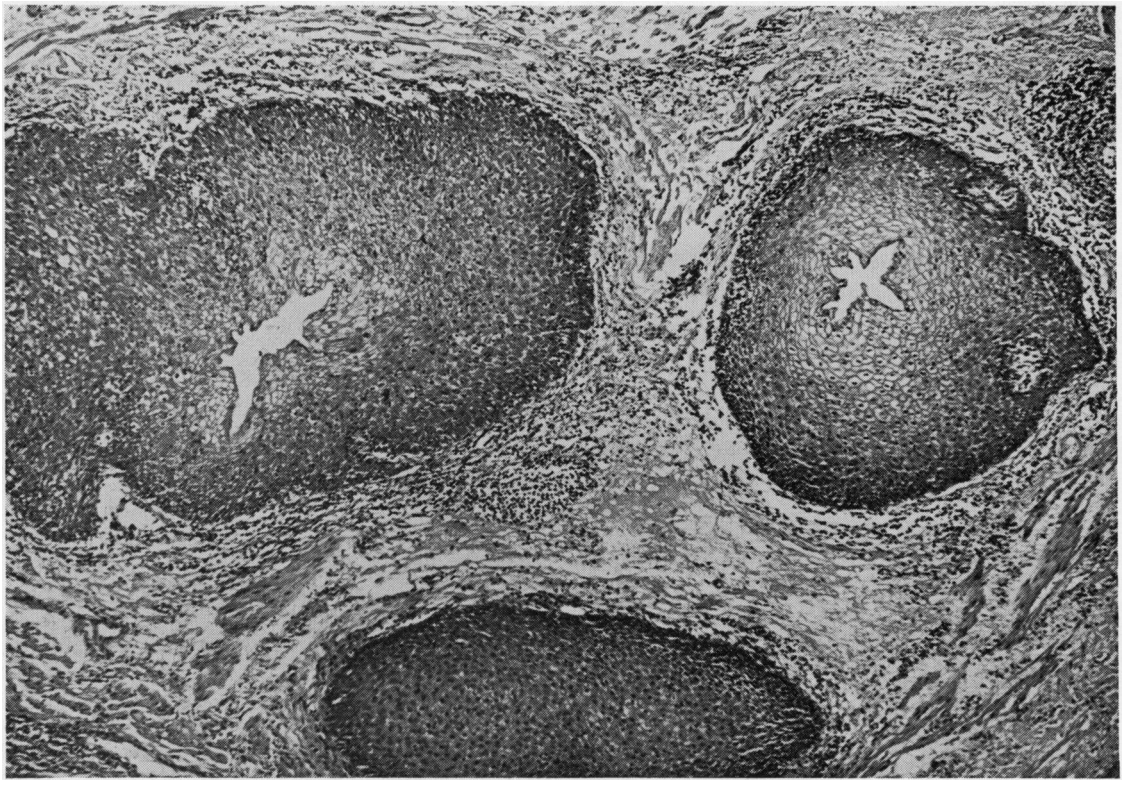

FIG. 2. *Case* 1. *Oesophageal biopsy showing invaginations of hypertrophied mucosa at the mouths of diverticula. Haematoxylin and eosin* ×60.

Thorax: first published as 10.1136/thx.30.3.278 on 1 June 1975. Downloaded from http://thorax.bmj.com/ on April 19, 2024 by guest. Protected by copyright.

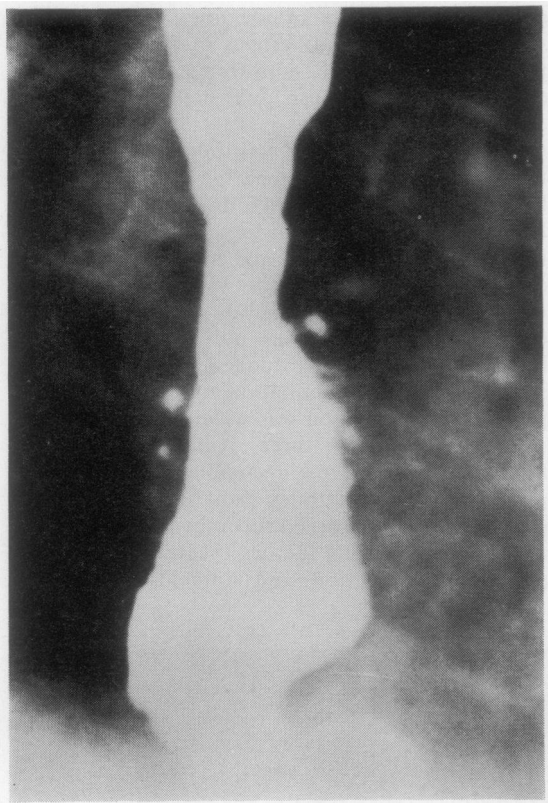

FIG. 3. *Case 2. Barium study. Multiple diverticula in the lower oesophagus above a small hiatus hernia.*

swallow was repeated on two occasions and showed no change.

CASE 3 A 70-year-old woman was admitted to a long-stay geriatric ward in September 1971 with confusion and incontinence due to cerebrovascular disease. One year later she complained of discomfort in the throat lasting about two weeks. She was reluctant to swallow and began to lose weight.

A barium swallow showed a narrowed segment of upper oesophagus, 2 cm in length, at the level of the second thoracic vertebra with intramural diverticulosis localized to this area (Fig. 4). There was marked spastic activity confined to this segment, the lumen varying from complete obliteration to a maximal diameter of 9 mm. Apart from the projection of narrow-necked diverticula the contours at the site of narrowing were smooth. No other lesion was seen.

The patient's symptoms improved spontaneously but radiographs in 1972 showed the same picture. In 1974 there were fresh bouts of dysphagia. Oesophagoscopy at this time revealed no organic stricture, and mucosal biopsies were essentially normal.

CASE 4 A man aged 64 presented in July 1969 with two months' history of substernal pain, vomiting, and dysphagia. He was found to have a gastric carcinoma involving the cardia and the lower 5 cm of oesophagus. A partial oesophago-gastrectomy with splenectomy was performed. The lower third of the oesophagus was removed.

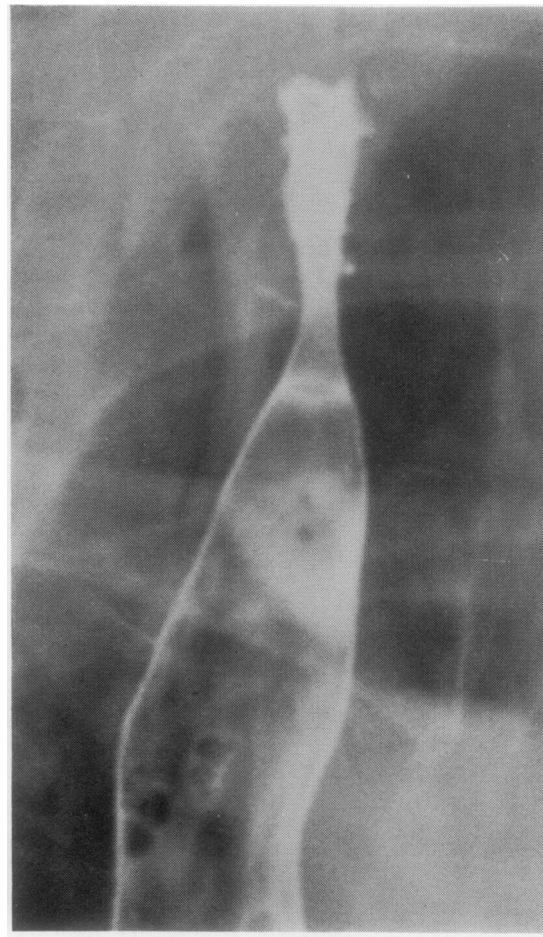

(*a*)

FIG. 4. *Case 3. (a) Barium study showing a constricted segment of oesophagus with intramural diverticula. (b) Barium study of upper oesophagus during relaxation. The 'shouldering' effect on the barium column indicates muscle hypertrophy.*

Thorax: first published as 10.1136/thx.30.3.278 on 1 June 1975. Downloaded from http://thorax.bmj.com/ on April 19, 2024 by guest. Protected by copyright.

and an oesophagogastric anastomosis was effected behind the hilum of the left lung. The tumour was a poorly differentiated adenocarcinoma; the removed regional lymph nodes were free of growth.

His postoperative course was satisfactory. During 1970 he had occasional sudden total blockage on swallowing solids, and by July 1971 this was happening nearly every day. Oesophagoscopy showed a narrow anastomosis but no evidence of oesophagitis and no recurrence of growth. A biopsy showed moderate inflammatory cell infiltration of the lamina propria.

After dilatation, his symptoms improved for several months, but sudden bouts of dysphagia then recurred, and oesophagoscopy in July 1972 showed increased narrowing which appeared to be due to spasm. Self-bouginage was tried with partial success. Mucaine also afforded some relief, and the patient's symptoms have improved but still recur sporadically.

A preoperative barium swallow in 1969 showed a dilated oesophagus full of debris above a polypoid growth; no intramural abnormality was seen. Repeat radiographs in June 1972 revealed a smooth anastomosis 10 cm below the lower border of the aortic arch. The segment of oesophagus below the arch contained numerous intramural diverticula (Fig. 5). In April 1973 the general appearance was unchanged, but the diverticula were much less evident.

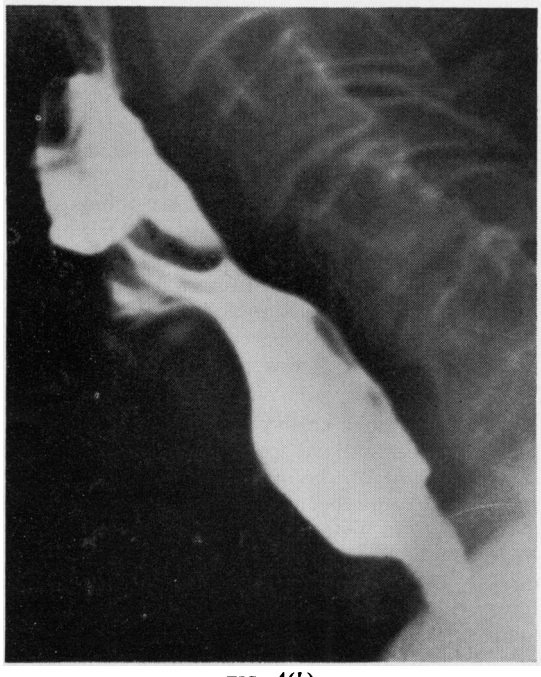

FIG. 4(*b*)

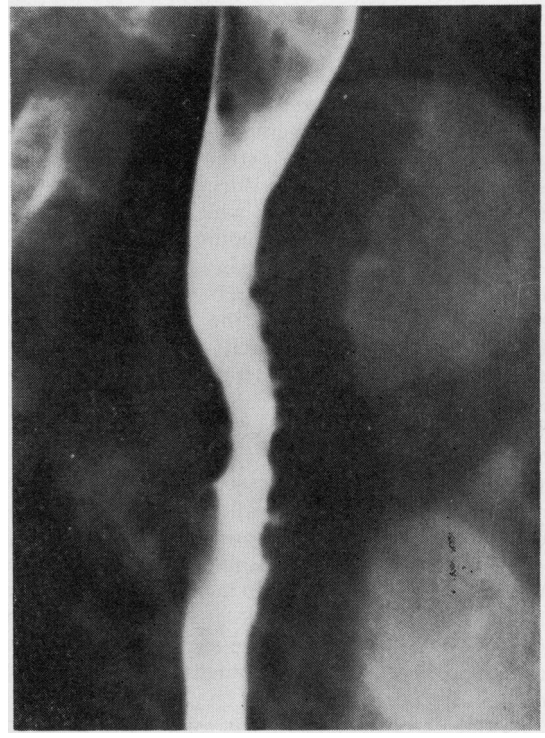

FIG. 5. *Case* 4. *Barium study showing intramural diverticula in the remaining mid-segment of oesophagus following resection.*

DISCUSSION

With the addition of these four cases, a published series of 16 patients is available for review, and a clearer picture is possible of the salient features of this condition.

PRESENTING SYMPTOMS Ten of the 16 patients were males. Their ages ranged from 11 to 83 years. In every case the primary symptom was dysphagia for solids. In three young subjects this dated from infancy (Culver and Chaudhari, 1967; Cramer, 1972; Weller, 1972); in others the length of history ranged from a few weeks to 18 years. The dysphagia was often abrupt, total, and episodic in nature—sometimes leading to emergency hospital admission. In one case only five episodes had occurred in five years (Hodes *et al.*, 1966). Pain was not a prominent feature of the dysphagia, except in two cases with lower oesophagitis associated with hiatus hernia (Mendl *et al.*, 1973 case 2), two cases with moniliasis, and Weller and Lutzker's

Thorax: first published as 10.1136/thx.30.3.278 on 1 June 1975. Downloaded from http://thorax.bmj.com/ on April 19, 2024 by guest. Protected by copyright.

case (1971) of alkaline oesophagitis following total gastrectomy.

RADIOLOGICAL FEATURES Barium studies have been thoroughly documented. Consistent features of the diverticula are the extremely narrow necks, which may be obliterated during muscle contraction, and the bulbous ends which nearly all lie at a constant depth corresponding to the thickness of the oesophageal wall. It is now apparent that in every case there has been either a stenosed segment at some level of the oesophagus, or a diffuse sustained hypertonicity, or both. In addition, Hodes *et al.* (1966) described 'hyperperistalsis, which was at times deep and segmenting'. In the case of Weller and Lutzker (1971) there was 'total oesophageal irritability, and tertiary oesophageal contractions were seen', and in Weller's second case (1972) cine radiography showed disordered motor activity above a stricture. Mendl *et al.* (1960) observed irregularity of contractions indicating a neuromuscular incoordination; while in the later case of Mendl *et al.* (1973) violent propulsive contractions were seen to originate in a narrowed and hypertrophied segment in the mid-oesophagus.

A degree of localized narrowing was evident in 12 of the 16 cases. In Weller and Lutzker's patient this was adjacent to the site of oesophago-jejunostomy and was probably an organic post-inflammatory stricture. In two young subjects with upper oesophageal hold-up a congenital stricture was implied, but there was no evidence as to its nature (Culver and Chaudhari, 1967; Cramer, 1972). In all the other cases there was some evidence that narrowing, when present, was due to localized muscular hypertonus rather than a fibrous stricture. Hodes *et al.* (1966), for example, demonstrated hold-up of a capsule given with a barium swallow, and subsequently at endoscopy a lima bean was found at the same level, but there was no obstruction to the instrument.

In both cases of presumed congenital stricture it was stated that oesophageal motor activity was normal. However, as Weller and Lutzker (1971) pointed out, an area of increased resistance anywhere in the oesophagus can be expected to trigger the propagation of forceful peristaltic waves throughout its length. It is reasonable to suppose that episodes of obstructive dysphagia would be accompanied by violent muscular contractions which in these particular patients were not apparent at other times.

With regard to the distribution of the diverticula, these were either diffuse (nine cases) or confined to a segment of oesophagus, and this segment was either at the level of a stricture (three cases) or at the site of prolonged but remittent spasm (four cases). In our present series all four cases on radiography showed segments of tonic contraction but no stenosis. Diverticulosis was mainly confined to these segments, but in case 1 it was more diffuse.

In Weller's two cases, and in our case 4, diverticulosis was seen to develop in a segment of oesophagus where it was not demonstrable previously.

In two cases (Zatzkin *et al.*, 1968; Cramer, 1972) there was the appearance of an anterior pharyngo-oesophageal web. In neither case was this the site of obstruction, and the significance of this finding is doubtful.

Oesophageal moniliasis was present in three patients (Zatzkin *et al.*, 1968; Troupin, 1968; Creely and Trail, 1970). All were elderly negro women; in one there was severe dental caries and stomatitis. The radiological appearances of diverticula at and below the level of a stricture in Troupin's case bore some resemblance to the condition that we are describing, but the typical, narrow necks and bulbous ends were not a constant feature. In Zatzkin's patient the abnormalities were diffuse and florid, the protrusions were irregular in shape, and many of them were broad-based. In a subsequent report on the same case, Smulewicz and Dorfman (1971) showed how these changes resolved into frank ulceration and later healed with antibiotic therapy. The radiographic appearances resembled those of other examples of oesophageal moniliasis (Andrén and Theander, 1956; Kaufman, Scheff, and Levene, 1960).

A monilial invasion of the oesophagus had modified the picture in both cases, and it would be unwise to draw firm conclusions as to whether a true intramural diverticulosis was present, and if so whether it preceded or followed the infection. In Creely and Trail's case (1970), however, the monilial overgrowth was probably incidental.

ENDOSCOPY AND BIOPSY The appearances at oesophagoscopy have contributed little to our understanding of the nature of the diverticula; these have only been visualized by Creely and Trail (1970) in a strictured oesophagus which was hyperaemic. The four other cases of inflammation due to either moniliasis or reflux oesophagitis have already been mentioned. In all other cases, apart from segments of concentric narrowing, the oesophageal mucosa has appeared normal at oesophagoscopy.

Thorax: first published as 10.1136/thx.30.3.278 on 1 June 1975. Downloaded from http://thorax.bmj.com/ on April 19, 2024 by guest. Protected by copyright.

Superficial biopsies have revealed only mild chronic inflammatory changes. Biopsy in case 1 is of some significance since it revealed a hypertrophic, folded mucosa with deep processes extending into the submucosa, an appearance consistent with true pulsion diverticulosis. Similar histological evidence of a mucosal diverticulum was published by Weller (1972).

SUBSEQUENT COURSE On follow-up, both the symptoms of dysphagia and the radiological appearance of diverticulosis tend to remain unchanged (Mendl *et al.*, 1960; Hodes *et al.*, 1966; Culver and Chaudhari, 1967).

In case 1 the radiographic changes persisted even in the absence of symptoms. In other cases, good symptomatic remission has been obtained after repeated endoscopies and bouginage, and on radiography the diverticulosis has improved (Cramer, 1972; Weller, 1972; case 4) or even disappeared (Weller and Lutzker, 1971). The radiographic improvement implies not only a failure to fill some diverticula at their previous site, but an actual shrinkage of those that are outlined.

PATHOGENESIS For some years the nature of this condition was obscure. Mendl *et al.* (1960) believed that deranged muscular activity was the direct cause of hernial protrusions of intact mucosa through points of weakness in the oesophageal wall—and drew attention to the close similarity to intramural diverticulosis of the gall-bladder (the Rokitansky-Aschoff sinuses). When the next case was reported by Hodes *et al.* in 1966, their findings were consistent with this view; however they questioned whether the appearances might be due to dilatation of the deep mucous glands in response to unrecognized chronic inflammation—analogous to the dilatation of bronchial mucous glands in chronic lung disease.

These authors further suggested that the underlying cause might be moniliasis, a view which gained support with the publication of causes of moniliasis by Troupin (1968) and Zatzkin *et al.* (1968). In these particular patients, as already described, the infection was florid and readily recognized, and the appearances were quite atypical. The negative findings in subsequent cases of intramural diverticulosis exclude this as a causal factor. Zatzkin *et al.* (1968) suggested that the protrusions might be 'collar stud' abscesses due to intense oesophagitis, but this is not consistent with the findings or the clinical course. There is nothing to suggest the presence of severe or purulent oesophagitis, and in some cases the mucosa has been virtually normal.

Wightman and Wright (1974) recently published the first necropsy report on this condition. Their findings confirmed the presence of epithelial hyperplasia and the absence of acute inflammation. They observed varying degrees of dilatation of the mucous glands. Although the diverticular ducts were lined with squamous epithelium, they believed that these ducts had their origin in the mucous glands. While it is quite possible that dilated mucous glands could represent sites of relative weakness in the oesophageal wall, in our opinion these authors have failed to stress the underlying importance of muscle spasm with raised intraluminal pressure in the formation of diverticula.

Oesophageal motility is deranged either as a result of obstruction, or after surgical interruption of continuity, or more often through some intrinsic defect which is not understood but which is probably related to previous inflammation. Moersch and Camp (1934) described the condition of 'diffuse spasm of the lower oesophagus' as a clinical entity which seems applicable to a number of cases in this series. The nature of this disorder and its relation to muscle hypertrophy was reviewed by Bennett and Hendrix (1970); hypersensitivity to pentagastrin has recently been reported (Eckardt and Weigand, 1974).

In our previous case (Mendl *et al.*, 1973), the localization of deep intramural diverticula to a segment of severely spastic and hypertrophied muscle clearly points to a direct relationship. In this case there was the possibility of damage by trauma 30 years previously. In Mendl's original case (Mendl *et al.*, 1960) there was also some evidence of previous deep inflammation with para-oesophageal adhesions.

The deranged motor activity is a non-specific response, thus it is quite possible (if unproven) that diverticulosis could arise as a sequel to moniliasis. Gastro-oesophageal reflux may have played a causal role in some cases, but there is no evidence that it featured in the majority.

The analogy to Rokitansky-Aschoff sinuses in the gall-bladder is a close one. It is now recognized that this is a condition of pulsion diverticulosis resulting from repeated rises of intraluminal pressure and over-distension, with associated muscle hypertrophy and chronic inflammatory changes (Halpert, 1927; Robertson and Ferguson, 1945; Colquhoun, 1961). Although the condition in the gall-bladder is usually diffuse, there may be segmental muscle hypertrophy with

Thorax: first published as 10.1136/thx.30.3.278 on 1 June 1975. Downloaded from http://thorax.bmj.com/ on April 19, 2024 by guest. Protected by copyright.

stenosis, the diverticula being deeper and more numerous at the site of hypertrophy (Mendl, unpublished).

Intramural diverticulosis of the oesophagus is an unusual finding, but the fact that four cases have been encountered by one radiologist (K. M.) in the space of 14 years suggests that it is not excessively rare. It seems surprising that it was not recognized prior to 1960, despite a number of reviews of oesophageal disease including pulsion diverticula (Habein *et al.*, 1956; Mustard, 1957).

Although complete regression is unlikely, this appears to be a chronic but relatively benign disease, its course depending on the underlying disorder. There is no evidence that the diverticula have ever directly caused symptoms or acted as a significant source of infection.

We are grateful to Dr. D. D. Gibbs and Dr. A. V. Barford who supplied us with clinical information on cases 2 and 3, and to Dr. B. O'Hare and Dr. P. W. Robertson for the radiological findings in cases 2 and 4. We are also indebted to Dr. R. G. F. Parker for the biopsy report on case 1.

REFERENCES

Andrén, L. and Theander, G. (1956). Roentgenographic appearances of oesophageal moniliasis. *Acta Radiologica*, **46**, 571.

Bennett, J. R. and Hendrix, T. R. (1970). Diffuse oesophageal spasm: a disorder with more than one cause. *Gastroenterology*, **59**, 273.

Colquhoun, J. (1961). Adenomyomatosis of the gall-bladder. *British Journal of Radiology*, **34**, 101.

Cramer, K. R. (1972). Intramural diverticulosis of the oesophagus. *British Journal of Radiology*, **45**, 857.

Creely, J. J. and Trail, M. L. (1970). Intramural diverticulosis of the esophagus. *Southern Medical Journal*, **63**, 1257.

Culver, G. J. and Chaudhari, K. R. (1967). Intramural esophageal diverticulosis. *American Journal of Roentgenology*, **99**, 210.

Eckardt, V. and Weigand, H. (1974). Supersensitivity to pentagastrin in diffuse oesophageal spasm. *Gut*, **15**, 706.

Habein, H. C., Kirklin, J. W., Clagett, O. T., and Moersch, H. J. (1956). Surgical treatment of lower esophageal pulsion diverticula. *Archives of Surgery*, **72**, 1018.

Halpert, B. (1927). Morphological studies on gall-bladder: development and microscopic structure of normal human gall-bladder. *Bulletin of Johns Hopkins Hospital*, **40**, 390.

Hodes, P. J., Atkins, J. P., and Hodes, B. L. (1966). Esophageal intramural diverticulosis. *American Journal of Roentgenology*, **96**, 411.

Kaufman, S. A., Scheff, S., and Levene, G. (1960). Esophageal moniliasis. *Radiology*, **75**, 726.

Lane, J. W. (1972). Intramural esophageal diverticulosis: a case report. *Journal of the Arkansas Medical Society*, **69**, 87.

Mendl, K., McKay, J. M., and Tanner, C. H. (1960). Intramural diverticulosis of the oesophagus and Rokitansky-Aschoff sinuses in the gall-bladder. *British Journal of Radiology*, **33**, 496.

——, Montgomery, R. D., and Stephenson, S. F. (1973). Segmental intramural diverticulosis associated with and confined to a spastic area of muscular hypertrophy in a columnar lined oesophagus. *Clinical Radiology*, **24**, 440.

Moersch, H. J. and Camp, J. D. (1934). Diffuse spasm of the lower part of the esophagus. *Annals of Otology, Rhinology and Laryngology*, **43**, 1165.

Mustard, R. A. (1957). Diverticula of the esophagus. *Canadian Medical Association Journal*, **76**, 822.

Robertson, H. E. and Ferguson, W. J. (1945). Diverticula (Luschka's Crypts) of the gall-bladder. *Archives of Pathology*, **40**, 312.

Smulewicz, J. J. and Dorfman, J. (1971). Esophageal intramural diverticulosis: a re-evaluation. *Radiology*, **101**, 527.

Troupin, R. H. (1968). Intramural esophageal diverticulosis and moniliasis. *American Journal of Roentgenology*, **104**, 613.

Weller, M. H. (1972). Intramural diverticulosis of the esophagus: report of a case in a child. *Journal of Paediatrics*, **80**, 281.

—— and Lutzker, S. A. (1971). Intramural diverticulosis of the esophagus associated with post-operative hiatal hernia, alkaline esophagitis, and esophageal stricture. *Radiology*, **98**, 373.

Wightman, A. J. A. and Wright, E. A. (1974). Intramural oesophageal diverticulosis: a correlation of radiological and pathological findings. *British Journal of Radiology*, **47**, 496.

Zatzkin, H. R., Green, S., and LaVine, J. J. (1968). Esophageal intramural diverticulosis. *Radiology*, **90**, 1193.

Requests for reprints to: Dr. R. D. Montgomery, F.R.C.P., East Birmingham Hospital, Bordesley Green East, Birmingham, B9 5ST.

Thorax: first published as 10.1136/thx.29.3.278 on 1 June 1975. Downloaded from http://thorax.bmj.com/ on April 19, 2024 by guest. Protected by copyright.