Thorax (1948), 3, 1.

Mon 7
Sam 1

HYDATID DISEASE OF THE LUNG

BY

A. LOGAN AND H. NICHOLSON

From the Department of Surgery, University of Edinburgh, and the Brompton Hospital, London

The following cases of hydatid disease of the lungs are recorded because in them an attempt was made to follow the behaviour of the pulmonary cavity ("empty sac") after removal of the cyst.

Literature

Lendon (1902) pointed out that, although it had been generally assumed that the cavity in the lung left after removal of a hydatid cyst soon becomes obliterated, this was not by any means invariable. He described two cases in which a pulmonary cavity was found at necropsy some time after complete expulsion of the hydatid membranes by coughing.

Dew (1928) stated that in some cases in which the cyst was large or the adventitia thick, particularly when it was situated in the upper part of the lungs, complete collapse of the cavity and re-expansion of the lung did not occur.

In an article based on sixteen cases of bilateral pulmonary cysts from the Australasian Hydatid Registry, Christie (1938) stated that when the cyst had thin walls and was not infected, obliteration of the lung cavity soon took place. In patients radiographed at intervals of four months, ten months, and four years respectively after removal of the cyst, no evidence of a residual cavity was seen. In a bilateral infected case there was no evidence of residual cavitation after seven months.

Writing of the pulmonary cavity, Barrett (1947) stated that it was usually quickly obliterated after removal of the parasite. If it persisted for as long as six months it was likely to be permanent and to become lined with bronchial epithelium. Such a lung cyst might remain for years without causing symptoms, but the possibility of haemorrhage from it or infection within it was always present. The type of case in which the pulmonary cavity was likely to persist was that in which the adventitia was thick and tough at the time of operation. Those cases in which inflammation had occurred around a simple hydatid, or in which daughter cysts had formed, were also likely to have persistent pulmonary cavities after removal of the parasite.

Case Reports

Case 1.—An Italian prisoner of war, aged 23, was admitted on July 23, 1943, after having been admitted to another military hospital on June 8 on account of pain in the right side of his chest, cough, and a small amount of sputum. On June 23 his sputum was blood-stained. On July 16 from his right chest 15 ml. of cloudy fluid were aspirated, in which hooklets of *Taenia echinococcus* were identified on microscopy.

On admission he was in good general condition. The abnormal physical signs were limited to the right chest. Rib movements were almost absent in the right lower series; there was impairment of the percussion note below the spine of the right scapula, and dullness to percussion below the angle; breath sounds were weak but audible to within two inches of the right base. There was no finger-clubbing.

The radiograph of the chest showed a dense opacity in the right lower lung field posteriorly (Plate I*a* and *b*). A white cell count showed a total of 8,200 leucocytes per c.mm., of which 7 per cent were eosinophils. A Casoni test was positive. Six sputum examinations were negative for tubercle bacilli, and a blood Wassermann reaction and Kahn test were negative.

Bronchoscopy was performed on July 29, and the only abnormality found was an alteration in the direction of the right stem bronchus, which curved over a rounded prominence postero-medial to it.

On Aug. 2, under general anaesthesia, 4 in. of the ninth rib on the right side were resected from the transverse process laterally. The pleura was found to be free in the lateral half of the wound. A gauze pack was placed intrapleurally and the wound closed over the pack. Radiographs after operation showed a small pneumothorax with an anterior fluid level on the right side. Air and fluid were aspirated through the anterior axillary region. On Aug. 19, under local anaesthesia, the old incision was reopened and the pack removed. The main right pleural cavity was not opened by this manœuvre, and the hydatid cyst was aspirated. The adventitia was then incised and

the parasitic membranes were taken out intact. The wound was closed round a tube draining the pulmonary cavity into the dressing.

Convalescence was calm and there was little drainage from the tube. Repeated sinusograms showed no diminution in the size of the cavity, and on Nov. 13 the tube was removed. By Nov. 27 the track had healed. A radiograph at this time showed the right diaphragm slightly raised but no evidence of cavitation in the lung field (Plate I*c*). A bronchogram showed bronchiectasis of all branches of the right lower bronchus, and a cavity deep to the angles of the eighth and ninth ribs in communication with the bronchial tree (Plate II*a* and *b*).

This patient was kept under observation. He continued to have a little cough and sputum, and by April, 1944, he was observed to have early clubbing of the fingers. The right bronchogram was repeated on July 19 and was found to be unchanged.

In view of the bronchiectatic right lower lobe and the persistence of the pulmonary cavity, a right lower lobectomy was carried out on Nov. 28, 1944. This was followed by relief of symptoms, and the patient was discharged well.

Case 2.—A corporal in the Royal Hellenic Air Force, aged 24, was admitted on Feb. 28, 1945. He had been well until September, 1944, when he began to have pain in the right side of his chest. This lasted for several weeks and then disappeared, but recurred in December. He was admitted to another military hospital on Feb. 8, 1945, and fluid was aspirated from his right chest.

On admission he was in fair general condition. Abnormal physical signs were limited to the right side of the chest. Rib movements were restricted in the right middle and lower series. The percussion note was dull in the right axilla and over the anterior part of the chest. Breath sounds were distant in the right axilla with râles and an area of bronchial breath sounds. There was no finger-clubbing.

The Casoni test was negative. A white cell count showed 11,850 leucocytes per c.mm., of which 7 per cent were eosinophils. Radiographs showed a dense, sharply outlined opacity anteriorly in the right lower chest. It was surmounted by a translucent space (Plate III*a* and *b*).

On March 19, under local anaesthesia, a right thoracotomy was performed by resection of the fifth rib lateral to the nipple. The pleura was adherent. The adventitia was incised and a large infected hydatid cyst, its wall invaginated and folded to form an almost solid mass, was removed. There was a large bronchial fistula into the pericyst. The pulmonary cavity was drained by a rubber tube to the dressing, and the wound was closed.

A piece of the pericyst wall was removed and showed, on microscopic examination, a deep layer of degenerate connective tissue containing foci of lymphocytes surrounded by a layer of fibrotic granuation tissue. No lung tissue was seen.

The fluid from the pericyst was yellow and turbid. Microscopy revealed Gram-positive cocci, a few Gram-negative bacilli, numerous epithelial cells, and degenerate polymorphs. On culture, non-haemolytic streptococci and *Micrococcus catarrhalis* were grown.

The healing of the pulmonary cavity was followed by sinusograms, and on May 14 only a tubular track remained. The tube was removed, and by June 30 the track had healed. A Casoni test on July 2 showed a strongly positive reaction. A radiograph on July 9 showed some opacity in the right anterior chest and thickening of the transverse fissure, which was slightly displaced downwards. A bronchogram on July 10 showed some tubular bronchiectasis of the anterolateral branch of the right upper bronchus. No cavities were filled, and the rest of the bronchial tree was normal (Plate III*c* and *d*).

The patient was then well and free from symptoms.

Case 3.—A petty officer in the Royal Navy, a Palestinian aged 22, admitted on Oct. 25, 1944, was born in a small town in Poland and had lived there until the age of 16, when he went to Haifa. He had been in the Royal Navy for two and a half years. He had had malaria five years before, but otherwise had been well. He had had cough and sputum for six months before admission, and pain in the right side of his chest anteriorly for three weeks. On the day before admission he had had a slight haemoptysis. He had been admitted to another military hospital on Oct. 10 with a temperature of 102° F. There, on Oct. 20, from his right chest watery fluid had been aspirated in which scolices and hooklets of *Taenia echinococcus* had been identified.

On admission he was ill and had a temperature of 102° F. He was coughing up a small quantity of purulent sputum. Abnormal physical signs were confined to the right side of his chest. There was an inflamed aspiration puncture posteriorly at the level of the spine of the fifth thoracic vertebra. The rib movements were diminished in the right middle and lower series. The percussion note was not impaired. There were râles on the right side posteriorly in the scapulo-vertebral interval at the level of the spines of the fourth, fifth, and sixth thoracic vertebrae. His fingers were clubbed.

A radiograph of his chest showed a large opacity in the right side, in contact with the posterior chest wall at the level of the second costal cartilage. The opacity was surmounted by a translucent crescent. There was a second opacity in the postero-inferior part of the left chest just visible to the left of the cardiac apex (Plate IV*a* and *b*). A white cell count showed 12,600 leucocytes per c.mm., of which 1 per cent were eosinophils. A Casoni test was not done.

Shortly after admission he began to cough up large quantities of thin fluid which caused him considerable respiratory difficulty, and on Oct. 29 he was operated on as an emergency. The sixth right rib was resected at its angle, and a small empyema pocket about 5 c.cm. in size opened. The main pleural cavity was

not laid open, and the pericyst was incised. The parasitic membranes, which were almost empty, were removed. A large bronchial fistula was present. Since it was believed that this cyst was infected, no attempt was made to close the pulmonary cavity, which was drained by a rubber tube to the dressing. The wound was closed round the tube.

The operation was followed at once by great improvement in the patient's general condition, and his cough and sputum immediately ceased. The pus from the pleural empyema pocket contained numerous polymorpho-nuclear cells, but no organisms were seen in the direct smear. It was sterile on culture. A Casoni test was done on Nov. 2 with hydatid fluid from the Hadassah Hospital, and was negative. On Dec. 4 the drainage tube was removed. The wound had healed by Jan. 23, 1945.

The opacity to the left of the heart shadow, observed in the first radiograph (Plate IV*a* and *b*), was seen in a left lateral view to lie posteriorly and was believed to represent another hydatid cyst. On Feb. 5 the left side of the chest was explored by a postero-lateral thoracotomy through the ninth rib bed. No cyst could be palpated in the left lung, but there was a plaque of thick pleura over the diaphragm and lower lobe which no doubt explained the radiographic appearances. A biopsy of this thickened pleura was carried out and the chest wall closed. Microscopic examination of the specimen showed only fibrous tissue.

The behaviour of the residual cavity in the right lung was followed by serial radiographs and by bronchograms on Jan. 10 and on March 21, 1945. The patient remained well, and on June 30, 1945, it was noted that his finger-clubbing had disappeared. The Casoni test was repeated on July 2, and a negative immediate but weak positive delayed reaction was obtained.

A radiograph on July 2 showed, apart from the post-operative rib defects, that the cavity outline could still be made out in relation to the right sixth rib. A bronchogram on July 10 showed the cavity clearly filled and unchanged in size since the earlier bronchograms. The cavity was in communication with the bronchial tree and probably in relation to the postero-lateral segment of the right upper lobe (Plate IV*c* and *d*). The patient then felt well but had a trace of sputum.

Case 4.—An Italian co-operator, aged 25, admitted on Sept. 6, 1944, had had malaria in 1943 and injections for syphilis since January, 1944. He became ill on Aug. 8, 1944, with pain in his right lower chest and a dry cough. He was admitted to another military hospital and began to have scanty purulent sputum, blood-stained on one occasion.

On admission he was in fair general condition. Abnormal physical signs were confined to the right side of the chest. Rib movements were reduced in the right lower series. The percussion note was impaired below the middle of the vertebral border of the scapula on the right side. Breath sounds were absent below the angle of the scapula, and there were râles medial to the angle. The fingers were clubbed.

The radiograph of the chest showed a dense opacity situated posteriorly just above the diaphragm on the right side. The Casoni test was negative. A white cell count showed a total of 15,200 leucocytes per c.mm., of which 2 per cent were eosinophils.

On Sept. 11, under general anaesthesia, thoracotomy was performed through the seventh interspace on the right side. The lower lobe was adherent posteriorly over the cyst to the chest wall and was separated from it. The adventitia was incised after aspiration of the hydatid cyst. The parasitic membranes were then removed intact. A bronchial fistula communicated with the pericyst, which contained a little purulent material. A swab of this material was taken for microscopic examination and culture. The lung cavity, with its bronchial fistula, was then obliterated by infolding with sutures. The chest was closed without drainage.

The swab from the pericyst cavity showed numerous pus cells but gave no growth on culture.

The postoperative course was at first stormy. A tension pneumothorax due to persistence of a broncho-pleural fistula developed, and on Sept. 12 a self-retaining intercostal catheter was introduced into the right pleural cavity and attached to a water-seal. After this, progress was satisfactory, and on Oct. 23 a sinusogram showed that the drainage tube was in communication with a small posterior cavity which communicated with the bronchial tree. The tube was then removed and the track healed by Nov. 11.

On Dec. 13, 1944, the patient was well and free from symptoms. A plain radiograph showed no pulmonary cavitation (Plate V*a*). A bronchogram showed a small cavity in communication with the posterior basic branch of the right lower bronchus (Plate V*b* and *c*).

Case 5.—A Yugoslav refugee boy, aged 16, admitted on Oct. 4, 1944, had been admitted to another military hospital on Aug. 20 because he had pain in his left chest and repeated haemoptysis. While there he had had fever, usually to 99° F. but on one occasion to 102° F.

On admission his general condition was good. The percussion note was impaired for 3 in. above the left base posteriorly. Breath sounds were weak over the impaired area. Apart from this there were no abnormal physical signs. The fingers were not clubbed.

A radiograph of the chest showed a small nearly spherical opacity occupying the medial and posterior part of the left costophrenic sulcus. A white cell count showed 10,800 leucocytes per c.mm., of which 3 per cent were eosinophils. A Casoni test gave a weak positive immediate reaction.

On Nov. 15 thoracotomy was performed through the eighth intercostal space on the left side. The

lower lobe was loosely adherent to the costal wall, and densely to the vertebral column and posterior mediastinum. The adhesions were divided and the lobe mobilized. The hydatid cyst was partly emptied by aspiration and then removed after incising the adventitia. A bronchial fistula opened into the pericyst. This was closed with catgut sutures. Part of the lobe forming the wall of the pericyst was excised, and the remaining cavity obliterated by mattress sutures. The chest wall was closed without drainage.

On Nov. 17 6 oz. of blood-stained fluid were aspirated from his left chest, and on Nov. 19 2 oz. of orange-coloured fluid were aspirated. On Nov. 24 he was up and about and very well.

A radiograph on Dec. 5 showed a completely re-expanded left lung. A bronchogram on Dec. 13 showed a cavity ¼ in. in diameter at the extremity of the posterior basic branch of the left lower bronchus. There was also bronchiectasis of the postero-lateral branch of the left upper bronchus (Plate VI*a* and *b*).

Case 6.—An Indian Sowar, aged 24, from the Scinde, was admitted on March 6, 1945, having been admitted to another military hospital on Jan. 22, 1945, with blood-stained sputum. He was said to have lost a considerable amount of weight.

On admission he was in good general condition. His rib movements were good and equal on both sides of the chest. The percussion note was dull on the right side over an area below the third costal cartilage extending to the anterior axillary line. On the left side of the chest the percussion note was dull below the level of the spine of the sixth thoracic vertebra over an area extending to the posterior axillary line. Breath sounds were absent over these dull areas. The liver was palpable for two fingers' breadth below the right costal margin. The fingers were clubbed.

A radiograph of the chest showed a "cannon-ball" shadow on each side, anteriorly on the right, posteriorly on the left (Plate VII*a*). A white cell count showed 13,350 leucocytes per c.mm., of which 6 per cent were eosinophils. A Casoni test was not done. Bronchoscopy on March 19 showed a normal larynx, trachea, and bronchial tree.

On March 21, under general anaesthesia, a left thoracotomy was performed. The hydatid cyst in the left lower lobe was aspirated, the adventitia was incised, and the cyst was removed. The lower lobe was adherent to the vertebral column and diaphragm. There were two bronchial fistulae opening into the pericyst, and these were closed with catgut sutures. The lung incision was then sutured and the chest wall closed without drainage.

The postoperative course was smooth. Some fluid collected in the left pleural cavity, and on March 24 11 oz. of this were aspirated. By April 23 the left lung field was almost clear radiologically.

On April 29, under general anaesthesia, a right anterior thoracotomy was performed through the bed of the fourth rib and cartilage, which were temporarily displaced. A large hydatid cyst in the anterior part of the lower lobe was found and aspirated. After incision of the adventitia the cyst was removed. A large part of the pericyst was then excised and the rest was infolded by large catgut sutures. The chest wall was closed without drainage.

The postoperative course was quiet. On May 2 12 oz. of blood-stained fluid were aspirated from the right pleural cavity. On June 6 the patient developed a malarial attack, which was treated. On July 2 the Casoni test was strongly positive.

On Aug. 14 a radiograph showed obliteration of the right costophrenic angle. Apart from this and the postoperative rib defects the lung fields were normal (Plate VII*b*). On the same day a bronchogram showed on the right side cylindrical dilatation of the axillary basic bronchus only. On the left side there was a posterior cavity in communication with the basic branches of the left lower bronchus. The lower bronchi were crowded together and the posterior basic branch showed cylindrical bronchiectasis (Plate VII*c* and *d*).

Finger-clubbing was still present. The patient was then free from symptoms and well.

Case 7.—A trooper of the Transjordan Frontier Force, aged 21, was admitted on Feb. 2, 1945. He had had a cough for many years which had been attributed to smoking. One year before, he had had a haemoptysis following a car accident. For six weeks before admission his cough had become rather worse. On Jan. 30, in a medical post of the Transjordan Frontier Force, his chest had been aspirated through the second left intercostal space in the midclavicular line and clear fluid had been withdrawn which was said to contain neither hooklets nor scolices.

On admission his general condition was fair. Abnormal physical signs were confined to the left side of his chest. Rib movements were absent in the left upper series and reduced in the left middle and lower series. The left base was 2 in. higher than the right. The percussion note was dull at the apex of the left axilla and was impaired over the left chest anteriorly, over the lower axilla, and at the base posteriorly below the angle of the scapula. Breath sounds were absent in the left axilla. There were no added sounds. The fingers were not clubbed.

A radiograph of the chest showed a dense opacity in the left upper lobe surmounted by a small translucent crescent (Plate VIII*a* and *b*). A white cell count showed 9,600 leucocytes per c.mm., of which 1 per cent were eosinophils. A Casoni test was not done.

On Feb. 9, under general anaesthesia, thoracotomy was performed through the fourth left intercostal space. The hydatid cyst was aspirated, the adventitia incised, and the parasitic membranes removed. In an attempt to obliterate the pericyst a bronchial

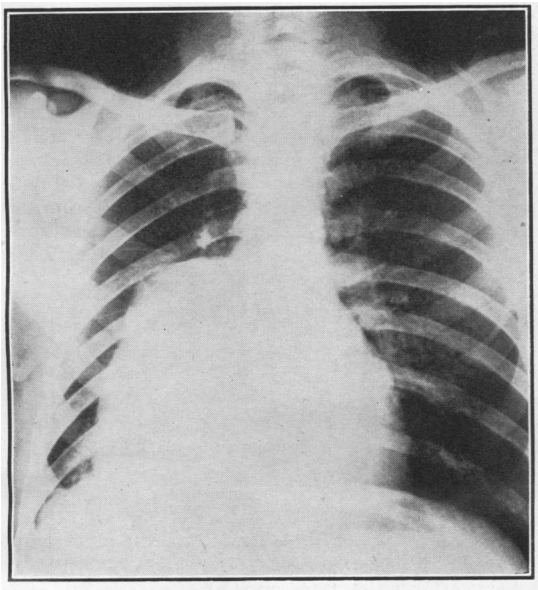

(a)

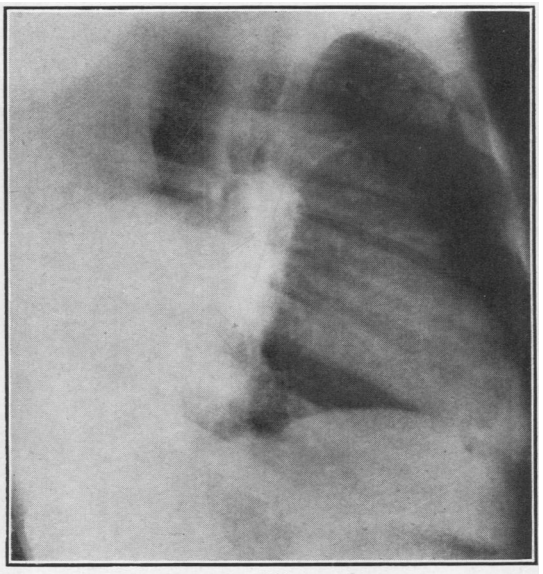

(b)

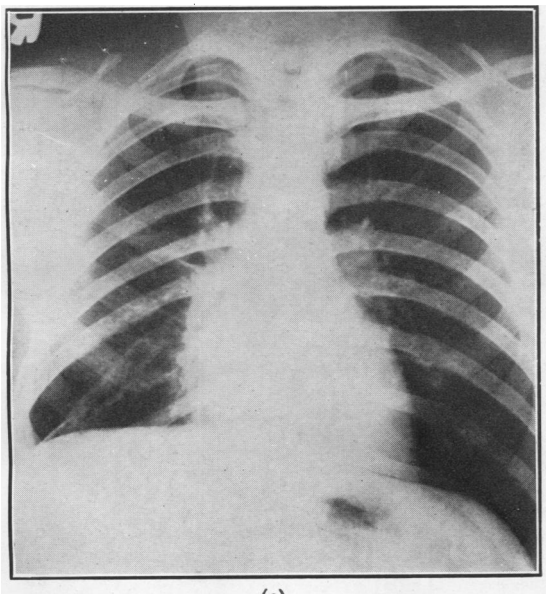

(c)

PLATE I.—Case 1. (*a* and *b*) Radiographs of chest taken on admission, showing a dense opacity in the right lower lung field posteriorly. (*c*) Radiograph taken on Nov. 27, showing diaphragm slightly raised but no evidence of cavitation in the lung field.

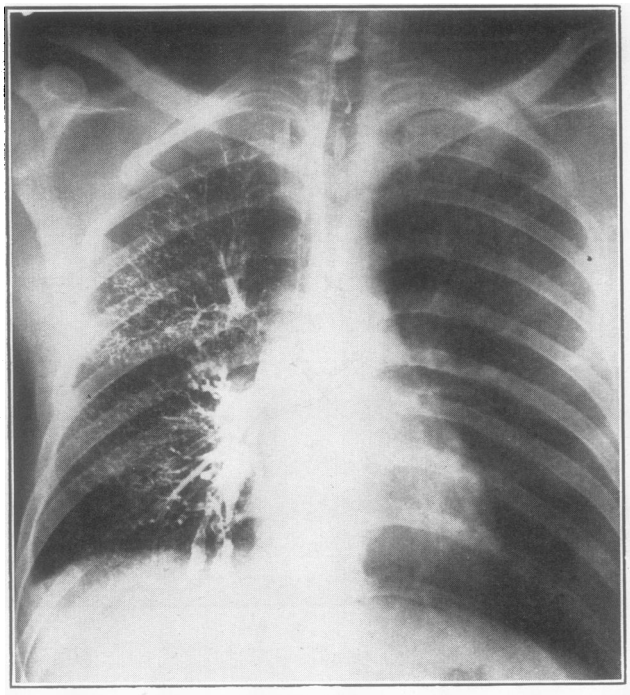

(a)

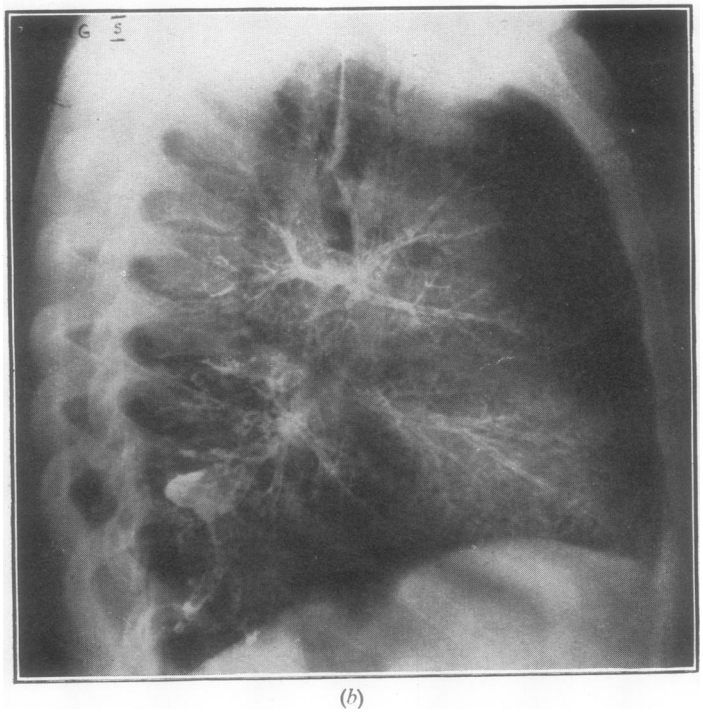

(b)

PLATE II.—Case 1. (*a* and *b*) Bronchograms showing bronchiectasis of all branches of the right lower bronchus, and a cavity deep to the angles of the eighth and ninth ribs in communication with the bronchial tree.

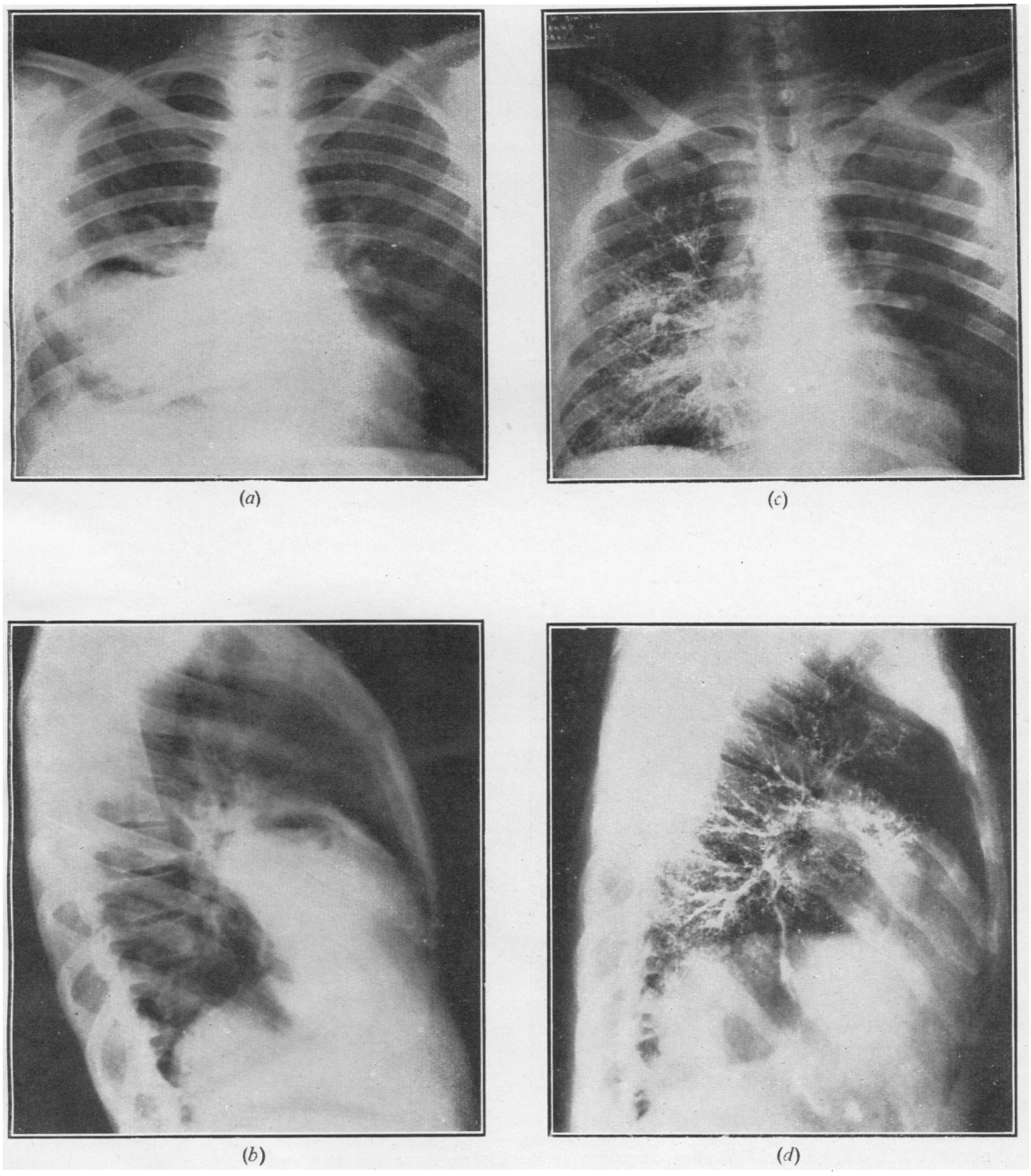

PLATE III.—Case 2. (*a* and *b*) Radiographs taken on admission and showing a dense, sharply outlined opacity anteriorly in the right lower chest, surmounted by a translucent space. (*c* and *d*) Bronchograms taken on July 10, showing some tubular bronchiectasis of the antero-lateral branch of the right upper bronchus. No cavities are filled, and the rest of the bronchial tree is normal.

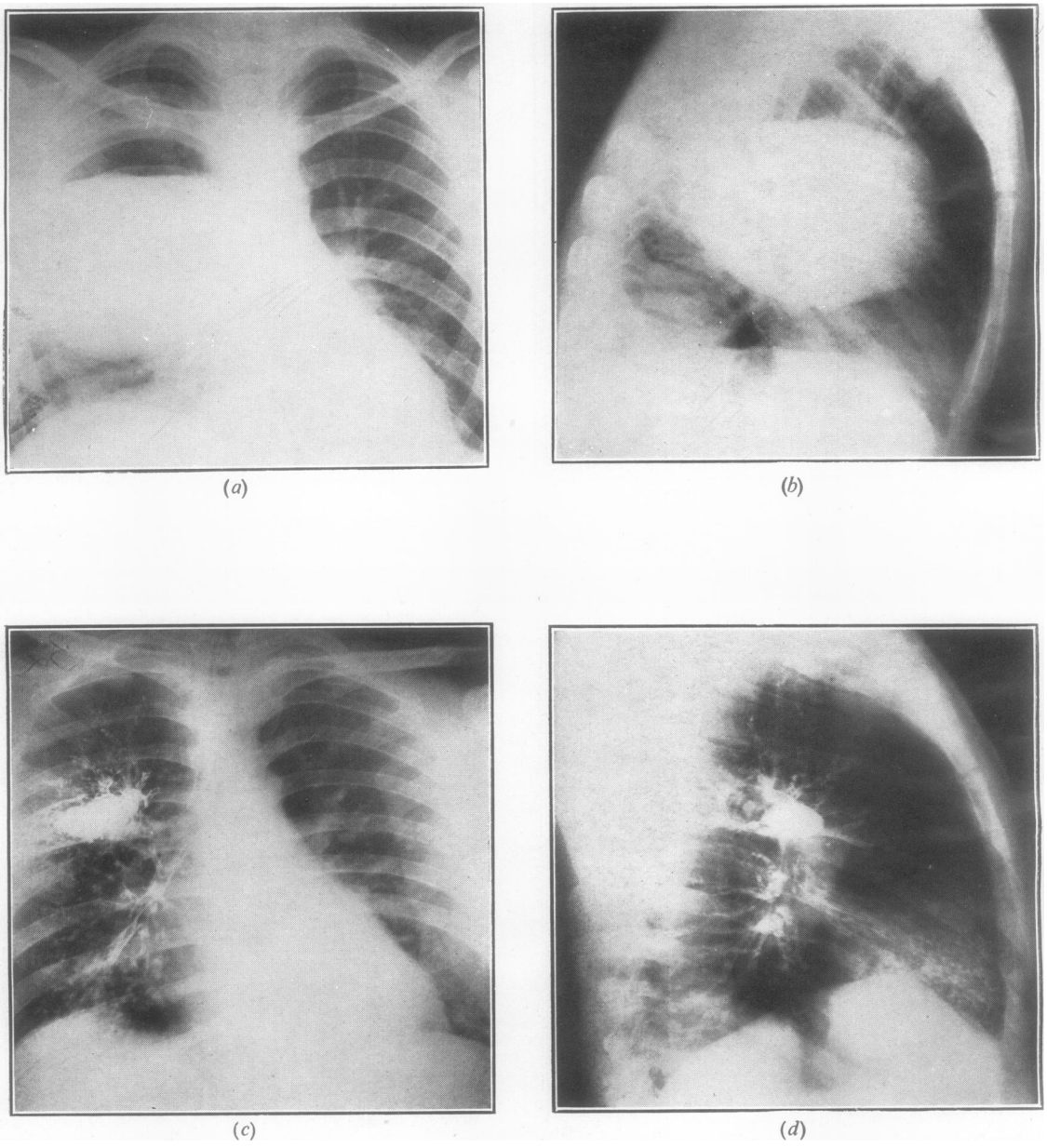

PLATE IV.—Case 3. (*a* and *b*) Radiographs taken on admission, showing a large opacity in the right side, in contact with the posterior chest wall at the level of the second costal cartilage. The opacity is surmounted by a translucent crescent. There is a second opacity in the postero-inferior part of the left chest just visible to the left of the cardiac apex. (*c* and *d*) Bronchograms taken on July 20, showing the cavity clearly filled and unchanged in size since the earlier bronchograms. The cavity is in communication with the bronchial tree and probably in relation to the postero-lateral segment of the right upper lobe.

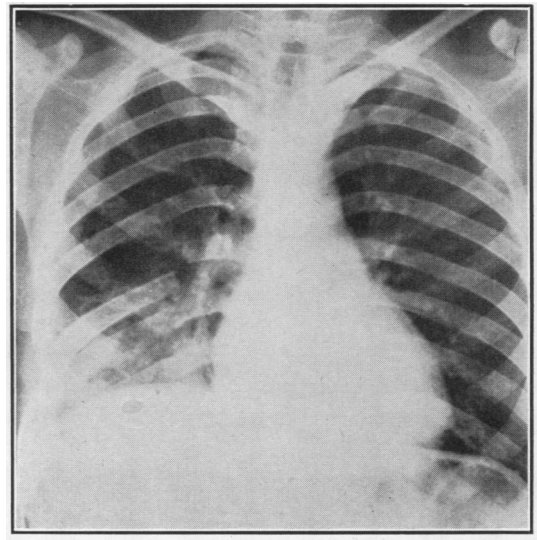

(*a*)

PLATE V.—Case 4. (*a*) Radiograph taken on Dec. 13, 1944, and showing no pulmonary cavitation. (*b* and *c*) Bronchograms showing a small cavity in communication with the posterior basic branch of the right lower bronchus.

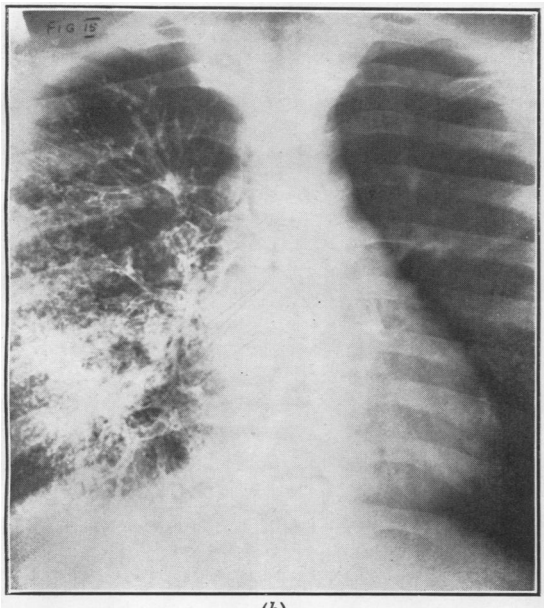

(*b*)

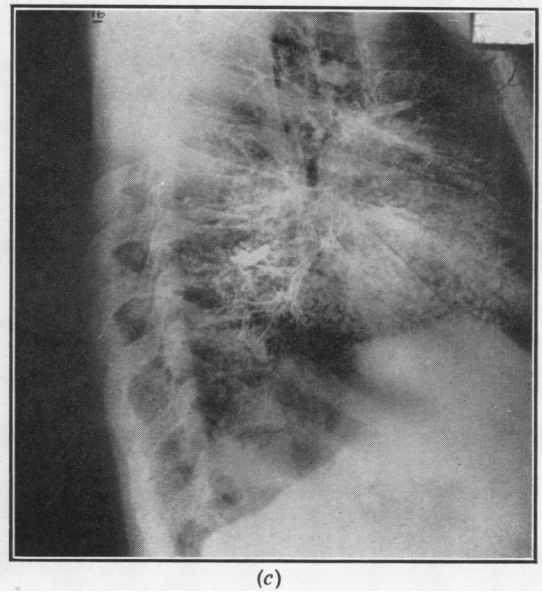

(*c*)

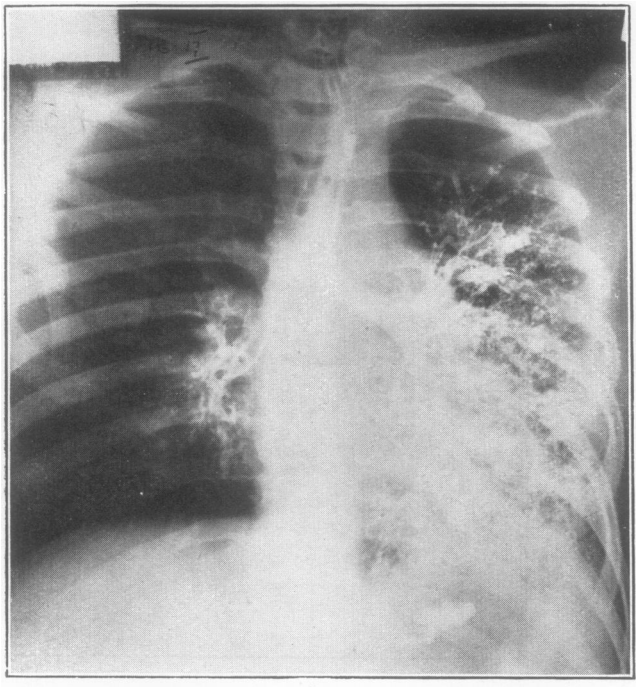

(*a*)

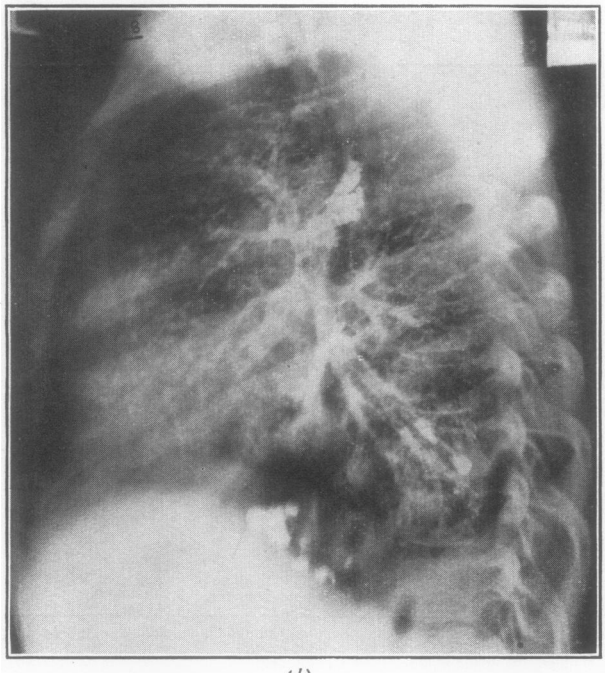

(*b*)

PLATE VI.—Case 5. (*a*) Radiograph taken on Dec. 5, showing a completely re-expanded left lung. (*b*) Bronchogram taken on Dec. 13, showing a cavity 1/4 in. in diameter at the extremity of the posterior basic branch of the left lower bronchus, and bronchiectasis of the postero-lateral branch of the left upper bronchus.

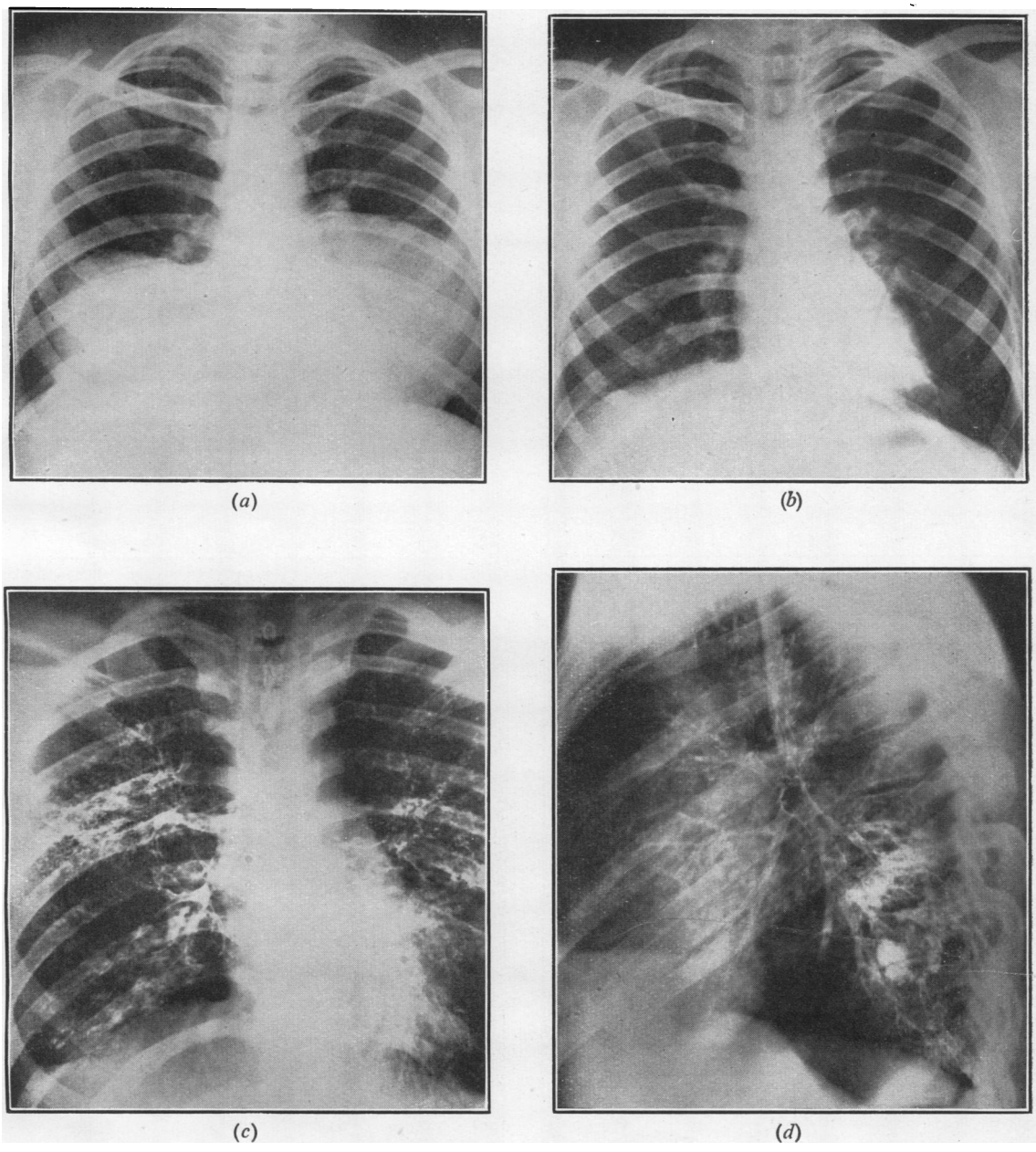

PLATE VII.—Case 6. (*a*) Radiograph taken on admission, showing a "cannon-ball" shadow on each side, anteriorly on the right, posteriorly on the left. (*b*) Post-operative radiograph showing normal lung fields. (*c* and *d*) Post-operative bronchograms showing on the right side cylindrical dilatation of the axillary basic bronchus, and on the left a posterior cavity in communication with the basic branches of the left lower bronchus. The lower bronchi are crowded together and the posterior basic branch shows cylindrical bronchiectasis.

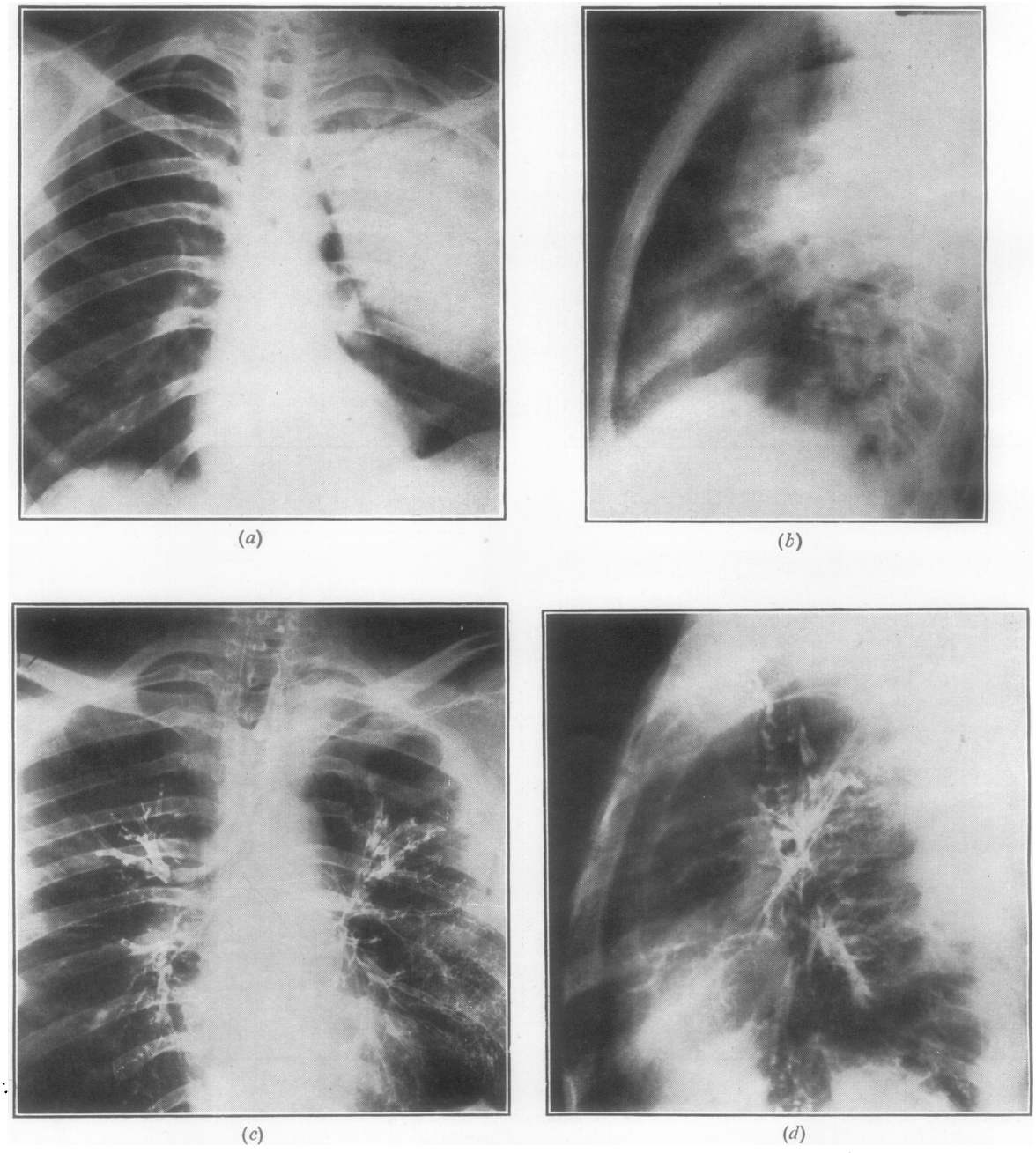

PLATE VIII.—Case 7. (*a* and *b*) Radiographs of chest, showing a dense opacity in the left upper lobe surmounted by a small translucent crescent. (*c* and *d*) Bronchograms showing dilatation of the postero-lateral branches of the left upper bronchus.

fistula which communicated with it was closed with layers of catgut sutures. The chest wall was closed, a postero-lateral intercostal drain attached to a water-seal having been inserted.

Immediately after the operation the patient was ill and febrile. A radiograph on Feb. 12 showed absorption collapse of the whole of the left lung with a high diaphragm on the left side and a hydropneumothorax. Because of the ascent of the diaphragm the intercostal drain had become inadequate. This was adjusted, and by March 5 the left lung was aerated, the diaphragm was lower, and the pleural drainage was satisfactory. On March 13 the intercostal drain was replaced by a short tube, inserted into the pleural cavity after resection of 1½ in. of the rib above the intercostal drain, and draining into the dressing.

By April 7 he was well, afebrile, and without cough. The expanding lung shut off the drainage track, which closed at the beginning of June. A radiograph on July 9 showed an almost completely re-expanded lung with thickening particularly of the axillary pleura and a small apical pneumothorax with no fluid level. A Casoni test on July 2 was negative. A bronchogram made on July 10 showed dilatation of the postero-lateral branches of the left upper bronchus. No pulmonary cavity was demonstrated (Plate VIII*c* and *d*).

Discussion

It will be seen that following the removal of eight pulmonary hydatid cysts, lung cavities were demonstrated in communication with the bronchial tree in five instances. In the case of the cyst treated by a two-stage operation a cavity was present fifteen months later. Of the two cysts which were treated by removal and drainage of the pericyst, in one case a cavity was present eight and a half months later, but in the other no cavity was demonstrated three months after the operation. In the four cases in which an attempt was made to obliterate the pulmonary cavity, two showed a cavity still present after three months and one month respectively, and two showed no evidence of a cavity after four months and five months respectively. In the case in which the pericyst was closed a residual pulmonary cavity was demonstrated five months later.

All eight cysts were large, the shadow of the smallest being 2 in. in diameter in the usual chest projection. In all but one cyst, which was infected, scolices and hooklets were seen, but none contained daughter cysts. Except in one case, in which closure of the pulmonary cavity took place within three months, the pericyst was thin, soft, and mobile where it was not closely adherent to the bony chest wall. In all instances a large bronchial fistula communicated with the pericyst.

Pre-operative bronchography was not performed. In one case it would have been inadvisable on account of the acute illness of the patient. When the hydatid cyst had been removed and it was estimated that healing had occurred, or that the condition of the lung had become stationary, a bronchogram was made in each case in order to demonstrate the closure of the pericyst and the presence or absence of associated bronchiectasis. In three cases the bronchogram revealed a persistent cavity not shown in the plain radiograph, and in two of these the patient was symptom free and had no clinical signs of a pulmonary cavity. In the lobes from which five of the hydatid cysts had been removed it outlined dilated bronchi. In all eight lobes either bronchiectasis or a persistent cavity was shown, or both were present. It was thought that either by maintenance of infection or by impairment of drainage bronchiectasis might have a delaying effect on obliteration of the residual space after removal of the hydatid cyst. Of the five bronchiectatic lobes, two showed a persistent cavity and in three the cavity apparently healed completely. In the three cases without bronchiectasis in the same segment as the hydatid cyst a cavity persisted.

Closure of the cavity draining through a bronchus might have been expected to be favoured by a position in the superior or antero-superior part of the lung rather than the inferior or postero-inferior. Two cysts were situated in the upper part of the lung, and after their removal the pericyst closed in one, but in the other it persisted, in spite of the apparently perfect drainage, for more than eight and a half months. Of the six cysts in the lower part of the lung, four lay posteriorly and two anteriorly. Healing followed removal of the two anterior cysts, but a cavity persisted after removal of each of the four posterior cysts.

The two cysts occurring in one patient were comparable in size, in the degree of associated bronchiectasis, and in the treatment applied. One was in the anterior part of the right lower lobe and one in the posterior part of the left lower lobe. The right lower lobe was healed four months after operation, while a cavity persisted in the left lower lobe more than five months after operation.

In one case only was an organism grown from the contents of the pericyst. The infection did not appear to exert an unfavourable influence on healing, because a pulmonary cavity could not be demonstrated three months after operation. In two other cases the pulmonary cavity became infected in the course of treatment by drainage through the chest wall, and persisted for fifteen months and eight and a half months respectively.

Pus was found in the pericyst in two cases at the time of removal of the hydatid cyst, but proved sterile on both occasions.

We believe that the residual cavity remains unhealed in those cases in which the bronchial fistula fails to close shortly after the removal of the parasite. In Case 2, in which the cavity closed, the external drainage track was outlined by lipiodol two weeks after removal of the hydatid cyst, and no bronchial communication was seen. In those cases of persistent cavity in which repeated bronchograms were carried out no shrinkage in the size of the cavity was observed over several months.

The persistence of a pulmonary cavity after removal of a hydatid cyst and the coexistence of bronchiectasis are so frequent that the treatment of large single hydatid cysts by the methods described cannot be regarded as satisfactory. Lobectomy offers a greater likelihood of final freedom from symptoms, and also a shorter period of convalescence and surgical supervision.

Summary

1. An account is given of seven patients with hydatid disease of the lungs. One patient had a cyst in each lung.

2. One of the cysts was removed by a two-stage operation and the pericyst drained. Two of the cysts were believed to be infected, but organisms were grown from the pericyst in only one of them. The lung over these cysts was adherent to the chest wall, and after removal of the parasite the pericyst was drained.

The remaining five cysts were treated by removal after free thoracotomy. An attempt was made to obliterate, with catgut sutures, the pulmonary cavities remaining after removal of four of these cysts. The cavity left after removal of the fifth was closed.

3. After operation bronchograms were made in all cases. They showed persistence of the pulmonary cavities at various intervals after removal of five of the eight hydatid cysts.

4. The views are advanced that persistence of the residual cavity depends on failure of early closure of the bronchial fistula, and that lobectomy is the best treatment for large single hydatid cysts of the lung.

References

Barrett, N. R. (1947). *Thorax*, **2**, 21.

Christie, H. K. (1938). *Austral. New Zeal. J. Surg.*, **8**, 373.

Dew, H. R. (1928). "Hydatid Disease." Sydney. Australian Medical Publishing Co.

Lendon, A. A. (1902). "Hydatid Disease of the Lung." London.