Thorax (1973), **28**, 342.

Intraluminal pressure, transmucosal potential difference, and pH studies in the oesophagus of patients before and after Collis repair of a hiatal hernia

K. S. HABIBULLA and J. LEIGH COLLIS[1]

Oesophageal Laboratory, Queen Elizabeth Hospital, Birmingham

Intraluminal pressure, transmucosal potential difference, and endo-oesophageal pH measurements were studied in patients with hiatal hernia—before and after a hiatal repair. The operation employed is the Collis (1968) repair for uncomplicated hiatal hernia and does not refer to gastroplasty as recommended for peptic stricture (Collis, 1961). Postoperative studies show that the repair approximates the inferior oesophageal sphincter to the hiatus with the production of a single band of raised pressure at the lower end of the oesophagus. This band is similar to that seen in normal subjects and its appearance was associated with cure of the symptoms, abolition of the gastro-oesophageal reflux, and improvement in the function of the inferior oesophageal sphincter and the musculature of the body of the oesophagus. Certain physiological implications of this study are discussed.

One of us (Habibulla, 1972) has described how the high pressure band at the oesophagogastric junction has two parts, one being produced by the crural muscle of the diaphragm and the other by the inferior oesophageal sphincter. These two parts are spread out or separated in patients with hiatal hernia. Intraluminal pressure studies were carried out before and after reduction of the hiatal hernia by Collis (1968) repair.

MATERIAL AND METHODS

For this investigation 21 patients with simple hiatal hernia were prospectively studied before surgery. The tests were repeated six to 24 months afterwards. All initially had severe reflux symptoms. They have been referred from other hospitals in the area for surgery and in every case the possibility of obtaining relief by medical treatment had proved ineffective. The 21 patients were selected from a group of 31 treated surgically because they had a demonstrable disturbance of the motor function of the oesophagus. All had barium swallow examinations showing free gastro-oesophageal reflux. Oesophagoscopic assessment was made for all patients.

INTRALUMINAL PRESSURE STUDIES This was carried out as previously described by Woodward (1970) with patients supine. Two polyvinyl catheters were used with their openings 5 cm apart. They were infused constantly with water. The catheters were passed into the stomach and were then withdrawn 1 cm every 6 seconds approximately, while recording was continuous. The patients were given 3 to 5 ml of water and the response to swallows was then recorded in the lower 5 cm of the oesophagus.

Twelve to 35 swallows were recorded for each patient and the average height of the contraction developed was then interpreted as the contractile strength of the muscle of the oesophagus.

MEASUREMENT OF TRANSMUCOSAL POTENTIAL DIFFERENCE Simultaneous measurement of the transmucosal potential difference during the recordings of the intraluminal pressure provides a satisfactory method for the identification of the change of squamous epithelium to gastric mucosa. This technique has been described previously (Helm, Schlegel, Code, and Summerskill, 1965; Habibulla, 1972). Normally the transmucosal potential difference in the lumen of the stomach is negative with reference to the skin, while the potential difference in the lumen of the oesophagus is positive. Thus when an electrode is withdrawn from the stomach into the oesophagus there is a change in the polarity of the potential difference at the site of the oesophagogastric junction.

MEASUREMENT OF ENDO-OESOPHAGEAL pH This was measured by a glass pH electrode as has been described previously (Woodward, 1970).

[1]Reprints are obtainable from Professor J. Leigh Collis, Queen Elizabeth Hospital, Birmingham 15

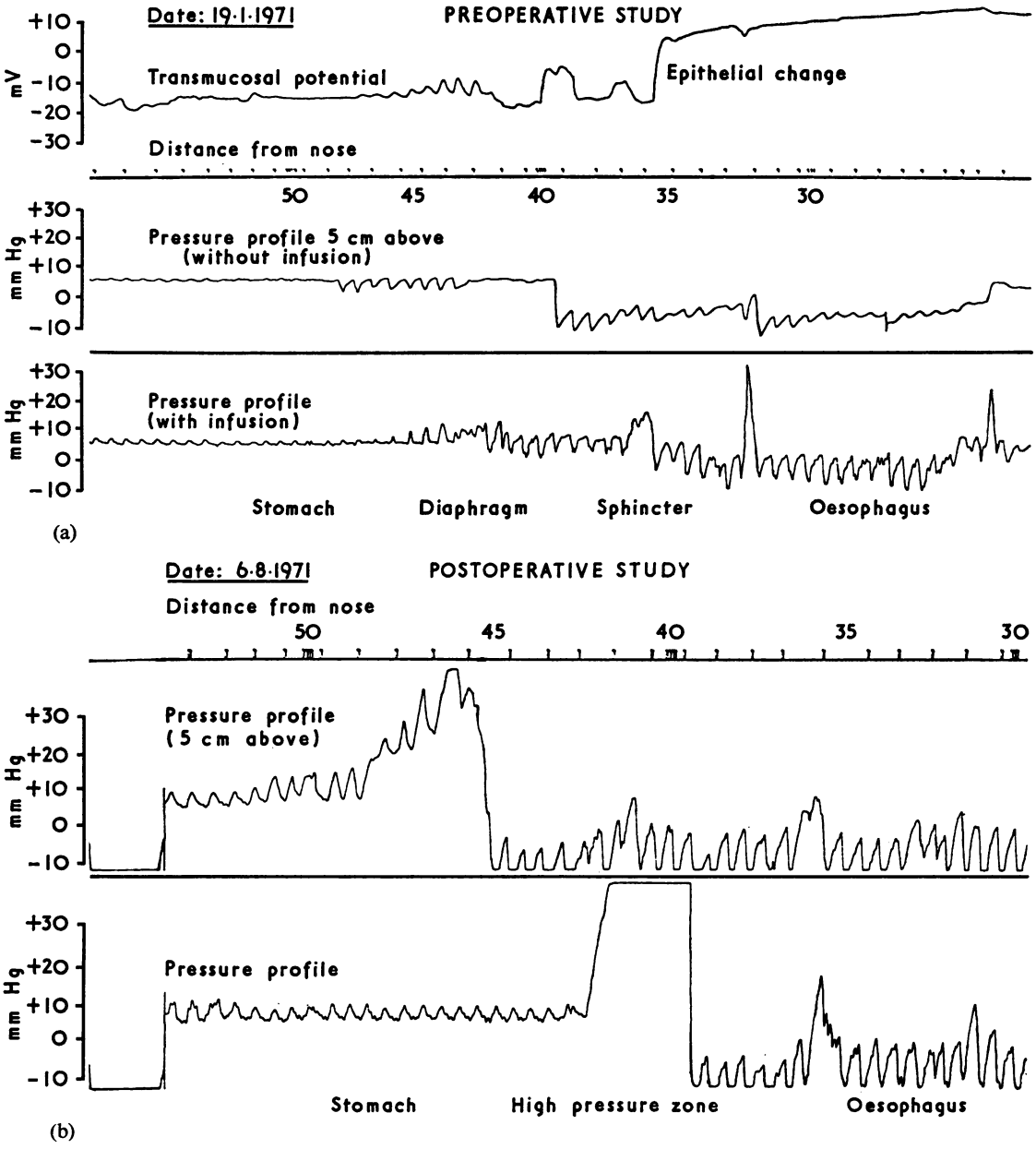

FIG. 1. (a) *Simultaneous recordings of the transmucosal potential difference (upper panel) and intraluminal resting pressures (middle and lower panels). The recordings of the upper and lower panels are at the same level and the distance from the external nares is indicated in centimetres by the scale on the upper line. The legends in the lower panel are for the lower pressure recording. Note the positive fundal (stomach) pressure and negative oesophageal pressure. Note also the thoracic displacement of the inferior oesophageal sphincter. The pressure recording in the middle panel is 5 cm proximal to the lower pressure recording and it was done with water-filled non-infused catheters to show the difference between infusion and non-infusion techniques.* (b) *The effect of surgery on the resting pressure recording at the oesophagogastric region in the same patient seven months after hiatal repair. The scale of distance on the upper line and the legends in the lower panel are for the lower pressure recording. Note a band of elevated pressure marked as 'high pressure zone' is now interposed between the stomach and oesophagus. Subsequent studies showed that this band contained sphincteric and crural pressure bands.*

RESULTS

All the 21 patients were asymptomatic at the time of postoperative review and had no radiological hiatal hernia.

INTRALUMINAL PRESSURE STUDIES (Figs. 1, 2, 3, 4, and 5)

Preoperative studies When the catheters were withdrawn from the stomach into the oesophagus through the herniated sac the pressure studies did not show the normal single band of raised pressure but the band was split into two parts. The mean distance between them was 4·4 (SE 0·3) cm. The part of the band of raised pressure responding to swallows (i.e., the sphincteric band) was displaced up in the chest. It had normal end expiratory pressure excess in four patients and in a further five patients it was low (i.e., less than 4 mmHg). The mean length of this band in these

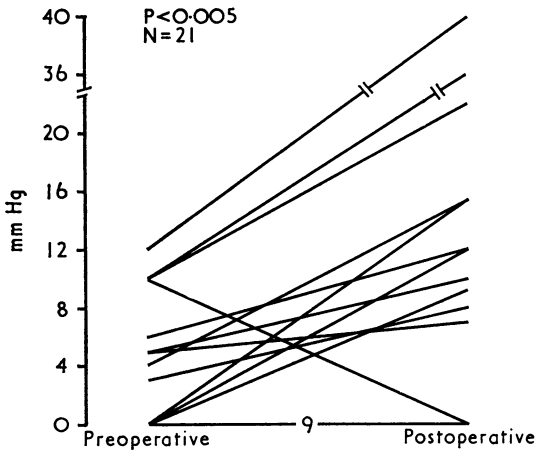

FIG. 2. *The effect of surgery on the mean end expiratory pressure excess of the sphincteric band of raised pressure. Note the significant improvement in 11 patients but none in nine patients. The general pattern is one of good recovery of the sphincter tone provided that some sphincter power was present preoperatively.*

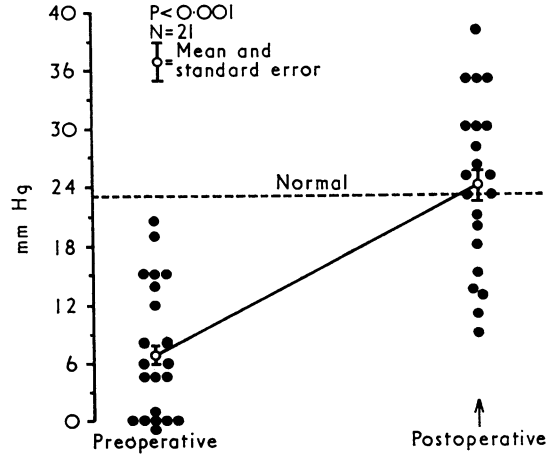

FIG. 3. *The effect of surgery on mean end inspiratory pressure excess of the crural band of raised pressure in hiatal hernia patients. There is a significant increase in the end inspiratory pressure. This is not unexpected on the basis of the principle of the Collis repair of a hiatal hernia. This graph may be accepted as demonstrating that pressure due to the portion of the lower oesophageal band which is produced by the diaphragm has been returned to a normal level.*

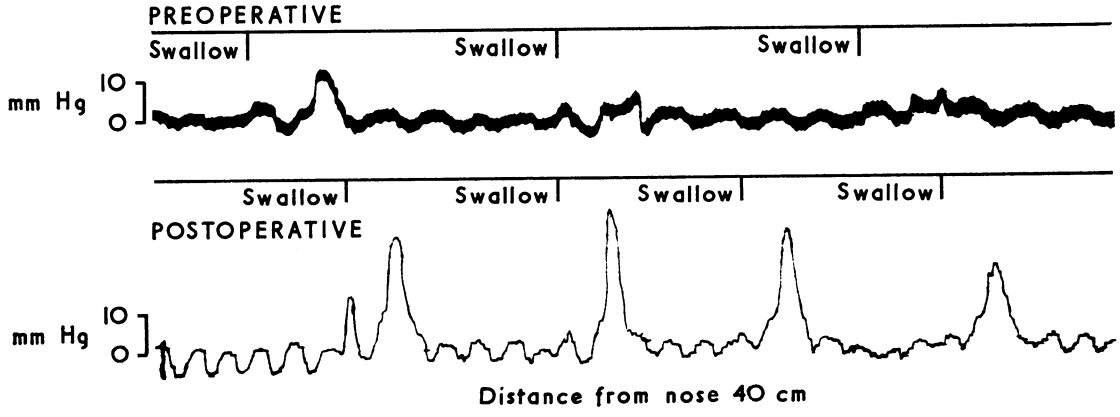

FIG. 4. *The effect of surgery on the contractile strength of the muscle of the oesophagus. The upper tracing was taken before surgery. It is a continuous pressure tracing from a catheter placed in the oesophagus 4 cm above the inferior oesophageal sphincter. The time of the onset of each swallow is shown in the upper line. Note slight elevation in the resting pressure produced by a wave of contraction after a swallow. The lower pressure recording was done in the same patient 18 months after hiatal repair. Note a significant rise in the height of contraction.*

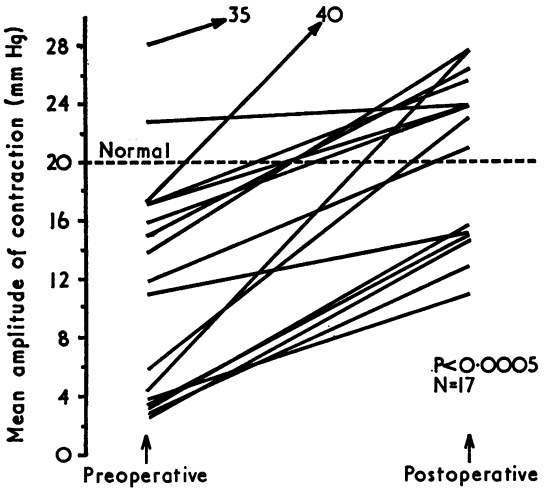

FIG. 5. *The effect of surgery on the contractile strength of the muscle of the oesophagus in* 17 *of the* 21 *hiatal hernia patients. These recordings relate to strength of muscle contraction within the oesophagus above the inferior oesophageal sphincter. All these patients showed improvement after the repair. This improvement was more marked when pressure was low before the operation.*

nine patients was 1·6 (SE 0·01) cm. The other part of the band of raised pressure responding to the deep voluntary inspiratory effort but not to swallows (i.e., crural pressure band) remained at the level of the hiatus. This was present in 14 patients. It recorded a mean end inspiratory pressure excess of 7·0 (SE 0·9) mmHg, a mean end expiratory pressure excess of 2·0 (SE 0·2) mmHg, and its length was 1·7 (SE 0·02) cm.

When the contractions to swallows in the lower 5 cm of the oesophagus were analysed the pressure tracings showed weak sequential contractions in 17 patients, non-sequential contractions in another two patients, and in the remaining two patients they showed spontaneous contractions.

Postoperative studies When the catheters were similarly withdrawn into the lower oesophagus a single band of raised pressure was seen at the repaired hiatus. The mean length of this band was 3·3 (SE 0·01) cm. It contained sphincteric as well as crural pressure bands. Analysis of the sphincteric band showed that the basal end expiratory pressure excess (=tone) was significantly ($P<0·001$) increased in eight of the nine patients who had a band preoperatively, but in contrast it appeared in only three of the 12 patients who had no band previously. The height of the crural band increased in all the patients. The mean end inspiratory pressure excess of this band was 24·2 (SE 1·9) mmHg, the mean end expiratory pressure excess was 7·2 (SE 1·0) mmHg, and the mean length of this band was 2·9 (SE 0·2) cm.

Swallows studied in the lower oesophagus showed that the amplitude of contraction improved significantly in all the 17 patients ($P<0·0005$). The synchronous contractions were replaced by progressive peristaltic contractions. The spontaneous contractions present in two patients disappeared completely.

TRANSMUCOSAL POTENTIAL DIFFERENCE STUDIES (Figs. 6 and 7) This was studied in 13 patients preoperatively and in 14 patients postoperatively. Before the operation the transitional zone of the

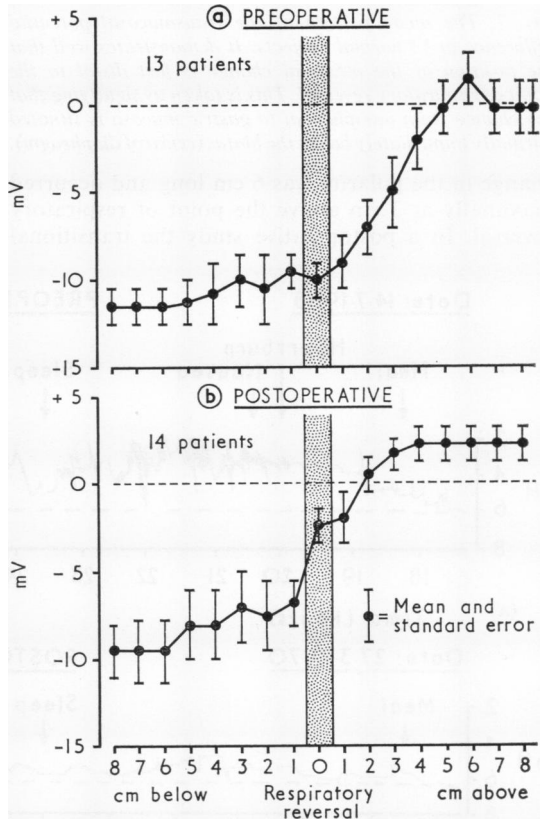

FIG. 6. (a) *The mean pattern of the transmucosal potential difference in the oesophagogastric region before operation. The mean position of the maximal change in polarity has been calculated to be* 3 *cm proximal to the point of respiratory reversal.* (b) *The mean pattern of the transmucosal potential difference after operation. The mean position of the maximal change in polarity is seen now to be below the point of respiratory reversal. This confirms the reduction of the hernia.*

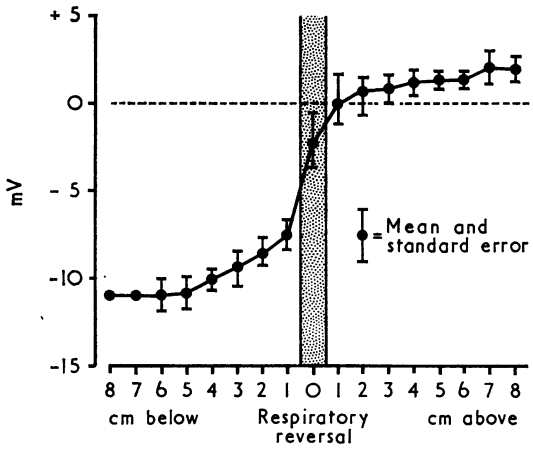

FIG. 7. *The mean pattern of the transmucosal potential difference in* 13 *normal subjects. It demonstrates well that the position of the maximal change is just distal to the point of respiratory reversal. This is taken as signifying that the change from oesophageal to gastric mucosa is situated normally immediately below the hiatus (crura of diaphragm).*

change in the polarity was 6 cm long and occurred maximally at 3 cm above the point of respiratory reversal. In a postoperative study the transitional zone shortened to 5 cm and the point of maximal change has shifted to the normal position below the point of respiratory reversal.

ASSESSMENT OF GASTRO-OESOPHAGEAL REFLUX (Figs. 8 and 9 and Table) Postoperative radiological studies have shown that the gastro-oesophageal reflux has been successfully controlled in all the patients. One patient had minimal reflux in the supine position but with good clearance. Endo-oesophageal pH studies showed that all patients refluxed frequently and for a longer

TABLE

SIGNIFICANCE OF GASTRO-OESOPHAGEAL REFLUX

		Mean	SE	
Frequency of reflux episodes				
	Preoperative	34	4·6	$t = 3·86$
	Postoperative	14	2·8	$P = < 0·0005$
Percentage time				
<pH 5	Preoperative	28·9	4·8	$t = 4·82$
	Postoperative	7	1·8	$P = < 0·0005$
<pH 4	Preoperative	14·6	4	$t = 3·0$
	Postoperative	2·9	0·9	$P = < 0·005$
<pH 3	Preoperative	3·5	0·9	$t = 3·1$
	Postoperative	0·5	0·2	$P = < 0·005$

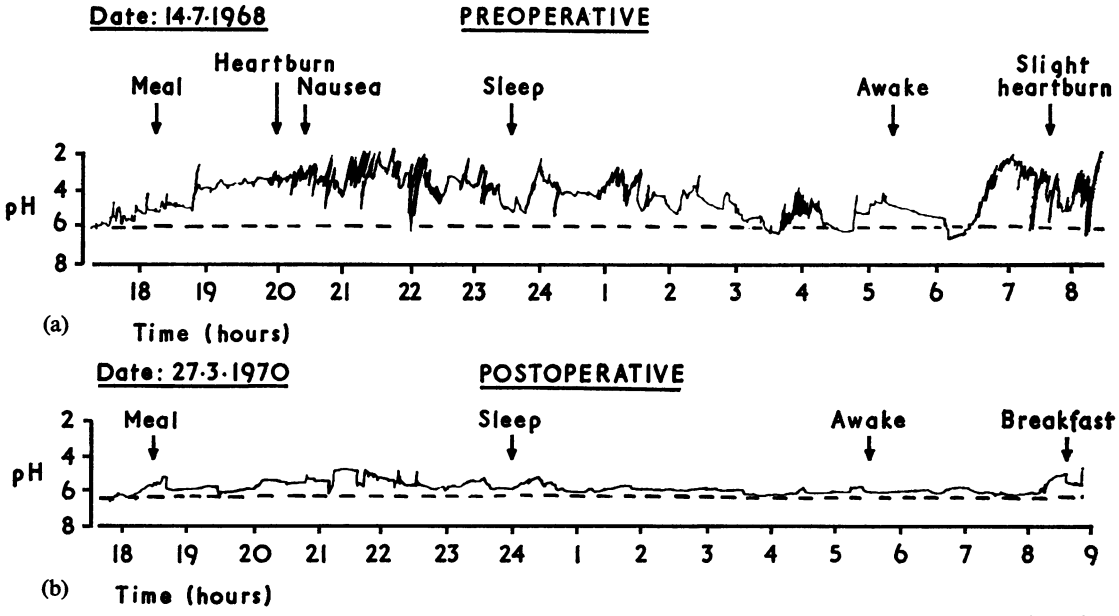

FIG. 8. (a) *Continuous recording of the endo-oesophageal pH in a hiatal hernia patient. The patient was supine throughout except at the time of meals. Note a marked elevation of the tracing from the normal basal pH, as indicated by the interrupted line. Each spike represents an episode of the gastro-oesophageal reflux. Note the poor correlation between the symptom and reflux. While patient was refluxing almost continuously, the complaints were made only for a few minutes.* (b) *Continuous recording of the endo-oesophageal pH in the same patient* 19 *months after operation. Note the basal pH is around pH* 6. *There are hardly any spikes of falling pH (the gastro-oesophageal reflux) even after a meal.*

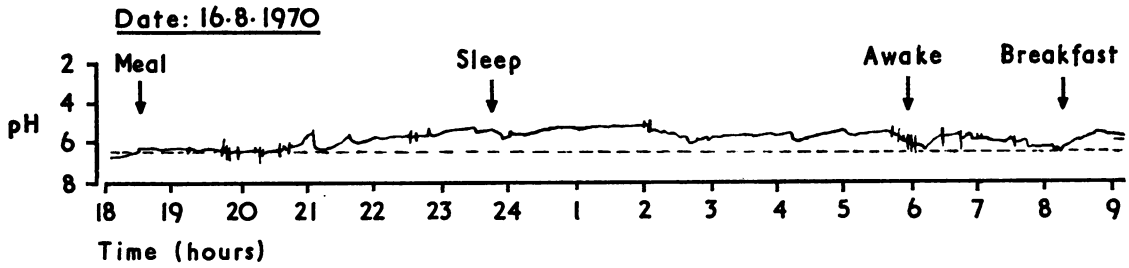

FIG. 9. *Continuous recording of the endo-oesophageal pH by the glass pH electrode in a control. Compare this with Fig. 8b.*

duration before the operation. The mean number of reflux episodes was 34 (SE 4·6) for the group and the mean percentage of the total duration of the test that the oesophageal pH remained under pH 5 was 28·9 (SE 4·8)%. In the postoperative study the frequency of the reflux episodes was reduced to 14 (SE 2·8) and the mean percentage of the duration of the test under pH 5 was also significantly reduced to 7 (SE 1·8)%.

DISCUSSION

One aim of the Collis operation for hiatal repair is to site the inferior oesophageal sphincter at the level of the diaphragmatic hiatus on the assumption that this allows more normal function. This siting of the inferior oesophageal sphincter was shown by radiology to have been effected and was confirmed by a shift of the slope of the curve of transmucosal potential difference (i.e., oesophagogastric junction) towards the point of respiratory reversal (i.e., diaphragmatic hiatus).

Postoperative intraluminal pressure studies show the emergence of a single band of raised pressure at the hiatus incorporating the inferior oesophageal sphincter. Since these patients were symptom and reflux free when assessed clinically, radiologically, and by endo-oesophageal pH measurements, it is likely that the band of raised pressure takes a part in preventing reflux. Further confirmation comes from the similarity of this band of raised pressure with that seen in normal controls.

The effect of producing surgically this single band of raised pressure as an anti-reflux barrier is also reflected by the improvement in the contractile strength of the body of the oesophagus ($P<0·001$) and the function of the inferior oesophageal sphincter ($P<0·005$). The improvement in the oesophageal musculature is believed to be due to the removal of the irritating effects of gastric reflux. A similar hypothesis can be postulated for the improved tone in the inferior oesophageal sphincter. Improvement in the tone of the sphincter after surgery has also been reported by Lind, Burns, and MacDougall (1965) and by Skinner and Booth (1970). In our study the improvement was most marked when the sphincteric tone was subnormal ($P<0·0005$) in contrast to the unsatisfactory findings when the sphincteric tone was absent preoperatively.

The physiological implications of this study are that the inferior oesophageal sphincter is not alone responsible for antireflux mechanisms, and that an elevated pressure band produced by the crural muscle also makes a contribution to reflux control. This effect is best when the two pressure bands are at the same level. These studies are contrary to the views of Cohen and Harris (1971) and support the widely accepted views of Edwards (1971) and of the leader in the *British Medical Journal* (1971) that some other mechanism besides the inferior oesophageal sphincter is responsible for the prevention of reflux. The surgical implications of this study are that Collis's repair is effective in the prevention of reflux.

CONCLUSION

Late postoperative intraluminal pressure studies were carried out in a selected group of patients with hiatal hernia with motor abnormality in the oesophagus. These studies showed the reappearance of a single band of raised pressure at the lower end of the oesophagus. This band of raised pressure was identical with the raised pressure band in normals.

With the production of this band, the patients became symptom free and reflux was reduced. The contractile strength of the musculature of the body of the oesophagus and the inferior oesophageal sphincter returned towards normality.

We are most grateful to Mr. D. A. K. Woodward, consultant surgeon, Walsgrave Hospital, Coventry for

allowing us to include some of his unpublished work. We are also very indebted to Mr. Tom Dee, chief clinical photographer, Queen Elizabeth Hospital and to Miss P. Cole of the Surgical Research Wing for the diagrams, Mr. D. H. Berer of the Department of Medicine for statistical advice and help, and our own secretary, Mrs. Mary T. Noakes, for secretarial help.

This study was supported by grants from the Endowment Fund of the United Birmingham Hospitals.

REFERENCES

Cohen, S., and Harris, L. D. (1971). Does hiatus hernia affect competence of the gastroesophageal sphincter? *New Engl. J. Med.*, **284**, 1053.

Collis, J. L. (1961). Gastroplasty. *Thorax*, **16**, 197.

— (1968). Surgical control of reflux in hiatus hernia. *Amer. J. Surg.*, **115**, 465.

Edwards, D. A. W. (1971). The oesophagus—progress report. *Gut*, **12**, 948.

Habibulla, K. S. (1972). The diaphragm as an anti-reflux barrier—a manometric, oesophagoscopic and transmucosal potential study. *Thorax*, **27**, 692.

Helm, W. J., Schlegel, J. F., Code, C. F., and Summerskill, W. H. J. (1965). Identification of the gastroesophageal mucosal junction by transmucosal potential in healthy subjects and patients with hiatal hernia. *Gastroenterology*, **48**, 25.

Leading article (1971). Reflux and hernia. *Brit. med. J.*, **3**, 205.

Lind, J. F., Burns, C. M., and MacDougall, J. T. (1965). Physiological repair for hiatus hernia—manometric study. *Arch. Surg.*, **91**, 233.

Skinner, D. B., and Booth, D. J. (1970). Assessment of distal esophageal function in patients with hiatal hernia and/or gastroesophageal reflux. *Ann. Surg.*, **172**, 627.

Woodward, D. A. K. (1970). Response of the gullet to gastric reflux in patients with hiatus hernia and oesophagitis. *Thorax*, **25**, 459.