Thorax (1962), **17**, 5.

CHRONIC BRONCHITIS: RADIOLOGICAL ASPECTS OF A FIVE-YEAR FOLLOW-UP

BY

G. SIMON AND V. C. MEDVEI

From the Brompton and St. Bartholomew's Hospitals and H.M. Treasury, London

(RECEIVED FOR PUBLICATION JUNE 28, 1961)

The radiographs of only 299 of the 312 patients with a clinical diagnosis of chronic bronchitis surveyed by Medvei and Oswald (on page 1) were available for review. Thirteen unselected cases are missing, which accounts for certain small differences in the figures from those given by these authors. The patients were divided into three groups on the basis of the radiographic appearances.

The first group, consisting of 177 or 59% of all the patients, were those with a normal chest radiograph. Included in this group were a few showing calcified or stellate small shadows, suggesting an old tuberculous and presumably quiescent lesion, or some other type of shadow, the probable cause of which seemed to be neither an active lesion nor a lesion related in any way to the chronic bronchitis or the clinical course.

The second group, consisting of 35 or 12% of all the patients, were those in whom the radiograph showed evidence of local emphysema. This was diagnosed when a single and localized avascular translucent area was seen, which was either clearly demarcated by a hair-line shadow, suggesting a bulla, or was poorly demarcated, suggesting a bullous area. In either case there were no other radiographic abnormalities and therefore no radiological evidence of general emphysema. In most of the following tables this group is joined to the first group having a normal chest radiograph.

The third group, consisting of 87 or 29% of the 299 patients, were those with obvious radiographic evidence of general emphysema. The criteria for this were evidence of diaphragmatic change suggesting an excess of air in the lungs, a changed cardiovascular pattern, and localized overdistension, three conditions which commonly result from the grosser pathological changes of emphysema and which have been described by Simon and Galbraith (1953), Simon (1956), and Lynne Reid and Simon (1959).

In order that there may be no misunderstanding about the basis on which the diagnosis of emphysema was made, the criteria used are described in detail.

CRITERIA USED FOR DIAGNOSIS OF EMPHYSEMA

1. EVIDENCE OF EXCESS OF AIR IN THE LUNGS.—An excess of air in the lungs may be inferred if the diaphragm is low and flat. It was judged to be low either by a subjective impression of the length of the thorax in relation to its width, or if it lay below the anterior end of the right seventh rib. It was considered flat if there was no even and obvious superior convex curvature. Each flattened dome either extended more or less horizontally across or sloped some 20° downwards and outwards. The flattening was sometimes most obvious in a lateral view, with the diaphragm running horizontally from the front to the back of the chest.

If a lateral view was available, an excess of air was also inferred if the retrosternal translucent area was very large. This was judged subjectively and no measurements were taken. Any curvature of the sternum or gross kyphosis was taken into account.

In some cases a radiograph taken on deep expiration was also available, and air trapping was inferred if the range of diaphragm movement was less than 3 cm. (Measurement of the range of movement in a control group of normal males up to the age of 60 showed a range of 3 to 10 cm.) Local air trapping was also inferred if some parts of the lung remained relatively translucent in the radiograph taken on expiration when adjacent and presumably normal parts became relatively opaque. In this particular series of cases, a radiograph on expiration was only taken if there was some doubt about the diagnosis.

2. CHANGES IN CARDIOVASCULAR PATTERN.—In emphysema the heart tends to be narrow and vertical, partly due to the low position of the

diaphragm. It was judged narrow if the transverse diameter was less than 11 cm. or the cardiothoracic ratio less than about 40%.

The left border below the aortic knuckle, representing the main trunk of the pulmonary artery, is either straight or convex laterally. This may be due in part to the rotation of the heart, resulting from its more vertical position, and in part to dilatation of the pulmonary artery.

The hilar vessels seem large and appear to extend further laterally than normally while the intrapulmonary vessels seem unduly small and narrow. This may be a subjective impression, but some confirmation was obtained in a few cases by direct measurements in tomograms and comparison with tomograms of apparently normal persons.

3. LOCALIZED OVERDISTENSION. — Localized overdistension, that is, a bulla, may be of sufficient degree to appear as a hypertranslucent avascular area.

When all three signs were present, a diagnosis of general emphysema was made, but it was also made even in the absence of obvious bullae if the other two signs were clearly seen. In this survey the diagnosis of general emphysema was only made when the above-mentioned changes were obvious, and if there was any doubt the radiograph for the purpose of the grouping was considered normal. Because of this, and also because the findings were recorded individually on a special form, there was no observer error when the radiographs were read a second time.

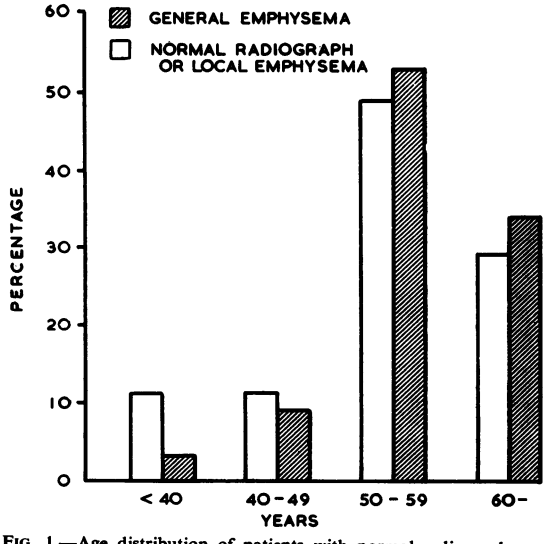

FIG. 1.—Age distribution of patients with normal radiographs or local emphysema compared with patients with general emphysema.

RADIOGRAPHIC APPEARANCES IN RELATION TO AGE OF PATIENT WHEN FIRST SEEN

Fig. 1 compares the ages of the patients with a normal radiograph, or with local emphysema only, to those of the patients with radiographic evidence of general emphysema. As was to be expected, there is a relative deficiency of patients under 40 with evidence of general emphysema, but in the over-40 age groups the differences are so slight that the two groups can be considered comparable. Fuller details of the ages are given in Table I.

TABLE I
RADIOLOGICAL DIAGNOSIS AND AGE

	Total	Age (Years)			
		<40	40–	50–	60–
Normal radiograph	177	22	23	81	51
Local emphysema	35	1	1	23	10
General ,,	87	3	8	46	30

RADIOGRAPHIC APPEARANCES IN RELATION TO MORTALITY

Table II shows the mortality in relation to the three groups of radiological appearances. It is a very striking finding that 53% of those showing general emphysema died within five years, whereas only 21% of those with local emphysema or a normal chest radiograph had died in the same period.

TABLE II
FIVE-YEAR MORTALITY

	No. of Cases	Dead Within 5 Years
Normal radiograph ..	177	38 (21%)
Local emphysema ..	35	7 (20%)
General emphysema:		
With bullae	33 } 87	24 } 46 (73 } 53%)
Without ,, ...	54	22

ANALYSIS OF CAUSES OF DEATH IN TWO MAIN GROUPS

An analysis of the causes of death is given in Table III. The data recorded in the Registrar-General's certificates, or our interpretation of them, may of course be inaccurate, but this table does suggest that the majority of the patients with general emphysema died of respiratory insufficiency, whereas the majority of those with a normal radiograph, or with evidence of local emphysema only, died of non-pulmonary causes, such as a malignant neoplasm, a cerebral vascular disaster, or a cardiac infarction.

TABLE III
CAUSES OF DEATH

	Total Deaths	Cause of Death*			
		Cardio-respiratory (No.)	Respiratory Infection (No.)	Other Diseases (No.)	Not Known (No.)
Normal radiograph or local emphysema	45	9	9	25	2
General emphysema	46	29	3	13	1

* Personal assessment: subject to considerable inaccuracy due to misinterpretation of the wording of the death certificates.

RELATION OF AGE TO MORTALITY IN TWO GROUPS

In the middle age group the mortality was very much higher in those with general emphysema than in those with a normal radiograph. In the former, of the 54 patients between the ages of 40 and 59, over half (60%) were dead within the five-year period compared with only 13% of the 128 patients with a normal radiograph in the same age group. The details are given in Table IV.

TABLE IV
FIVE-YEAR MORTALITY BY AGE

Age (yr.)	Normal Radiograph or Local Emphysema		Generalized Emphysema	
	No. of Patients	Deaths	No. of Patients	Deaths
<40	23	1	3	—
40–49	24	2 } (13·5%)	8	5 } (60%)
50–59	104	14	46	28
60–	61	28 (46%)	30	13 (43%)
Total ..	212	45 (21%)	87	46 (53%)

There was only one death in the patients under 40, and this man had a normal radiograph. The cause of death is unknown.

BULLAE IN CHRONIC BRONCHITIS WITH COMPLICATING EMPHYSEMA

Table II shows an incidence of about one third of obvious bullae in the 87 patients with gross radiological evidence of general emphysema. The mortality in the five-year period was 73% in those with obvious bullae, compared with 41% in those without obvious bullae. This suggests that radiological evidence of general emphysema carries a worse prognosis if obvious bullae are present than if they are not.

AMOUNT AND CHARACTER OF SPUTUM ON ENTRY INTO SERIES

Table V shows that generalized emphysema in the radiograph is associated not only with a greater volume of sputum but also with a higher proportion of patients having purulent sputum. However, within the emphysema group itself purulent sputum was less common in patients with obvious bullae than in those without. The difficulties of obtaining an accurate sputum history were recognized.

TABLE V
AMOUNT AND TYPE OF SPUTUM FROM HISTORY AT INITIAL INTERVIEW (WINTER AVERAGE AMOUNT)

	No. of Cases	Amount of Sputum				Type of Sputum	
		1 oz. (%)	1–2 oz. (%)	2–3 oz. (%)	3 oz. (%)	Mucoid (%)	Purulent (%)
Normal radiograph or local emphysema	200	34	43	11	12	77	23
General emphysema	85	19	45	14	22	62	38

* Excludes 14 cases in which some of sputum may have come from lesions additional to chronic bronchitis.

DURATION OF MAIN SYMPTOMS

There was no consistent pattern relating the duration of the symptoms to the radiological appearances. Many with general emphysema and with a normal chest radiograph had a history of less than two years, and many in both groups had a history of cough, sputum, and dyspnoea for 20 years or more.

SEVERITY OF DYSPNOEA

On comparing the severity of dyspnoea, assessed from the history at the initial interview, with the radiographic findings, those with a general emphysema pattern showed a higher percentage graded as severe dyspnoea than those with a normal radiograph (Table VI).

TABLE VI
SEVERITY OF DYSPNOEA AT INITIAL INTERVIEW

	No. of Cases*	Grade of Dyspnoea			
		1 (%)	2 (%)	3 (%)	4 (%)
Normal radiograph or local emphysema	199	49	31	17	3
General emphysema	86	29	37	29	5

* Excludes 14 cases with severity not known.

In the group showing the general emphysema pattern, there were more patients with severe dyspnoea among those with obvious bullae, 43% being in grades 3 and 4 compared with only 37% of those with no bullae.

Alterations in Radiological Appearances During Five-year Period

There was not a single case showing any significant alteration in the chest radiograph between the initial film and that taken five years later. Those with a normal appearance in the initial radiograph were still normal five years later, and none developed an emphysema pattern.

Three of the normal and five of those showing general emphysema showed an increase in the transverse diameter of the heart, the former because of systemic hypertension, the latter because of the development of cor pulmonale and failure.

Many of those who died had one or more radiographs taken between the initial one and the time they died, and in none of these patients did such an intervening radiograph show any significant change.

The lack of change in the radiological appearances over a period of time up to five years was in marked contrast to the clinical findings. Of those who survived five years, that is, 167 in the normal or local emphysema group, 46 (28%) showed clinical deterioration compared with 18 (44%) of the 41 survivors in the general emphysema group. Twenty-eight in the normal group were better clinically, but only five in the general emphysema group.

Relation to Allergy or Previous Pneumonia

Some 10% of the patients with a normal radiograph and 11% of those with general emphysema had a history of allergic attacks, mainly asthma or hay fever.

Those with a normal chest radiograph showed a slight increase of pneumonic incidents in adult life compared with those with general emphysema, but the difference was not significant.

The incidence of pneumonia in childhood was about the same in the two groups.

Conclusions

In patients with a clinical diagnosis of chronic bronchitis a radiological appearance of general emphysema was of serious import, half such patients, compared with less than a quarter with a normal radiograph, being dead within a five-year period of observation. Furthermore, the deaths in the general emphysema group were mainly of patients under 60 at the commencement of the trial, whereas the deaths in those with a normal chest film were mainly of patients over 60 with a correspondingly smaller expectation of life.

The prognosis seemed to be worse in patients with obvious bullae than in those without this radiological appearance.

Our thanks are due to Mr. P. Curwen and the Department of Medical Statistics, St. Bartholomew's Hospital. for help with the tables.

References

Medvei, V. C., and Oswald, N. C. (1961). *Thorax*, **17**, 1.
Reid, Lynne, and Simon, G. (1959). *Brit. J. Radiol.*, **32**, 291.
Simon, G. (1956). *Principles of Chest X-ray Diagnosis*. Butterworth, London.
—— and Galbraith, H. J. B. (1953). *Lancet*, **2**, 850.