

## ACUTE DISSEMINATED HISTOPLASMOSIS OF PULMONARY ORIGIN PROBABLY CONTRACTED IN BRITAIN

BY

A. A. MILLER, F. RAMSDEN, AND M. R. GEAKE

*From the Group Laboratory, Preston Royal Infirmary, and Sharoe Green Hospital, Preston*

(RECEIVED FOR PUBLICATION NOVEMBER 28, 1960)

Histoplasmosis in any form is an unusual finding in Great Britain. The case described in this paper is that of a man with bilateral pulmonary histoplasmosis which terminated with an acute disseminated infection. It is believed to be an example of an indigenous British infection.

Symmers (1956) made a critical analysis of the 15 cases of histoplasmosis reported in Great Britain up to 1956 and found two of them (Limerick, 1951) unacceptable as there was insufficient evidence to warrant the diagnosis of histoplasmosis. Earle, Highman, and Lockley (1960) described a fatal case of acute disseminated histoplasmosis in a man aged 62 years who had lived in India for 30 years and contracted the disease in that country. Including the case described here, the total number of authenticated reported cases in Great Britain is 15, of which five show the acute disseminated form. Among the British reports, pulmonary lesions were noted in those of Arblaster (1950), of Crofton (first and second cases, 1950), of Sakula (1953), and of Leigh and Thomas (1955).

In the United States of America, where histoplasmosis is now well recognized, pulmonary lesions are not uncommon. Darling (1906), in his original paper, described "foci of catarrhal pneumonia and haemorrhages in the lungs": there were extensive granulomata surrounded by haemorrhagic lesions and the pulmonary lesions sometimes simulated miliary tuberculosis. Since then Meleney (1940) reviewed 32 cases of histoplasmosis of which seven had pulmonary lesions; Hodgson, Weed, and Clagett (1951) in a review of the American literature found 138 cases of authenticated histoplasmic infection of which 65 had proven pulmonary involvement. Monroe and Kurung (1953) reported one case of chronic upper lobe pulmonary histoplasmosis in an adult male which showed a mixed bronchopneumonic and cavitary pattern. Bronson and Schwarz (1957)

made a comprehensive study of the varied radiological appearances in 28 cases of histoplasmosis; of these cases nine showed pulmonary involvement. Furcolow (1960) indicates that at least 30% of positive skin test reactors have, or develop, demonstrable lesions.

### INDIGENOUS INFECTIONS

The first unequivocal, mycologically proved instance of histoplasmosis in which the infection was contracted in Britain is believed to be that reported by Symmers (1956) and was a case of histoplasmic lymphadenitis.

In the case described here the patient had never been outside Great Britain except during the period January, 1915, to February, 1916, when he served in the Dardanelles during the 1914-18 war. Occasional cases of histoplasmosis have occurred in Turkey, but we have no information about its incidence on the coast of the Dardanelles.

It would appear unlikely that the infection was contracted during this remote period of his life. In the American literature Parsons and Zafonitis (1945) stated that in 71 reviewed cases of histoplasmosis death occurred in a few weeks, months, or rarely years, after infection. Monroe and Kurung (1953) suggest that infection "may exist as a chronic illness for years and then an exacerbation may occur and prove fatal," and Furcolow (1960) states that in chronic pulmonary histoplasmosis the duration of illness may be as long as 20 years, depending on the rapidity of progress of the disease. In the case reported here there is no history of long-standing progressive chronic respiratory illness with exacerbations and remissions, and it appears unlikely that the histoplasmic infection lay dormant for 40 years and then recurred. Symmers (1960) suggested that it was far more likely that the infection was contracted in this country, possibly at the patient's workplace.

## MEDICAL HISTORY AND INVESTIGATIONS

A man (F. G.), aged 61, was first seen by one of us (M. R. G.) in May, 1957, when he gave a history of ill-health of about four months' duration. The main features were weight loss, breathlessness, and a cough productive of large quantities of whitish sputum.

He had had no significant past illness, but, on a number of occasions during the previous 18 months, he had been in contact with his son-in-law, who had active pulmonary tuberculosis.

On examination he was a thin, ill man, breathless on any slight exertion; there was no finger clubbing or enlargement of the systemic lymph nodes. There was no skin lesion. The physical signs were confined to the respiratory system and consisted of coarse and medium crepitations which were present over the upper and mid-chest anteriorly and posteriorly.

Chest radiography showed patchy mottling in the right upper zone, very dense mottling in the right mid zone and less extensive but similar patchy mottling in the left upper and mid zones. The basal areas both appeared emphysematous (Fig. 1). Tomography of both lung fields showed no evidence of cavitation. A Mantoux test was positive at one tuberculin unit.

At this stage we thought that he almost certainly had pulmonary tuberculosis, but during the next two weeks numerous sputum examinations were negative for tubercle bacilli on concentration and subsequently proved to be negative on culture and animal inoculation. His sputum was examined for malignant cells and for fungi with negative results, though the

necessary special techniques for demonstrating *Histoplasma* species were not used, as this diagnosis was not considered at that time.

Bronchoscopy was performed on two occasions; no abnormality was seen. Plasma proteins (Kjeldahl and electrophoresis) were: Total 7.3 g.%, albumin 2.6 g.%, globulin 4.7 g.%, A.G. ratio 0.6.

A barium swallow was normal and an extensive search for a non-pulmonary primary growth yielded nothing informative.

He was treated as a case of chronic bacterial pneumonia with various antibiotics and physiotherapy, but no form of therapy altered the relentless deterioration in his clinical and radiological course. He became more and more wasted until he died on July 12, 1957.

## FAMILY HISTORY AND INVESTIGATIONS

Nineteen members of the deceased's family were examined radiologically, by the histoplasmin skin test, and for histoplasma antibodies in the serum.

All the tests for histoplasmosis were negative and in 16 cases the lung fields showed no abnormality. The son-in-law, who lived in a separate house from the deceased, had active pulmonary tuberculosis; two of his children showed opacities in the lung fields and were considered to have healed tuberculous lesions.

## INDUSTRIAL HISTORY AND INVESTIGATIONS

The deceased had worked as a yard man at a local cotton mill from March, 1956, until May, 1957: during the latter part of this period he had been absent from work six to eight weeks with chest trouble. A large part of his work involved sweeping and cleaning the shed in which the cotton bales were opened and split for feeding into the cotton cleaning machine: he also helped to remove trash and cotton waste from this machine. During the seven years up to 1956 he had been employed as a cloth warehouseman at another mill. Before 1949 he worked in an engineering factory.

Eight other men who worked in the cotton cleaning area were examined for antibodies to histoplasmosis. Two of them gave positive histoplasmin skin tests but collodion agglutination tests were negative. Radiological examinations of the chest gave negative results.

Three samples of cotton from the mill, two American and one Nigerian, were cultured for long periods, using 1% glucose broth and Sabouraud's agar, but *Histoplasma* sp. was not isolated.

## NECROPSY

Necropsy was performed 24 hours after death. External examination showed a spare-built man with marked wasting of the trunk and limbs.

Internally the main significant findings were in the chest and abdomen. The pharynx, larynx, and main bronchi showed moist mucosa without granulomatous lesions. The right pleural cavity contained massive turbid effusion with flakes of fibrin. Both lungs were enlarged, the right lung weighing 820 g. and the left

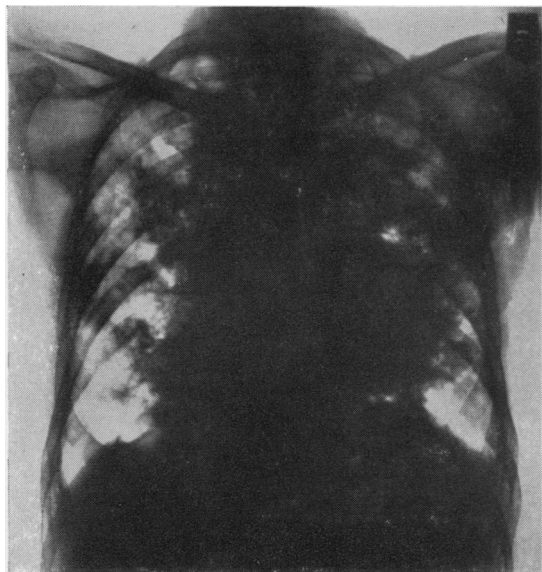


FIG. 1.—Chest radiograph showing patchy mottling in the right upper zone, dense mottling in the right mid zone, and less extensive similar patchy mottling in the left upper and mid zones. Basal areas appear emphysematous.

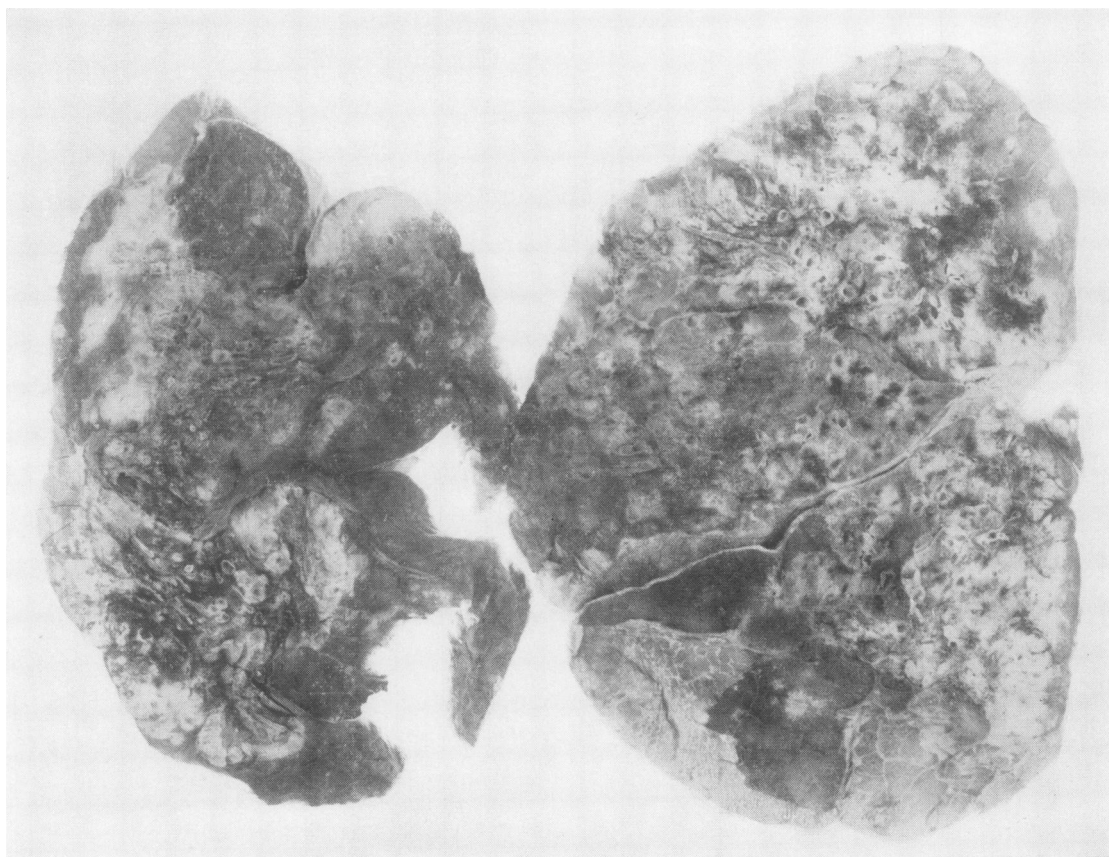


FIG. 2.—Mounted specimen of lungs, both showing infiltration by tumour-like nodules and white fluffy patches, peripheral emphysema and rigid thickened walls of bronchi and bronchioles.

800 g. The left pleural surfaces were smooth, moist, and whitish and thickened over the lower lobes. The right visceral pleura was thickened and showed the granular shaggy appearances of acute pleurisy: on the lower lateral aspect there were several large, firm, yellow plaques. Along the free borders of both lungs there were prominent emphysematous bullae. Enlarged lymph nodes were found on both sides of the upper mediastinum and at the hilum: they were discrete and rubbery in consistency.

The cut surfaces of the lungs showed unusual appearances (Fig. 2). The medullary parts were largely replaced by poorly circumscribed whitish masses, which suggested tumour or granulomata: the masses were surrounded or separated by spongy haemorrhagic zones. In the hilar regions there was diffuse fibrosis with black pigmentation; the rigid thickened walls of the cut bronchi stood out prominently. On the periphery of both lungs there was a scattering of miliary and larger whitish nodules surrounded by emphysema and also larger areas of subpleural

emphysema. The naked-eye appearances suggested granuloma, or possibly neoplasia, with considerable fibrosis.

The right adrenal gland was small, weighed 6 g., and was almost replaced by white tumour-like tissue: on the periphery there was a rim of yellow cortex. The left adrenal gland appeared normal.

The prostate gland weighed 50 g. and its substance showed adenomatous masses and whitish tumour-like tissue similar to that seen in the right adrenal gland.

There was no apparent lesion in the intestinal tract and no peritoneal exudate. Liver, spleen, meninges, and brain substance showed no gross abnormality.

The cause of death was circulatory and respiratory failure due to chronic destructive disease of the lungs with terminal acute exacerbation.

#### HISTOLOGY

**NATURE OF LESION.**—In the lung parenchyma there was patchy infiltration by large granulomatous masses (Fig. 3). These consisted of dense acellular



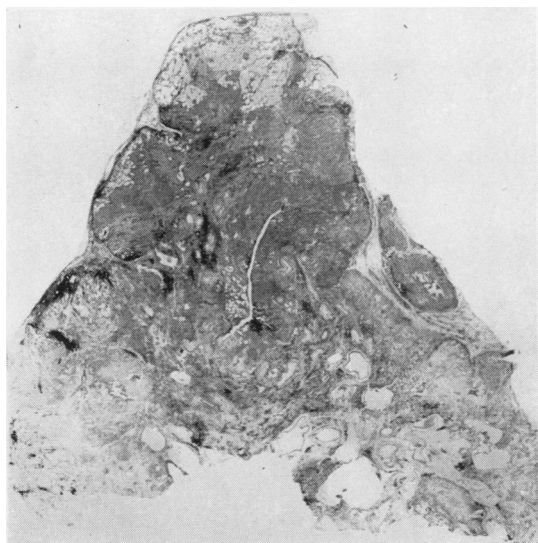


FIG. 3.—A giant section of the upper lobe in the perihilar region showing dense fibrosis, granulomatous masses replacing most of the parenchyma; also peripheral emphysema. Haematoxylin and eosin,  $\times 3$ .

collagenous tissue, fibrous stroma containing plasma cells, lymphocytes, and polymorphs, numerous large parasitized phagocytes, and poorly defined follicular aggregates, some of which resembled miliary tubercles. Parts of the lesion could be called "granulomatous pseudo-tubercles" (Humphrey, 1940, quoted by Tager and Liebow, 1942). There were areas of confluent bronchopneumonia with considerable cell necrosis and nuclear debris. The main blood vessels showed marked endarteritis obliterans. At the hilum of both lungs there was marked diffuse fibrosis with much black pigment in the stroma. On the lung periphery subpleural emphysema was a marked feature. The alveolar walls were thickened; around some of the bronchioles and blood vessels there were small focal areas of fibrosis. The visceral pleura was greatly thickened, acellular, and collagenous.

In the hilar lymph nodes the granulomatous pseudo-tuberculous appearances were prominent and necrosis was minimal (Fig. 4).

The suprarenal gland showed considerable caseation necrosis. The prostate showed the unusual appearances of the cystic glands distended with exudate which contained numerous phagocytes containing parasites. The spleen showed no evidence of histoplasmic lesions.

The overall microscopical appearances in the lungs suggested that the lesion, which showed a high collagen content and low vascularity with severe endarteritis obliterans, was of some duration. In the suprarenal gland and the prostate, the amount of caseation and cell necrosis indicated an advanced stage of the disease.

**CELLS CONTAINING PARASITES.**—Paraffin sections of the lungs, hilar lymph nodes, suprarenal and prostate glands were prepared and stained with haematoxylin and eosin. In almost every microscopical field the most prominent and conspicuous feature was the presence of large multinucleated macrophages of the reticulo-endothelial type containing parasites (Fig. 5). These infected macrophages were present in all components of the granuloma, in the pneumonic exudate, inside the thick-walled bronchi and bronchioles, and in the hyperplastic cystic glands of the prostate. They contain single and multiple, dark-staining, rounded bodies, each surrounded by an unstained cell wall or halo (Fig. 6). The number of parasites was large and in some instances there were as many as 10 organisms in one healthy macrophage: they were mainly intracellular, a few were found in epithelioid histiocytes and occasional ones in tissue spaces. With the use of the common stains such as haematoxylin and eosin the parasites stained feebly. The results were better with Gram's stain and a modified Ziehl-Neelsen method (Figs. 7 and 8), but the best effects were obtained by the use of periodic-acid-Schiff (Fig. 9), Gridley's modification of the chromic-acid-Schiff reaction, and also Gomori's chromic-acid-methenamine-silver reaction. With the three latter methods

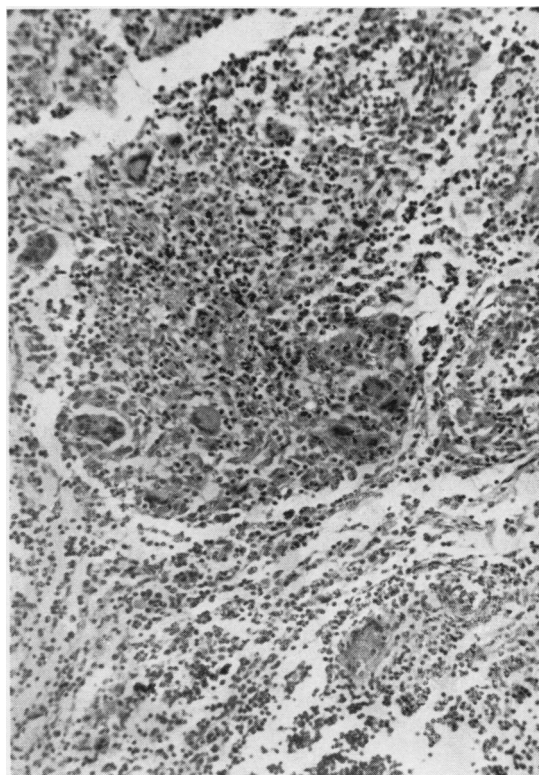


FIG. 4.—Section of hilar lymph node showing follicular aggregates with giant cells containing parasites. Haematoxylin and eosin,  $\times 130$ .



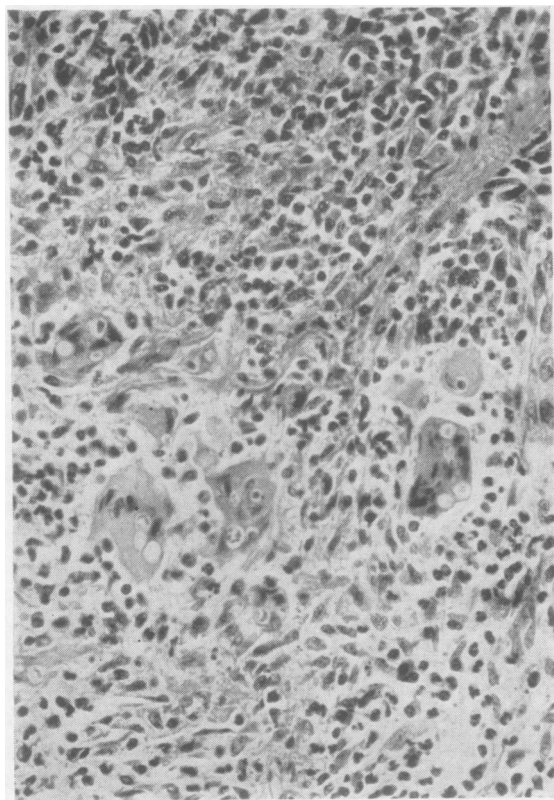


FIG. 5.—A lung field showing granulomatous lesion with inflammatory exudate and many macrophages heavily contaminated with parasites. Haematoxylin and eosin,  $\times 250$ .

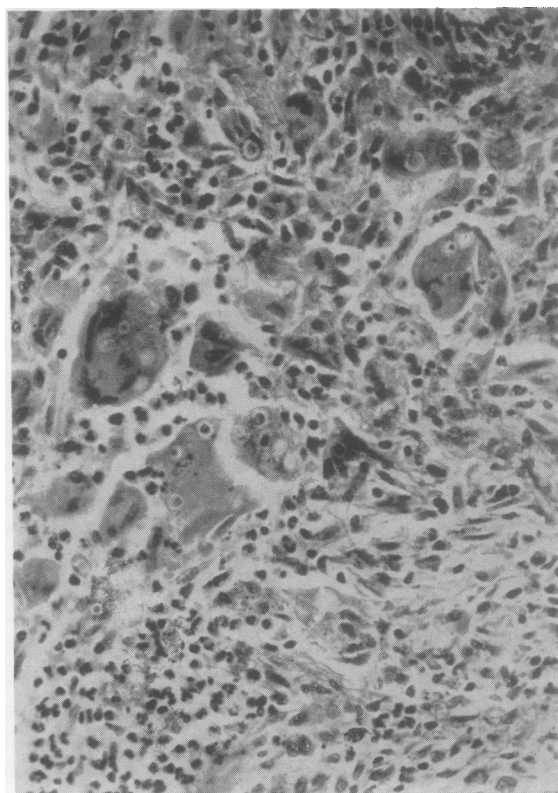


FIG. 6.—Another lung field showing more clearly the intracytoplasmic yeast-like parasites in the giant cells. Haematoxylin and eosin,  $\times 250$ .

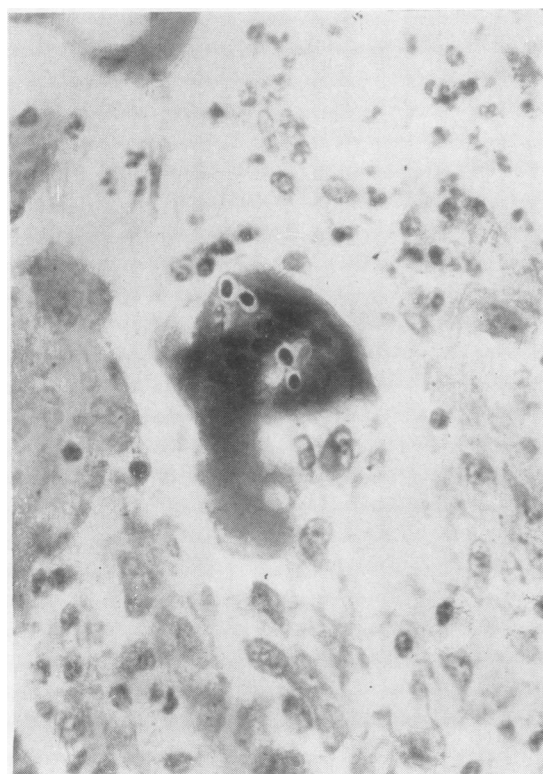


FIG. 7.—A lung field showing macrophage with four clear-cut parasites surrounded by unstained cell walls. Ziehl-Neelsen (modified),  $\times 250$ .

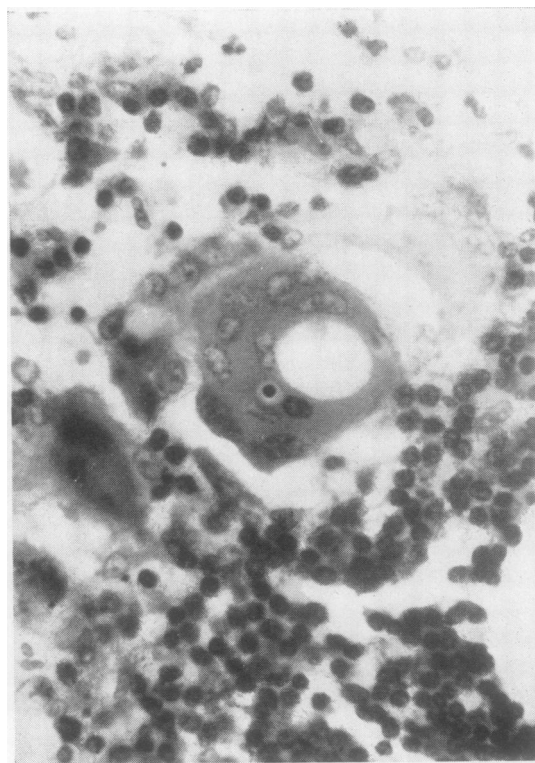


FIG. 8.—A lung field with one multinucleated giant cell showing one parasite. Ziehl-Neelsen (modified),  $\times 450$ .



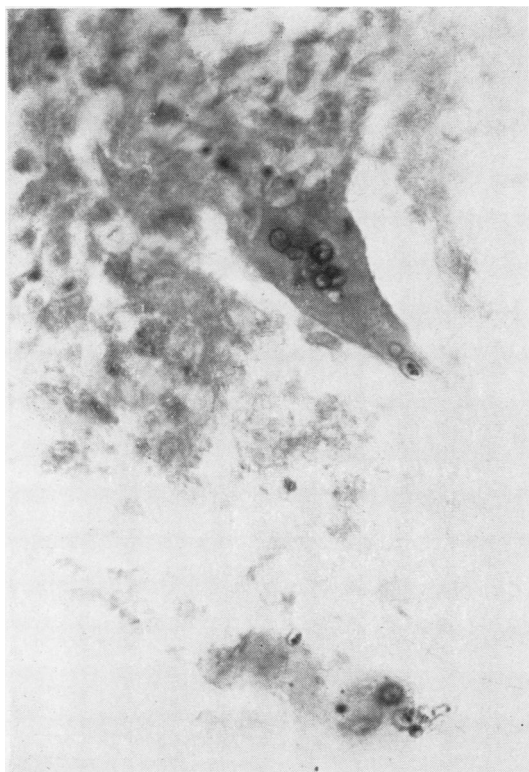


FIG. 9.—A lung field showing two giant cells with large parasites; two are budding. With this stain the body and cell wall of the parasite are both coloured, making it appear larger than in the sections stained with haematoxylin and eosin. Periodic-acid-Schiff,  $\times 450$ .

the walls of the parasites were stained, making them appear larger than in sections stained by haematoxylin and eosin (Fig. 9). With Gomori's stain the organisms appeared as grey to black, oval, spherical, or egg-shaped parasites and possessed distinct walls or shells. With these stains budding of the organisms was commonly seen. The mean size of the parasites was  $5.43 \mu \times 4.48 \mu$ , the largest  $8.1 \mu \times 5.0 \mu$  and the smallest  $3.1 \mu \times 2.6 \mu$ .

The above pathological picture of numerous giant cells, the large size and the intracellular nature of the organism, together with the staining reactions, strongly suggested the giant form of histoplasma, *Histoplasma duboisii* (Pine, 1960; Rosen, Townsend, and Fuller, 1961).

The fungi are much larger than is usual in *Histoplasma capsulatum* but fall within the range of *Histoplasma duboisii* (Emmons, 1961).

Until recently there was a difference of opinion as to whether *H. capsulatum* and *H. duboisii* were two distinct species. Dubois, Janssens, Brutsaert, and Vanbreuseghem (1952) suggested that the larger forms were a separate species, *H. duboisii*, whereas other workers (Moore, 1955; Drouhet and Schwarz, 1956)

felt that there was not sufficient evidence to establish the larger forms as a species distinct from *H. capsulatum*. Later results of histological studies on experimentally infected mice and hamsters (Schwarz and Drouhet, 1957) were in agreement with the results of Vanbreuseghem (1956) and showed that *H. duboisii* could be differentiated from *H. capsulatum* on the basis of its virulence and morphology in tissues. Vanbreuseghem (1953) recorded 15 cases of African histoplasmosis.

Polaroscopic examination of sections stained by periodic-acid-Schiff and Gridley's method failed to reveal birefringence.

In the differential diagnosis certain other fungi were considered, especially *Cryptococcus neoformans*. The average size was rather low for this organism. Specimens were stained with buffered crystal violet (Klatzo and Geisler, 1958) and examined by polarized light when the brilliant birefringence associated with cryptococcus was not seen.

### DISCUSSION

Histoplasmosis has often been reported in association with other serious conditions of which tuberculosis, Hodgkin's disease, Addison's disease, syphilis, diabetes, and leukaemia appear to be the most common ones in that order of prevalence.

The patient reported here was emaciated and gave a history of a subacute febrile illness with hypochromic anaemia. There was no evidence of leucopenia or leukaemia and clinically no sign of adrenal insufficiency. The radiographs of the chest and the clinical history, together with the positive tuberculin test, suggested a probable diagnosis of tuberculosis but fairly extensive bacteriological tests failed to yield *M. tuberculosis*.

At the time of the ante-mortem investigation of this case, there had been no suggestion of histoplasmosis and the necessary special cultural methods were not tried. The presence of numerous yeast-like forms of *Candida albicans* on microscopical examination of films prepared from sputa militated against the identification of any histoplasma cells present as there was no awareness of the possible finding of this organism. Mycelial or yeast forms of *Candida sp.* were not seen in sections of the lungs or other organs examined. Brucellosis was considered as a possible diagnosis, but antibodies could not be demonstrated in the serum.

Study of the literature on histoplasmosis, of which the largest proportion is American, shows the protean clinical manifestations of the disease. Apart from its association with other disorders, histoplasmosis can mimic many common diseases. The pulmonary lesions have been described by Tager and Liebow (1942), Parsons and Zarafonitis

(1945), and Monroe and Kurung (1953) as including interstitial pneumonitis, discrete and confluent areas of lobular pneumonia, miliary and larger tubercle-like nodules, granulomata, and caseation necrosis. There does not appear to be any characteristic type of pulmonary lesions, either clinically or radiologically: in some of the American cases of proved pulmonary histoplasmosis, the findings on chest radiography resembled the apical re-infective type of tuberculosis (Monroe and Kurung, 1953).

In Great Britain pulmonary histoplasmosis is rare and is seldom in the clinical consciousness, so that the diagnosis of cases can be very difficult or even impossible, especially where there is often a strong resemblance to, and frequently an association with, tuberculosis. Without special laboratory investigations to demonstrate the fungus, the disease will probably remain undiagnosed in life, and in the presence of other disease may not even be noted at necropsy.

If skin lesions, enlarged lymph nodes, or hepatic enlargement are present and biopsies are taken for histological examination, the organisms might be seen microscopically, but often, as in the case reported here, there are no lesions of this type.

Assuming that small numbers of the organisms were present in histological sections, they could be missed if there was some other obvious pathology present. The yeast-like forms do not stain very well with routinely used haematoxylin-eosin methods. In the normal staining methods used for tubercle bacilli, which would often be tried as the lesions can resemble tuberculosis, the parasites are usually completely decolorized.

Serological methods of diagnosis appear to have had varying degrees of success in the hands of various authors: presumably a rising antibody titre must be regarded as evidence of infection. Histoplasmin skin reactions are useful epidemiologically, but negative results do not exclude the disease, particularly in the acute disseminated form (Bronson and Schwarz, 1957).

The only positive method of diagnosis is by culture and identification of the mycelial and yeast forms of the organism. The organism grows slowly and can be difficult to separate from contaminants, especially as the medium must be incubated for several weeks before discarding as negative. *Candida* and allied species are particularly troublesome if present in large numbers (Poles and Lavertine, 1954). Another method of isolation is by the intravenous, or more usually intraperitoneal, inoculation of animals: the mouse appears to be a satisfactory and convenient animal. The inoculation of animals can prove a useful

method of separating histoplasma from contaminants as well as being a useful adjunct to the normal culture methods.

**SOURCE OF INFECTION.**—There was no evidence of histoplasmic infections in the family of the deceased and none of them had been abroad. He had no significant hobbies or recreations: there were no domestic animals or pets such as pigeons, hens, ducks, rabbits, or dogs.

In view of the finding of two positive skin reactors and one case of pulmonary histoplasmosis in the nine people dealing with raw cotton in one mill, three samples of raw cotton were examined for histoplasma with negative results. From the information available to us the source of the fungus could not be determined.

#### SUMMARY AND CONCLUSIONS

A fatal case of pulmonary and disseminated histoplasmosis is described together with limited family and industrial investigations.

From the relevant information it is concluded that the source of the histoplasma was unknown and that the infection took place in Britain.

We are indebted to Professor W. C. St. Symmers for considerable help and advice; to Dr. R. W. Riddell of the Brompton Hospital, London, together with Dr. Chester W. Emmons, chief mycologist, National Institute of Health, Dr. Samuel H. Rosen, and colleagues of the Armed Forces Institute of Pathology, Washington D.C., for reviewing the histological material. We also thank Dr. A. F. Ollerenshaw for access to the necropsy findings.

#### REFERENCES

- Arblaster, P. G. (1950). *Thorax*, **5**, 333.
- Bronson, S. M., and Schwarz, J. (1957). *Amer. Rev. Tuberc.*, **76**, 173.
- Crofton, J. (1950). *Thorax*, **5**, 340.
- Darling, S. T. (1906). *J. Amer. med. Ass.*, **46**, 1283.
- Drouhet, E., and Schwarz, J. (1956). *Ann. Inst. Pasteur*, **90**, 144.
- Dubois, A., Janssens, P. G., Brutsaert, P., and Vanbreuseghem, R. (1952). *Ann. Soc. belge. Méd. trop.*, **32**, 569.
- Earle, J. H. O., Highman, J. H., and Lockley, E. (1960). *Brit. med. J.*, **1**, 607.
- Emmons, C. W. (1961). Personal communication.
- Furcolow, M. L. (1960). In *Histoplasmosis*, pp. 382–404, ed. Sweany, H. C. Thomas, Springfield, Illinois.
- Hodgson, C. H., Weed, L. A., and Clagett, O. T. (1951). *J. Amer. med. Ass.*, **145**, 807.
- Klatzo, I., and Geisler, P. H. (1958). *Stain Technol.*, **33**, 55.
- Leigh, R., and Thomas, H. E. (1955). *Thorax*, **10**, 253.
- Limerick, C. B. (1951). *Brit. med. J.*, **1**, 885.
- Meleney, H. E. (1940). *Amer. J. trop. Med.*, **20**, 603.
- Monroe, J., and Kurung, J. M. (1953). *Ann. intern. Med.*, **38**, 206.
- Moore, M. (1955). *Amer. J. Path.*, **31**, 1049.
- Parsons, R. J., and Zarafonitis, C. J. D. (1945). *Arch. intern. Med.*, **75**, 1.
- Pine, L. (1960). In *Histoplasmosis*, p. 65, ed. Sweany, H. C. Thomas, Springfield, Illinois.
- Poles, F. C., and Lavertine, J. D. O'D. (1954). *Thorax*, **9**, 233.
- Rosen, S. H., Townsend, F. M., and Fuller, R. H. (1961). Armed Forces Inst. Pathology, Washington D.C. Personal communication.
- Sakula, A. (1953). *Tubercle (Lond.)*, **34**, 18.
- Schwarz, J., and Drouhet, E. (1957). *A.M.A. Arch. Path.*, **64**, 409.
- Symmers, W. C. St. (1956). *Brit. med. J.*, **2**, 786.
- (1960). Personal communication.
- Tager, M., and Liebow, A. A. (1942). *Yale J. Biol. Med.*, **14**, 469.
- Vanbreuseghem, R. (1956). *Mycologia (N.Y.)*, **48**, 264.