

THORACIC ACTINOMYCOSIS

BY

MICHAEL BATES AND GORDON CRUICKSHANK

From the North Middlesex Hospital and the Leicester Chest Unit

(RECEIVED FOR PUBLICATION JANUARY 9, 1957)

Thoracic actinomycosis was first described by Ponfick in 1882. It has been a serious disease, and, until recent years, there has been no satisfactory treatment. The literature is extensive and various forms of therapy have been claimed as successful, but the failures have been more impressive. The mortality rates quoted by different authors have varied from 75% to 100%; but since 1940 the results of treatment have improved. It is now reasonable to expect a 90% cure rate for all cases of thoracic actinomycosis, provided that antibiotic treatment is given in sufficient quantity and for an adequate length of time. There has been uncertainty both in the nomenclature of the causative organism and also in the aetiology and classification of the thoracic manifestations in man. It is because of this radical change in treatment and improvement in the mortality rate that we now review the subject.

HISTORICAL SURVEY

Bollinger (1877) first used the term "actinomycosis" with reference to a disease of cattle in which there was a woody swelling of the tongue and diffuse enlargement of the jaw. In the same year Harz (1877) suggested the use of the term "ray fungus" or *Actinomyces bovis* for the delicate, branching mycelial filaments which caused the disease in cattle. Israël (1878, 1879) was the first to find the organism in human necropsy material and in 1887 gave a clinical description. Bostroem (1890) described an aerobic form of the organism in cattle and in man; this form was not acid-fast and subsequently became known as *Actinomyces graminis*. Acland reported the first case of human actinomycosis in this country in 1884 (quoted by Foulerton, 1913). Hodenpyl (1890) wrote the first report from America of two fatal cases of thoracic actinomycosis. Bostroem (1890) gave the first bacteriological description of the organism, while in the same year Wolff and Israël (1891) wrote a description of the pathology based upon two human cases; they isolated an anaerobic form

which grew at body temperature, and showed true branching. Nocard (1888) described the pathogenic aerobic genus which was subsequently called *Nocardia*. Eppinger (1890) isolated a further aerobic form which was acid-fast called *Actinomyces asteroides* from a human brain abscess, and this type is also occasionally found in lung infections. In 1905 Wright established the term *Actinomyces bovis* for the anaerobic form, and this nomenclature continued until 1949 when the Medical Research Council (memorandum No. 23, 1949) decided that the anaerobic organism responsible for all human infections should subsequently be known as *Actinomyces israeli*.

REVIEW OF THE LITERATURE

Before 1940 thoracic actinomycosis was treated by various methods; occasionally one of these was used alone but more often in conjunction with other types of treatment. We have reviewed the literature on this subject under the different types of therapy used rather than in their chronological order of trial. The majority of papers concern a small number of cases, and there are few articles in which a significant number have been treated by any one method.

Trevithick (1906) reported an interesting case of actinomycotic lung abscess which was expectorated, and resolved spontaneously without treatment. A year later this patient developed abdominal actinomycosis which was cured by iodine and radiotherapy. At the beginning of a long list of specific therapeutic measures this case report serves to remind us of the body's natural resistance to the disease provided it is given some help in the way of general supportive measures. Vinson and Sutherland (1926) also mention a case where a resistance to the disease had been acquired. In 1897 their patient developed an actinomycotic ulcer of the tibia and not until 1924 did the disease manifest itself again by the development of an oesophago-bronchial fistula.

TREATMENT

VACCINES

Wynn (1908) reported a case of thoraco-abdominal actinomycosis successfully treated with a vaccine. Neuber (1940) also claimed satisfactory results from vaccine therapy in cervical and pulmonary actinomycotic infections. In 1949 Suteev treated 12 patients by immunization with "actino-filtrate" and seven were apparently cured, including one pulmonary case.

IODINE IN VARIOUS FORMS

For many years it was thought that iodine had a specific action upon the *Actinomyces israeli*; but it is now realized that the benefit gained from iodine therapy is the result of resorption of fibrous tissue, which is always abundant in any actinomycotic lesion, thus allowing other agents such as the sulphonamides or penicillin to get into immediate contact with the causative organism. Foulerton (1913) reported a pleuropulmonary infection presenting as a breast abscess and finally healing after treatment with large doses of potassium iodide for a year. Preston (1928) reported two cases of actinomycotic lung abscess and severe bronchitis which showed marked improvement on iodides by mouth in conjunction with 20 ml. of "lipiodol" injected into the trachea. Another case in which endotracheal iodine was considered to be of importance was reported by McHardy and Browne (1943). Their patient had an actinomycotic granuloma obstructing the middle lobe bronchus and was treated with 300 grains of potassium iodide daily for 80 days in conjunction with two bronchograms.

RADIOTHERAPY AND RADIUM IMPLANTS

Harsha, of Chicago (1904), first treated a case of actinomycosis with radiotherapy, and this form of treatment was later popularized by Heyerdahl in 1914. Cope (1915) described a case with multiple chest-wall sinuses treated by radium implantations. Desjardins (1928) reported a pulmonary case cured by a large dosage of radiotherapy, and Smith (1934) similarly treated 21 pulmonary cases, resulting in the cure of two, the improvement of two others, and the death of the remainder. He considered that the exact action of the x rays upon the actinomyces *in vivo* was not known, and that as large a dose as possible should be given without causing permanent damage to the skin. Stewart-Harrison (1934) demonstrated the efficacy of radiotherapy for cervical infections by curing

20 cases; but in eight cases of abdominal and pulmonary disease it had no effect and all the patients died. Williams (1944) considered radiotherapy to be the most useful therapeutic agent and reported two thoracic cases so treated, one of which was cured.

THYMOL

Myers (1937) reported five cases of actinomycosis treated with 10% thymol, two of them being thoracic cases; one of these died and the other was alive and well a year later. Etter and Schumacher (1939) also claimed a satisfactory response in treating a case with 0.65 g. of thymol by mouth daily for 17 days.

SURGICAL DRAINAGE AND EXCISION

There are few reports of cases treated by surgery alone, most having been treated by surgery in conjunction with other forms of therapy. The two types of thoracic disease most likely to respond to surgical drainage alone are the chest wall abscess without underlying pleuropulmonary infection, and the pleural empyema. Excision of the lung, by lobectomy or pneumonectomy, has only proved successful in conjunction with sulphonamide or penicillin therapy.

Cutler and Gross (1940) considered surgery the only treatment likely to be successful in this condition, and mention a mortality rate of over 95% for all other methods of treatment.

SURGERY IN CONJUNCTION WITH VACCINE, IODINE, THYMOL, OR RADIOTHERAPY

Colebrook (1921) advocated surgery in conjunction with vaccine in doses of 4 to 10 million fragments. Six thoracic cases so treated all died. Bigland and Sergeant (1923) reported a case of actinomycotic empyema and staphylococcal pericarditis satisfactorily treated by rib resection in conjunction with collosol iodine injected intravenously and into the pleural and pericardial sacs together with potassium iodide by mouth. Torek (1926) produced improvement in a case with multiple chest wall abscesses and a bronchocutaneous fistula by incision in conjunction with large doses of potassium iodide. Harris and Priestley (1944) reported a fatal case originating in the skin with miliary pulmonary lesions which showed no response to iodides, thymol, and radiotherapy. Benbow, Smith, and Grimson (1944) collected 26 thoracic cases from the literature, 25 of which were dead at that time. They also reported two cases of infection with *Nocardia asteroides* which

were well a year after treatment with sulphonamides, radiotherapy, iodides, and surgery. A case of actinomycotic empyema and pulmonary infection was reported by Jacob (1944) as being cured by iodides in conjunction with open drainage. Six others reported by Kolouch and Peltier (1946), which were treated by surgery, iodides, and irradiation, all died. Wangensteen (1932) reported a case with extensive involvement of the lung and chest wall treated satisfactorily by repeated surgery and iodides, until the patient eventually died of a cerebral abscess. He also treated six other cases of severe thoracic infection by radical surgery, iodides, and radiotherapy, all of which died (1936). Good (1934) reported a case to be improved by radical excision and thoracoplasty associated with 600 grains of potassium iodide daily.

Cope (1938) in his monograph on actinomycosis gave a full summary of the various treatments used. He mentioned Chitty's method of giving tincture of iodine in milk, injection of normal lymph node extracts, and "actinomycine," a vaccine used by several Argentine workers. Cope also reported satisfactory healing in a case treated with vaccine and diathermy excision. In 1939 Cope advocated surgery for the opening up of sinuses only, and did not advise the excision of large infiltrating areas.

Two thoracic cases were well two years after radical surgery, massive iodides, and radiotherapy given by Bisgard (1939). Davis (1941) reported 46 cases of all types of actinomycosis and considered that Lugol's wet dressings, iodides to the limit of tolerance, radiotherapy, and surgery combined were the best forms of treatment.

SULPHONAMIDES

Since 1940 the treatment of thoracic actinomycosis has been revolutionized by the introduction first of the sulphonamides and later of penicillin. The various forms of sulphonamides have all had their individual successes, and where one type has failed a good result has been obtained by using another type or a combination of sulphonamides.

Morton (1940) was the first to report improvement in a case of pulmonary actinomycosis treated with sulphonamides. Dobson, Holman, and Cutting (1941) and Wilkinson (1941) were also among the first to report satisfactory results with sulphonamides. Mitchell (1942) reported a thoraco-abdominal case which had failed to respond to vaccines and iodides but was apparently cured nine months after a course of a sulphapyridine. Lidbeck (1942) reported a fatal case from metastatic spread, in which sulphanilamide, sulphapyridine,

and sulphathiazole had been given continuously for 14 months without producing any toxic effects. A dramatic cure with sulphadiazine was claimed by Ladd and Bill (1943). Lyons, Owen, and Ayers (1943) report two cases, one being well two years after treatment with iodides, surgery, sulphathiazole, and sulphanilamide, the other being improved after five months' treatment with sulphadiazine. Watkins (1944) reported two children aged 3 years and 18 months respectively suffering from actinomycotic empyemata who were treated successfully by drainage and sulphonamides and by aspiration and sulphonamides respectively. Auspaugh (1945) reported a case of military spread from which the patient died in spite of sulphonamides and general supportive measures.

PENICILLIN ALONE OR COMBINED WITH OTHER FORMS OF THERAPY

Penicillin has proved a more powerful agent than the sulphonamides, and, even if not always successful by itself, it has been used to good effect in conjunction with surgery and occasionally sulphonamides.

In 1943 Florey and Florey reported the first two cases of thoracic actinomycosis treated by small doses given four-hourly through a duodenal tube without having any effect on the course of the disease; the other was a pleuropulmonary case which was well four months after drainage of an empyema and five weeks' penicillin therapy.

Keeney, Ajello, and Lankford (1944) carried out *in vitro* experiments with the sulphonamides and penicillin, and found that sulphamezathine, sulphadiazine and sulphathiazole were more effective against *Actinomyces bovis* than sulphanilamide; they also showed that *Actinomyces bovis* was inhibited and apparently killed by a concentration of 0.01 Oxford units of penicillin per millilitre of medium. Shulman (1944) treated a case with a total of 3 mega units of penicillin in five courses over a period of one year. Considerable temporary improvement was noticeable after each short course, but the patient eventually died; this illustrated the efficacy of the drug but the inadequacy of the dosage. Christie and Garrod (1944) gave a preliminary report on the first clinical penicillin trials in this country and included two thoracic cases both of which are included in this series and originally reported by Roberts, Tubbs, and Bates (1945). Walker and Hamilton (1945) reported six cases, one being of widespread disease with pulmonary involvement which responded dramatically to moderate penicillin dosage after a previous failure to respond to sulphonamide therapy.

Lynch and Holt (1945) reported a pleuropulmonary case with pericardial and cardiac involvement which failed to respond to iodides, sulphonamides, and radiotherapy. One hundred thousand units of penicillin were given during the last 48 hours of life. Culture of the pleural fluid grew *Actinomyces graminis*. Jones and Brownell (1945) reported two cases of thoracic actinomycosis after hysterectomy, both of which responded to penicillin. Dobson and Cutting (1945) described 16 cases of actinomycosis, three being pulmonary in origin. Two of these cases were greatly improved by sulphonamides and penicillin, while the third case, in which *Nocardia asteroides* was grown from the sputum, died in spite of sulphadiazine therapy.

Kay and Meade (1945) reported 93 cases of actinomycosis, two being pulmonary in type; the latter were cured by pulmonary resection in association with chemotherapy. They came to the conclusion that penicillin was better than the sulphonamides, but that the two combined were more effective still. A chest wall abscess in a girl aged 10 was cured by local and systemic penicillin followed by a two months' course of iodine. Seven patients were cured by Poppe (1946), three of whom were treated by lobectomy and penicillin. Shaw, Holt, and Ray (1946) reported two, one of whom responded to penicillin and sulphadiazine therapy, and the other to empyema drainage and penicillin; in the first of these the infection was due to *Nocardia asteroides*. Kay (1946) described two cases of the bronchopulmonary form in which resections were performed in conjunction with chemotherapy during the subacute stage of the disease. He considered segmental resection to be unwise, because the fissures were almost invariably obliterated and the danger of causing an extension of the disease was high. He therefore preferred pneumonectomy to lobectomy. In 1947 Kay reported five more cases; two of these were treated by pneumonectomy and two by lobectomy and all of them with penicillin and sulphadiazine. While he considered that penicillin and sulphadiazine were the most effective therapeutic agents on clinical grounds, preliminary evidence from experiments *in vitro* suggested that streptomycin was more effective against the *Actinomyces israeli* than either penicillin or the sulphonamides. Pyper (1947) and Hollis and Hargrove (1947) reported further cases treated by sulphonamides and penicillin. Moore (1947) believed that the introduction of chemotherapy permitted more radical surgery in the acute stage of the disease. Adamson and Hagerman (1948) cured an infection of the right lower lobe with combined penicillin and sulphon-

amide therapy. Nichols and Herrell (1947) reported 22 pulmonary cases, nine of which were treated with penicillin, five being cured; 13 were not given penicillin and of these five were improved and the remainder died. Robinson and Tasker (1949) reported 12 further thoracic cases, and came to the conclusion that sulphonamide or penicillin therapy had no advantage over the older types of treatment. Campbell and Bradford (1948) described six cases, one being a severe pleuropulmonary infection which was cured by drainage of the empyema in conjunction with systemic penicillin and sulphadiazine. Six thoracic cases were described by Delarue and Houdard (1949) of which four were fatal, including one treated with 24 mega units of penicillin. Rabin and Janowitz (1950) reported three cases of actinomycotic empyema, one having an underlying lung abscess. The empyemata were cured by simple open drainage, while the third case required penicillin and radiotherapy in addition to drainage for its cure.

Since 1952 several reports have appeared in the literature of cases treated by combined penicillin and sulphonamides (Scarinci, 1953; Rivas, 1952; Lawonn, 1953; Rumrich, 1953; Pütz, 1954; Nowski, 1953).

In a brief general review of thoracic actinomycosis Delarue (1954) recommends a combination of penicillin and sulphonamides as the most satisfactory treatment at the present time.

STREPTOMYCIN

Meurers (1951) was the first to report a case of pulmonary actinomycosis successfully treated with streptomycin and supronal, while Capitolo (1951) reports a similar case treated with streptomycin and P.A.S. Torrens and Wood (1949) reported three cases of actinomycosis treated with streptomycin, one being a thoraco-abdominal case in which a remarkable recovery took place when surgery, penicillin, sulphonamides, and iodides had previously failed. Blainey and Morris (1953) successfully treated a case of actinomycotic pyaemia resulting from a pulmonary infection with a combination of streptomycin, penicillin, and sulphonamides.

CHLOROMYCETIN, AUREOMYCIN, TERRAMYCIN, ETC.

In some cases the *Actinomyces israeli* is highly sensitive to these drugs, but the drugs in themselves have disadvantages when given for the prolonged period which we consider necessary in the treatment of thoracic actinomycosis. It is doubtful whether it would be justifiable to give chloromycetin for this condition, because of its possible adverse

effect on the bone marrow, unless the particular strain of *Actinomyces israeli* was insensitive to all other chemotherapeutic agents. Aureomycin and terramycin have other disadvantages, if given over a prolonged period of time, as we found ourselves in the one case treated with terramycin. Littman, Paul, and Fusillo (1952) treated one case successfully with chloromycetin for two months without any complications, and say that penicillin, aureomycin, and the sulphonamides are inadequate for a permanent cure. Our results do not confirm this statement.

Ocklitz (1952) treated two cases successfully with a combination of penicillin and aureomycin. Zoeckler (1951) treated one case with chest wall and pericardial involvement, also successfully, with a combination of penicillin and aureomycin.

Other cases have been treated with aureomycin (Heller, 1954; Reitter, 1954), combined aureomycin, erythromycin, and penicillin (Barker, 1954) and one by penicillin combined with potassium iodide Coenegrachts and Keil, 1954).

Other examples have been published by Ayberk (1953), Petříková and Vaněček (1953), and Sznajder (1953).

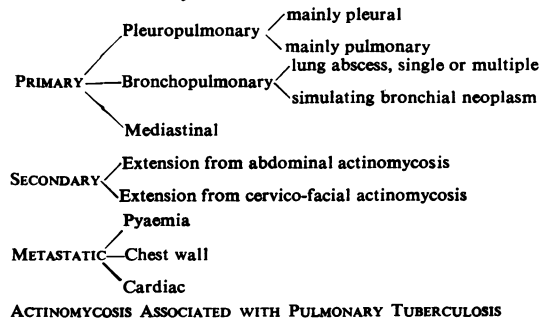
Cases treated by lung resection are described by Reitter (1954) and Kugel, Harlacher, and Hueck (1953).

CLASSIFICATION

The usual classifications of thoracic actinomycosis have seemed to us unsatisfactory and we have produced an enlargement and modification of the existing classifications. The nature of actinomycosis with its disregard of tissue barriers makes classification difficult; for example, a primary pulmonary infection may spread through the pleura and chest wall, leaving an empyema and multiple sinuses in its path. We have therefore concentrated upon the initial clinical picture with which the disease presented itself. The bronchitic and bronchopneumonic varieties have been omitted from this classification for the following reasons. Rare cases of the bronchitic variety have been described in the literature (Canali, 1882; Cope, 1938), but these have been of localized granulomata seen on bronchoscopy, and we do not believe that an anaerobic infection can be confined to the wall of a bronchus without disease within the lung substance adjacent to that bronchus. On these grounds we have decided to omit the bronchitic variety.

After study of these 85 cases we have found that actinomycotic bronchopneumonia only occasionally occurs as a complication of an existing

pulmonary infection, and we have no details of any case presenting initially as a bronchopneumonia. We therefore present the following classification as a basis for study.



AETIOLOGY

Cope (1949) states: "We must put aside the popular fairy tale about infections from grass and straw." Primary infection of the lung is caused either by the inhalation from a source within the buccal cavity, or by spread through the blood stream of the fungus *Actinomyces israeli*, which is an anaerobic or micro-aerophilic organism. Infection with the aerobic organism *Nocardia asteroides* occasionally occurs, and only one of the 85 patients in this series was infected with this organism. It has been shown that the *Actinomyces israeli* is a normal inhabitant of many people's mouths and under certain conditions of tissue damage or infection in the lung the organism finds the necessary conditions to invade the lung tissue and causes the clinical condition of pulmonary disease. On rare occasions the inhalation of fragments of carious teeth have been reported as the cause of an actinomycotic lung abscess (Israel, 1887; Roberts quoted by Cope, 1939).

Lingual actinomycosis was quoted by Bonnet (1921) as being the primary source of a thoracic infection. Delarue and Houdard (1949) considered that the inhalation of infected material occurred from a lesion in the perilaryngeal tissues rather than from a carious tooth. In the present series there is an increased incidence between the ages of 10 and 20 and between the ages of 30 and 50. We consider that infection from the tonsils is an important aetiological factor in the younger of these age groups, and dental sepsis in the older.

Pleuropulmonary infections occurred frequently in this series (44 cases). We believe that it is important to divide the pleuropulmonary infections into two categories, those mainly pleural and those mainly pulmonary; the prognosis of cases presenting with an empyema alone is better than those in

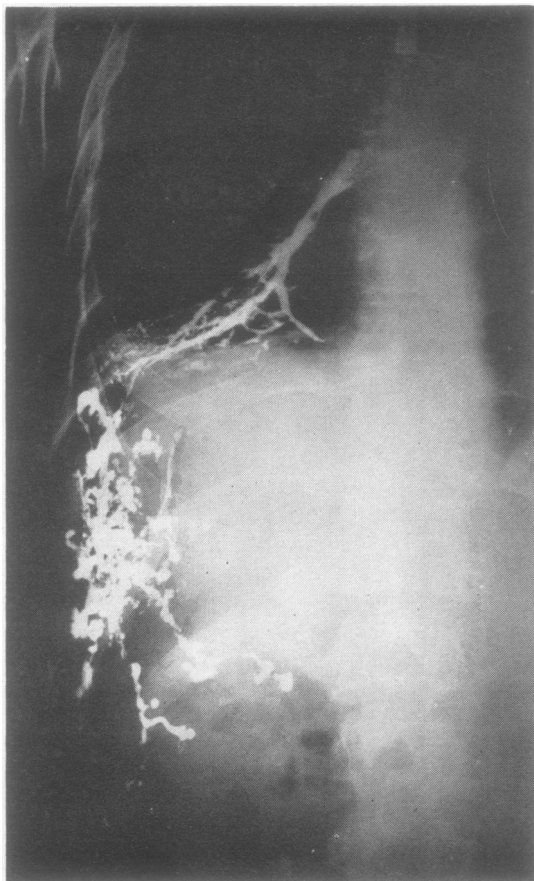


Fig. W.H.1

which there is an empyema together with pulmonary involvement. Bronchopulmonary infections were less common and only 11 cases occurred. Mediastinal infections may result from the entrance of the *Actinomyces israeli* through a mucosal lesion of the oesophageal wall; this lesion may subsequently heal or occasionally persist as a broncho-oesophageal fistula. In mediastinal infections the disease tends to spread to the vertebral column, to the pericardium, and round both sides of the chest, presenting as bilateral chest wall or lumbar abscess.

Secondary extension from abdominal actinomycosis is the second most common cause of infection in the chest, and 13 cases occurred in this series. Generally the disease began in the ileo-caecal region as an appendix abscess and later a subphrenic or liver abscess developed; the infection then spread directly through the diaphragm into one or other of the lower lobes (Fig. W.H.1).

Secondary extension from cervico-facial disease is uncommon and only two such cases occurred in this series.

Actinomycotic pyaemia is rare and generally results from a pulmonary infection due to the anaerobic organism *Actinomyces israeli*, but cases have been reported due to the aerobic organism *Nocardia asteroides*; such spread through the blood stream invariably proved fatal before the introduction of antibiotics.

Pyaemia occurred in two of the 85 patients under review.

Chest wall lesions occurred in many of the intrathoracic infections already mentioned, but in some instances the disease appeared localized to the chest wall and did not invade the underlying pleura, at least not in the first instance. The disease appeared to be confined to the chest wall in five of the patients in this series.

Infection of the heart or pericardium was uncommon. There were two instances of pericardial involvement in this series, both from direct extension of disease in the mediastinum. There was no instance of metastatic cardiac infection.

Cornell and Shookhoff (1944) collected from the literature 68 cases in which the infection involved the heart or pericardium and added three of their own, including one which presented as mitral stenosis and rheumatic fever. In 29 of these 68 cases the infection resulted from direct extension and in 19 by embolic spread from a distant focus. They state that it is unusual for the presenting clinical picture to be one of heart disease. In 1951 Zoeckler collected a further eight cases including one of his own, which, together with the two cases from the present series, makes a total of 78 cases reported.

COMBINED PULMONARY TUBERCULOSIS AND ACTINOMYCOSIS

Von Arnim (1949) first described the combined presence of these two specific granulomata in a patient with a tuberculous cavity in the right upper lobe, the sputum containing tubercle bacilli. Later a substernal abscess developed from which typical actinomycotic pus was obtained. The patient died. We add two cases in which this combination of disease was present. Both had tuberculous empyemata, *Actinomyces israeli* being present in the pus in addition to tubercle bacilli. One patient recovered following thoracoplasty, the other died of amyloidosis five years after pleural drainage. Both these patients were treated in the pre-antibiotic era.

ILLUSTRATIVE CASES

PLEUROPULMONARY: MAINLY PLEURAL

L. P., a male plastic worker aged 42, first complained of severe bilateral chest pain in September, 1946. This was later associated with dyspnoea and fever and he was treated with sulphonamides. He then had a haemoptysis, and radiographs of the chest in October showed a large right pleural effusion from which 4 pints of pus were aspirated; the fever slowly settled until February, 1947, when the empyema was drained. On April 17, 1947, he was transferred to another hospital, where the haemoglobin was 68% and the leucocyte count 17,250 per c.mm. Bronchoscopy was negative, and on April 28 the empyema was re-drained, the pus growing micro-aerophilic non-haemolytic streptococci. For three days before and 10 days after operation he

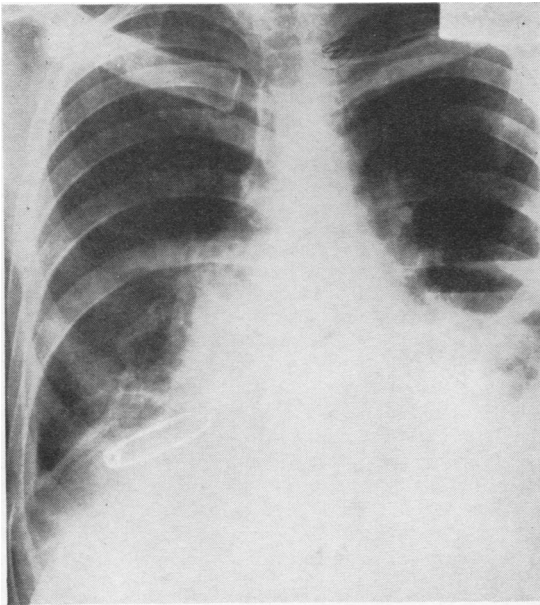


FIG. L.P.1

was given 200,000 units of penicillin twice daily, making a total of 5,200,000 units. On June 21 a large subcutaneous abscess was drained in the right axilla; this did not appear to communicate with the empyema cavity. On July 12 he developed left-sided pleurisy and his sputum became blood-stained. He was readmitted to hospital 10 days later with clubbing of the fingers, which had not been present before, and he had a left-sided empyema from which micro-aerophilic non-haemolytic streptococci were grown (Fig. L.P.1). This was drained on August 1 and a large loculated cavity containing fibrin was found. The left lung re expanded and he was discharged, only to be readmitted on September 14 with marked dyspnoea and an abscess in the right axilla. This was drained of foul-smelling pus which contained sulphur granules and grew

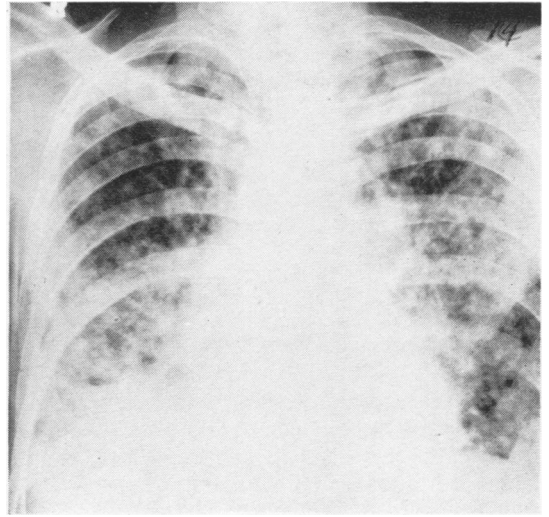


FIG. L.P.2

Actinomyces israeli on anaerobic culture. His temperature did not settle and on October 2 both empyemata were explored and further loculations of the cavities were found. The pus from the left side also grew *Actinomyces israeli*, and after operation he was given a second course of penicillin, 400,000 units a day for eight weeks, making a total of 23,400,000 units. He quickly gained 20 lb. in weight and was discharged with both empyemata healed. On February 5, 1948, he was readmitted with breathlessness and pain in the chest. Radiographs showed a diffuse mottling throughout both lung fields (Fig. L.P.2). He was given a third course of penicillin, 1,000,000 units a day for 38 days, and again discharged having gained weight, though the radiographs showed only slight improvement. In July,

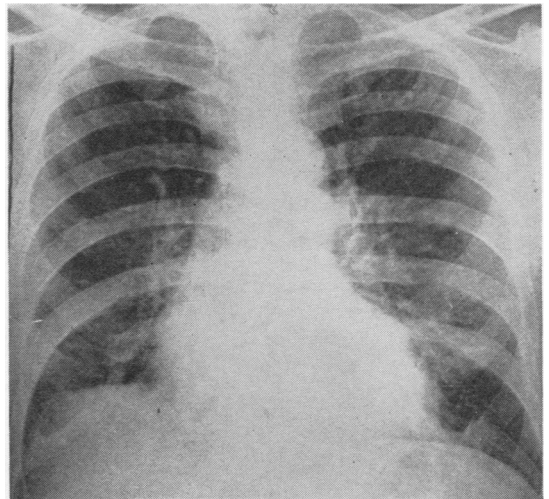


FIG. L.P.3

1948, he had a further relapse and was readmitted with persistent fever, cough with copious blood-stained mucopurulent sputum, and severe pain in the chest. Dyspnoea was present on talking, and he had lost $1\frac{1}{2}$ stones in weight since his last discharge. Radiographs showed a return of the diffuse mottling throughout both lung fields, and many specimens of sputum were negative for tubercle bacilli, but occasionally Gram-positive filaments identical with *Actinomyces israeli* were found. A fourth course of penicillin was given; 1,000,000 units a day for 84 days, making a combined total for the four courses of 149,600,000 units. When last seen as an out-patient in August, 1956, he weighed over 13 stones and was fit and working. He was symptomless and a radiograph of the chest was clear (Fig. L.P.3).

This case demonstrates the difficulty that may be experienced in diagnosing this disease even when it is suspected; seven months elapsed from the time of drainage of the first empyema to the finding of the *Actinomyces israeli*. The diffuse mottling throughout both lung fields was the result of a pyaemic spread from which the patient would have died in the pre-penicillin era. It was not until he was given his fourth and only adequate course of penicillin that the disease was overcome.

PLEUROPULMONARY: MAINLY PULMONARY

G. S., a commercial traveller aged 58 years, developed a severe cold and dry cough in August, 1950. Three months later he complained of a continuous, dull aching pain between the shoulders and was treated for fibrositis. His general condition began to deteriorate

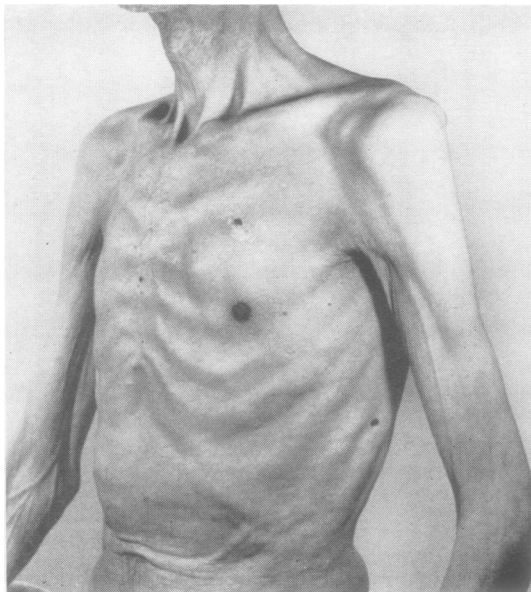


Fig. G.S.1

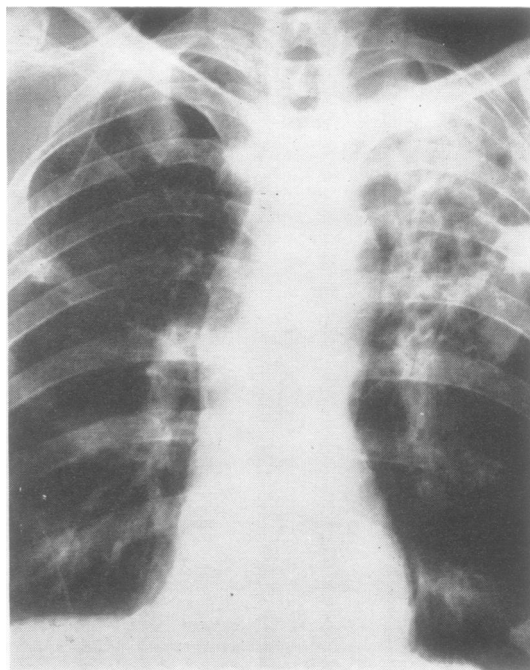


Fig. G.S.2

and he lost 3 stones in weight. In December, 1950, he coughed up purulent sputum and remained in bed because of lassitude. He was admitted to hospital on January 15, 1951, suffering from cachexia and coughing up 2 oz. of purulent sputum daily (Fig. G.S.1). He had an empyema necessitans presenting in the third left interspace anteriorly and was in pain. His teeth were carious and pus was exuding around the sockets. He weighed 7 stones and his fingers showed early clubbing. His haemoglobin was 46%. Stinking pus was aspirated from the empyema and both the pus and sputum contained sulphur granules and grew *Actinomyces israeli* on anaerobic culture. A radiograph of the chest showed diffuse mottling in the left upper lobe with a fluid level in the pleura anteriorly and periostitis of the third rib posteriorly (Fig. G.S.2). On January 20 he was given a transfusion of 2 pints of fresh blood and penicillin therapy was begun, 2 mega units of crystalline penicillin being given eight-hourly. Within three days he had lost his pain, and after a week's treatment he had no cough or sputum. His appetite returned and he gained weight. A month later all his teeth were removed and he was discharged from hospital on March 22, having had a total of 365 mega units of crystalline penicillin. The haemoglobin was then 94% and he weighed 9 st. 12 lb. (Fig. G.S.3). A radiograph of the chest showed incomplete clearing. Six hundred thousand units of distaquaine penicillin daily was continued at home for a total of 86 mega units. Since then he has returned to work and has remained fit and well. A radiograph taken in June, 1956, showed complete clearing of the left chest.

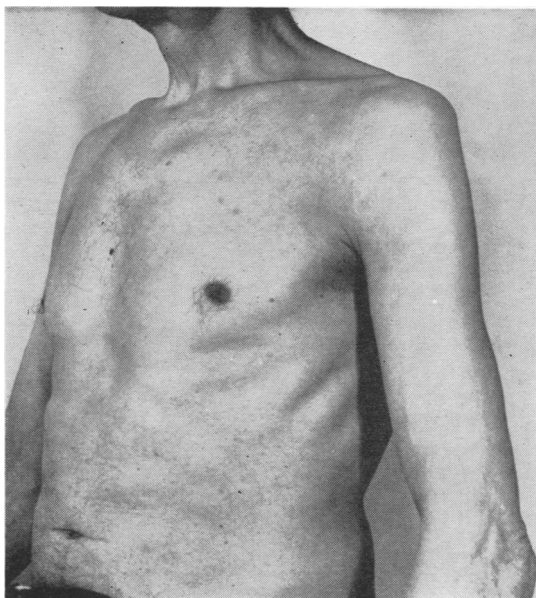

Fig. G.S.3

When this patient was first admitted to hospital he was moribund and his response to penicillin therapy was dramatic. The improvement in the radiographs did not keep pace with the improvement in his general condition, and it was at least a year before they finally cleared.

BRONCHOPULMONARY: SINGLE LUNG ABSCESS

J. G., aged 24 years, a cabinet maker, developed bronchitis with copious sputum in December, 1936. He was admitted to hospital and later developed a lung abscess in the right upper lobe. This was drained by rib resection and open drainage in April, 1937; he was discharged in June, 1937, with the wound soundly healed. He remained well until March, 1938, when a painful swelling appeared over the left chest wall anteriorly and the patient became ill and anaemic. A left-sided empyema was drained and the tissues were found to be oedematous and pockets of pus and granulation tissue were present. A streptothrix was seen in the granulation tissue, while the pus contained sulphur granules and grew *Actinomyces israeli* on anaerobic culture. Further operation was necessary and tracks were found running round from the anterior chest wall back into the erector spinae muscle. In April further ribs were resected, and in June, 1938, there was a foul discharge from the wound which resolved with zinc peroxide dressings. The patient has remained well ever since, apart from occasional small haemoptyses due to the resulting bronchiectasis, and in 1956 he was working as an electrical contractor.

Although there was no bacteriological information about the pus from the lung abscess, there can be

little doubt that this and the ensuing empyema were actinomycotic. It is interesting that such extensive pulmonary and pleural disease should have been eradicated by simple drainage in conjunction with zinc peroxide dressings.

D. H., aged 46 years, a garage attendant, developed pneumonia. Six weeks later he was admitted to hospital, by which time he had lost a stone in weight but had no chest symptom other than a slight cough. A radiograph showed a single cavity in the apical segment of the right lower lobe (Fig. D.H.1). Bronchoscopy was normal. A fluctuant swelling appeared over the right trapezius from which pus was aspirated. The patient was treated as a case of pulmonary tuberculosis. He died six weeks after admission. Necropsy revealed multiple abscesses in the right lobe of the thyroid gland, both kidneys, and the right lung. Culture of pus from these grew a *Nocardia asteroides*.

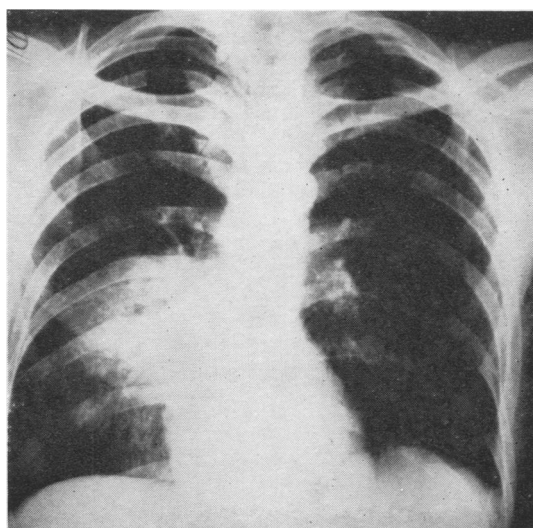


Fig. D.H.1

BRONCHOPULMONARY: SIMULATING NEOPLASM

C. D., aged 44 years, a metal spinner, complained of lassitude and an aching pain in the right chest posteriorly, beginning in June, 1952. In September he developed aching pains in the joints of all the limbs, but these disappeared after a month. Radiographs of the chest showed a diffuse opacity situated over the posterior part of the right upper lobe and apex of the lower lobe (Fig. C.D.1). A bronchoscopy was performed in October, 1952, as it was felt that he was most likely to be suffering from a bronchial carcinoma, but the bronchial tree was normal. The radiographs remained unchanged, and he was admitted to hospital on November 11, 1952. On examination he was

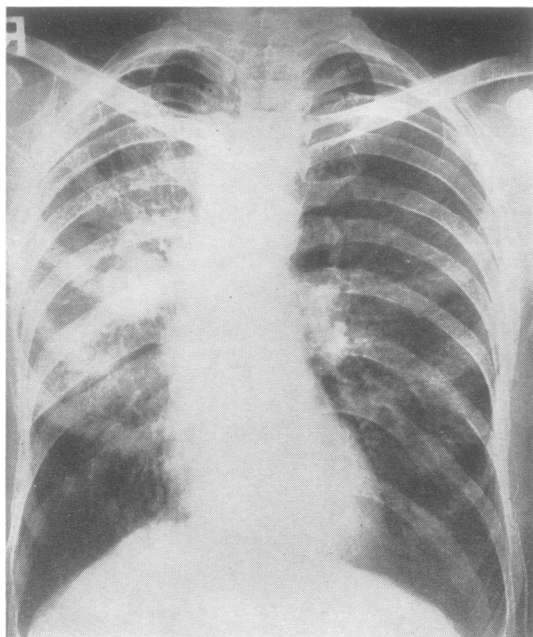


FIG. C.D.1

found to be in moderate health and to have early clubbing of the fingers. He had a morning cough with a little mucoid sputum. There was bronchial breathing over the whole of the right chest posteriorly and tomograms showed a rounded opacity in the apex of the right lower lobe which was considered to be a primary peripheral bronchial carcinoma (Fig. C.D.2). Bronchoscopy was repeated and again the findings were negative. Clinical and radiological examination of his joints did not reveal abnormalities. A right exploratory thoracotomy was performed under penicillin cover on November 20. The lung was found to be so adherent

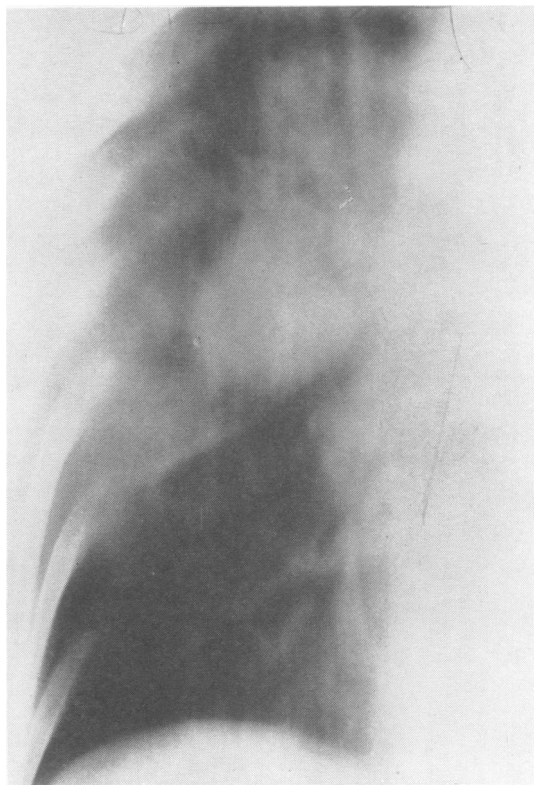


FIG. C.D.2

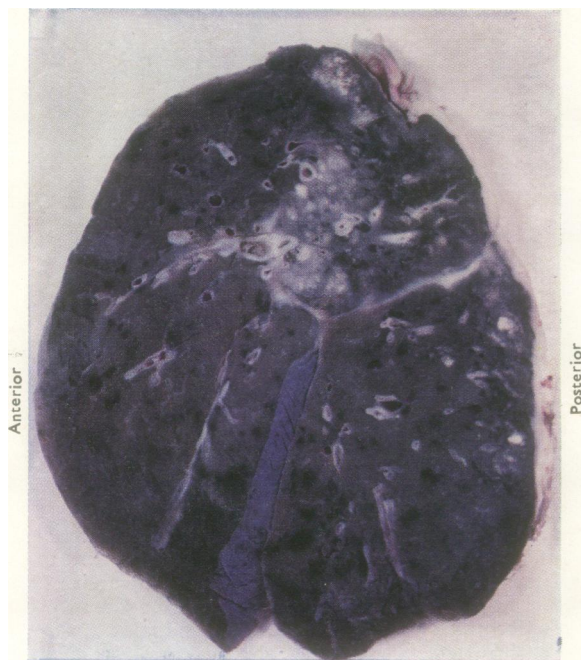

FIG. C.D.3.—The excised right lung is shown about half normal size. There is much fibrous thickening of the pleura posteriorly and of the interlobar septum. Several conglomerates of chronic abscesses with pulmonary fibrosis are seen in both upper and lower lobes; the largest conglomerate, towards the hilum, simulated tumour in radiographs.

posteriorly that an extrapleural strip was necessary in order to free it; when this had been done no localized mass could be felt in the lung as the tomograms had suggested. As the fissures had become obliterated and the disease appeared to involve the whole lung, a pneumonectomy was performed. His post-operative course was uneventful, and a week later the lung was cut after fixation and the naked-eye appearances suggested pulmonary tuberculosis (Fig. C.D.3). Penicillin was discontinued and streptomycin and P.A.S. substituted, until a week later when the histological report showed the presence of pulmonary actinomycosis. Crystalline penicillin was then given intrapleurally, and systemically 2 mega units eight-hourly for a further six weeks. He

was discharged, and 600,000 units of distaquaine penicillin given intramuscularly for a further six weeks, making a total of 287 mega units systemically and 10 mega units intrapleurally. Since then the patient has remained well and was last seen in January, 1956.

Those cases which simulate bronchial neoplasm are of particular interest to the thoracic surgeon. It is generally impossible to make a correct pre-operative diagnosis, and therefore pulmonary resection is carried out, often with resulting broncho-pleural fistula, empyema, and spread of the disease. We would stress the importance of immediate examination of the specimen in all undiagnosed resections so that if by chance it should prove to be a case of pulmonary actinomycosis then adequate dosage of antibiotics can be given without delay, thus helping to avoid serious and often fatal complications.

MEDIASTINAL

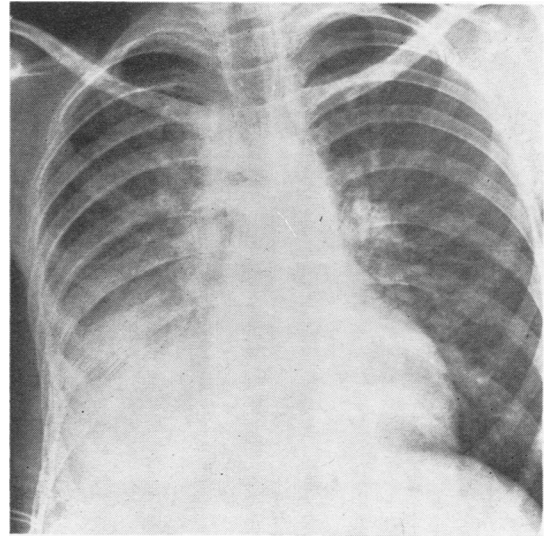


Fig. K.W.1

K. W., aged 10 years, was first noticed to have a painless swelling about 6 in. in diameter over the right lumbo-dorsal region in December, 1939. She was also breathless on exertion and was admitted to hospital with an evening temperature of 100.5° F. This swelling was incised and inspissated pus drained, the bacteriology of which is not known. Later in the same month she was given 0.5 g. sulphapyridine four-hourly for nine days. On January 2, 1940, a rib was resected through the original incision; the pleural cavity was found to contain blood-stained fluid, and a drainage tube was inserted. By January 6 two additional sinuses had formed and her general condition had deteriorated. On March 28, 1940, she was transferred to another hospital with a large right pleural effusion and a leucocyte count of 37,000 cells per ml. Thin fluid was aspirated from the right pleural cavity in which no organisms were seen on direct smear, and which was sterile on culture. Sulphur granules and Gram-positive filaments were found in the discharge from the drainage site. The patient was put on pot. iod., grains 30 per day, and discharged home. In July, 1940, she was readmitted to hospital with an indurated swelling over the right eleventh rib which discharged spontaneously; the pus contained sulphur granules and grew *Actinomyces israeli* on anaerobic culture. Radiographs in August, 1940, showed clouding over the lower half of the right lung field, with periosteal reaction of the lower six right ribs (Fig. K.W.1). The sinuses in the back were curetted and the granulation tissue showed typical colonies of actinomyces. In November, 1940, bi-weekly injections of actinomyces vaccine were begun, and increased to a dosage of 500 million fragments. The temperature quickly settled to normal and all the chest wall sinuses healed. The patient was discharged in December, 1950, while continuing with pot. iod., grains 30 t.d.s. In January, 1941, sinuses reopened, and in May she began to lose weight and developed a continuous

cough. She was readmitted to hospital in September, 1951, in poor general condition and suffering discomfort, but no pain, from multiple sinuses on both sides of the back. There was marked flattening of the right chest with severe scoliosis to the left side. The sinuses in the back, of which there were at least 30, were each surrounded by dark reddened skin of indolent appearance. Radiographs of the chest at that time showed widening of the mediastinum not unlike the appearance of a mediastinal sarcoma. The patient never complained of pain but steadily wasted and died on December 11, 1941. Post-mortem examination showed complete involvement of both lungs with actinomycosis. The oesophagus was found to be intact but surrounded by fibrous tissue. The liver and spleen were congested and showed the typical picture of amyloid disease.

This case illustrates several important characteristics of the disease. The first specimen of pus was sterile on culture and only later was the diagnosis confirmed by anaerobic culture and section of the granulation tissue. The formation of multiple chest wall sinuses which healed and broke down again is typical. The periosteal reaction of several adjacent ribs in the absence of an empyema is the only radiological appearance which is pathognomonic. Pain, which is generally a feature, was absent in spite of many chest wall sinuses. Post-mortem examination showed amyloid disease in the liver and spleen, a condition often associated with actinomycosis. The marked improvement while the patient was having vaccine therapy is in agreement with the experience of other workers, but almost invariably a relapse occurs. The marked peri-oesophageal fibrosis which was found at necropsy may have been the reaction to the

primary portal of entry of the actinomyces through a temporary abrasion in the oesophageal mucosa.

EXTENSION FROM ABDOMINAL ACTINOMYCOSIS

We have included two case histories under this heading. The first is an example of abdomino-thoracic actinomycosis originating in an appendix abscess; the second resulted from abdominal trauma and was one of the first cases to be treated in this country with penicillin.

Mrs. I. W., aged 49 years, a housewife, had a perforated appendix removed in September, 1941, and was discharged a month later with her wound healed. In November, 1942, she developed a right-sided empyema which was drained by rib resection and she was discharged with the wound healed in April, 1943. In May, 1943, she developed abscesses in the right groin and umbilicus. These subsided on conservative treatment until December, 1943, when the groin abscess required incision and drainage. Omentum was lining the deep surface of the abscess and there were many sinuses extending into the abdominal wall. In May, 1944, a further abscess was drained and found to involve the rectus sheath. In September, 1944, she developed pneumonia and was treated at home with sulphapyridine until October 5, when she was readmitted to hospital with a large left pleural effusion containing no organisms and sterile on culture. She was coughing up 1 oz. of mucopurulent sputum daily, but the fingers were not clubbed. There were multiple discharging sinuses in both lower quadrants of the anterior abdominal wall. Aspiration of the chest produced straw-coloured fluid, and both this and the sputum contained typical sulphur granules which grew *Actinomyces israeli* on anaerobic culture. The pleural fluid later became purulent and offensive. Intramuscular penicillin was begun on November 17 and 200,000 units was given daily until December 6 when a total of 3,800,000 had been given. The empyema was also aspirated on eight separate occasions and a total of 346,000 units of penicillin was injected into the pleural cavity. The induration of the abdominal wall had disappeared and all the sinuses had healed; on January 11, 1945, the empyema was drained by rib resection. In May, 1945, she complained of pain across the shoulders, and coughed up some blood-stained sputum which contained sulphur granules; systemic penicillin was begun on June 1 and 200,000 units was given daily until June 22 when 4,200,000 units had been administered. She was discharged in July with a tube still *in situ*. She was readmitted on October 1, 1945, feeling very fit, but coughing up 1 oz. of purulent sputum daily which still contained the typical Gram-positive branching filaments of *Actinomyces israeli*. Her general condition was excellent and the abdominal sinuses had remained healed. A third course of systemic penicillin was begun and 280,000 units was given daily for about three weeks, making a total of 5,880,000 units, and for the three courses of 13,880,000 units. She was dis-

charged on November 23, 1945, in spite of still having *Actinomyces israeli* in the sputum; the latter were evident until May, 1946, when the cough and sputum finally ceased. In October, 1946, the sinus had not healed, and the small residual empyema cavity was therefore re-drained. Section of the thickened pleura did not show actinomycosis or tuberculosis. On December 12, 1946, there was still a small residual empyema cavity, which was finally closed by a Roberts operation. The patient was discharged with all wounds healed on January 5, 1947, and when she last attended as an out-patient on March 5, 1956, she appeared in excellent health without cough or sputum, and all the wounds had remained healed.

This case illustrates the time interval which may elapse, and may be as long as two years, between the abdominal and thoracic infections in this disease. This patient's disease was protracted by the three short courses of penicillin which she received and by the small total dosage.

C. B., aged 22 years, a police clerk, while serving in the Army had a hand grenade, which he was holding in his left hand, detonated by a bullet on November 2, 1943. The left arm was blown off above the elbow and the left chest wall was riddled with small pieces of metal, a small fragment penetrating the abdomen and giving rise to a pneumoperitoneum. He recovered from these wounds, but while on disembarkation leave developed severe pain in the back and was admitted to hospital on January 12, 1944. On examination he had a temperature of 103° F. and a tender swelling over the left eleventh rib. This was explored, but no cause found; a week later a portion of the eleventh rib was resected and a localized subphrenic abscess was drained. After drainage he was given a course of sulphadiazine and several fresh blood transfusions; his temperature remained unsettled and in March, 1944, a left lumbar abscess was incised and offensive, thick pus was found to be tracking from the perinephric region, as well as from the previously drained subphrenic abscess. In April a collection of pus was drained beneath the left costal margin. Afterwards he was given another course of sulphamezathine and the left chest was needled in many places but no pus found. On May 23, 1944, he was transferred to another hospital and on examination looked thin and pale with a temperature of 100° F. He produced 3 oz. of purulent sputum daily, but the fingers were not clubbed. He developed more sinuses around the left costal margin, and finally sulphur granules were found in the discharge and in the sputum, both of which grew *Actinomyces israeli* on anaerobic culture in the presence of carbon dioxide, this particular strain being fully sensitive to penicillin. Radiographs at that time showed metallic foreign bodies and an opacity in the region of the left lower lobe; the left diaphragmatic outline was obscured. A sinogram demonstrated the ramifying subphrenic abscess and three external sinuses. By the end of June his general condition was deteriorating and there was loss of weight. He had been running an evening

temperature up to 101° F., and was coughing up 3 to 5 oz. of purulent blood-stained sputum daily. On June 26 systemic penicillin was begun and 120,000 units given daily for 15 days. His temperature fell to 98.4° F. in the evenings, and by the eleventh day his cough and sputum had disappeared. On June 26 he weighed 9 st. 4 lb. and was allowed to get up, but 10 days later his temperature rose again and the discharge from the sinuses increased. He was given a course of sulphamezathine for four days and then systemic penicillin was started again, 200,000 units being given daily for 30 days. The total dosage for the two courses was 7,800,000 units. On completion of treatment the sinuses had healed and he weighed 10 st. 10 lb. Since then he has attended as an out-patient, and when last seen, in October, 1956, he was working as a policeman and weighed 13 stones. He has had no further trouble with his chest and a radiograph shows complete clearing of the left lung field, except for obliteration of the costophrenic angle and a residual metallic foreign body.

This patient's history, previously reported by Roberts and others (1945), demonstrates the danger of a relapse if therapy is discontinued as soon as a satisfactory clinical response has been obtained. In the week before starting penicillin therapy this man was dying, and 12 years later he is cured of this disease.

EXTENSION FROM CERVICO-FACIAL ACTINOMYCOSIS

J. W., aged 43 years, a painter and decorator, developed a cold and pleuritic pain in the right chest in April, 1949. Radiographs showed a right pleural effusion, and he was admitted to hospital on July 22, 1949. He gave a history of an actinomycotic infection of the right side of the jaw in 1938, and had had treatment with iodides and penicillin on various occasions. The right temporo-mandibular joint was almost completely ankylosed and there was a discharging sinus over the jaw. He was in good general condition and there was no clubbing of the fingers or history of haemoptysis. The sputum was negative on several occasions for both tubercle bacilli and mycelial filaments. It was impossible to bronchoscope the patient as his jaw would only open for $\frac{1}{2}$ in., but a tentative diagnosis of carcinoma of the right lower lobe bronchus was made. A right thoracotomy was performed on August 9, 1949, when the pleura was densely adherent and a rubbery mass felt in the middle and lower lobes. There were no enlarged mediastinal glands and a right middle and lower lobectomy was done. The day after operation the patient developed a high fever and the pleural fluid grew a penicillin-resistant *Staphylococcus aureus*. Despite penicillin therapy a bronchopleural fistula developed on the tenth day and was followed by fatal aspiration pneumonia.

At necropsy the central part of the lower lobe contained a firm, greyish-white tissue stippled with carbon pigment. There were many subpleural yellowish areas resembling small foci of a variable degree of fibrosis of the surrounding lung tissue. Histological section showed

areas of acute and chronic inflammation, the latter containing masses of granulation tissue heavily infiltrated by round cells. There were also several small bronchopneumonic abscesses, and in the centre of several of these mycelial colonies were seen Gram-positive filaments identical with *Actinomyces israeli*. The left lung revealed a confluent staphylococcal bronchopneumonia with multiple abscess formation, in one of which there was a matted mycelium of Gram-positive branching filaments.

The pulmonary infection which followed 11 years after infection of the jaw may have spread, by direct extension by way of the tissues of the neck and thoracic inlet, or by inhalation to the basal bronchi from the mouth. This demonstrates an unusual diagnostic difficulty. Bronchoscopy, which was prevented by the ankylosis of the temporo-mandibular joints, would have led to the correct diagnosis and subsequent therapy with systemic penicillin, thus obviating surgery in this phase of the disease.

METASTATIC: PYAEMIA

C. C., aged 42 years, a fitter, complained of pains in the calf muscles in January, 1947. He was admitted to hospital in March and a series of abscesses was opened in both legs, buttocks, back, and chest wall. In April he developed a left-sided pleural effusion with consolidation of the left lower lobe. He was treated with N.A.B. and a staphylococcal vaccine without any improvement. In December, 1947, a clinical diagnosis of actinomycotic pyaemia was made as no specific organisms had then been isolated and a course of 1 mega unit of crystalline penicillin daily was given for six weeks. This resulted in improvement in his clinical condition, but healing of all the sinuses was only obtained after a course of radiotherapy. During this treatment a micro-aerophilic *Actinomyces israeli* was eventually cultured. He remained fit until July, 1952, when he complained of pain in the left upper chest associated with cough and purulent sputum. In August a radiograph showed an opacity at the left apex which was thought to be tuberculous and he was admitted to hospital in October, 1952 (Fig. C.C.1). His general condition was good, although his haemoglobin was 77% and his fingers showed early clubbing. He was coughing up 1 oz. of purulent sputum daily, which grew a micro-aerophilic *Actinomyces israeli* morphologically and culturally similar to the organism found in 1947. He was given a six weeks' course of 2 mega units of crystalline penicillin eight-hourly; after five days of this treatment his pain had disappeared and he had no cough or sputum. This course was followed by a further six weeks of 600,000 units of distaquaine penicillin daily, making a total continuous course of 273 mega units. He was discharged in December, 1952, and has remained well and at work ever since. He last attended the Out-patient Department on July 25, 1956, when a chest radiograph was clear.

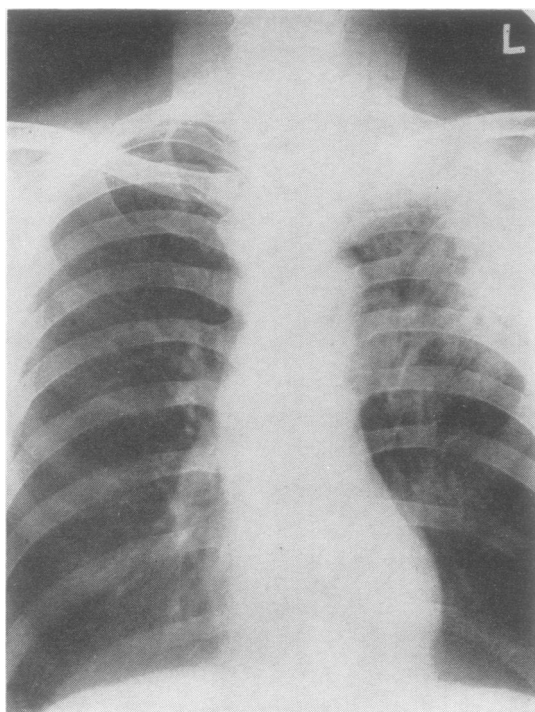


FIG. C.C.1

Actinomycotic pyaemia is rare and generally results from infection with the anaerobic organism *Actinomyces israeli*; cases have been reported due to the aerobic organism *Nocardia asteroides*. Spread by the blood stream invariably proved fatal before the introduction of antibiotics.

METASTATIC: CHEST WALL

M. B., aged 10 years, complained of feeling tired in February, 1947. An abscess later developed on the left anterior chest wall, and she was admitted to hospital where this abscess was drained and what was thought to be a tuberculous rib resected. The wound did not heal, and when she was readmitted to hospital in February, 1948, there were several granulating areas over the lower half of the chest wall anteriorly (Fig. M.B.1). These granulating areas were tender and histological section from a biopsy showed the typical colonies of *Actinomyces israeli*. She weighed 4 st. 7 lb. and her haemoglobin was 80% before treatment was begun with daily intramuscular injections of 1 million units of penicillin for 21 days. The granulating areas diminished in size and healed (Fig. M.B.2). She began to put on weight and her general health improved. Her condition has remained satisfactory up to 1956.

This case illustrates the typical chest wall lesions and emphasizes that they are usually extremely painful.

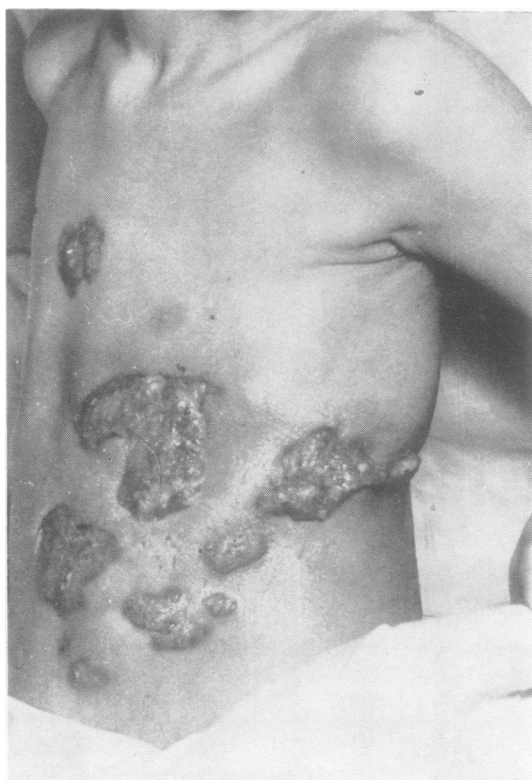

FIG. M.B.1

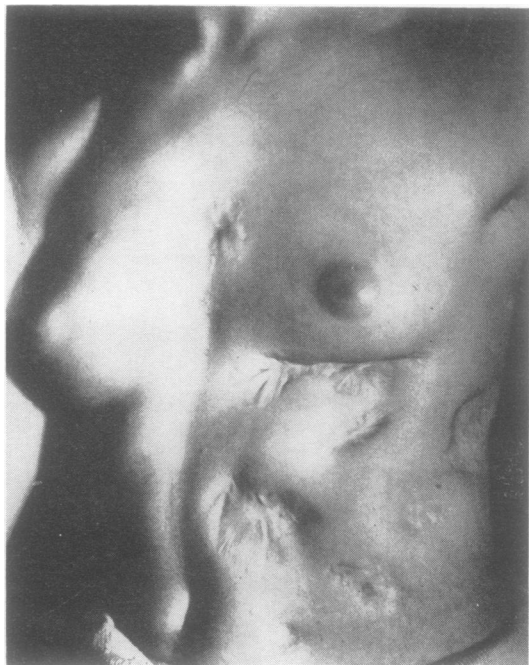


FIG. M.B.2

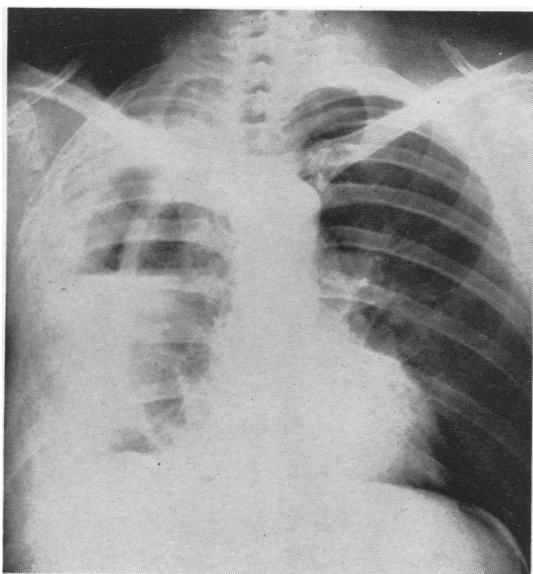


FIG. R.H.1

PULMONARY TUBERCULOSIS AND ACTINOMYCOSIS

R. H., a man of 32 years, developed bilateral pulmonary tuberculosis in India in October, 1944. His sputum was positive for tubercle bacilli. In February, 1956, a right artificial pneumothorax was induced and two thorascopies carried out. In March, 1946, he had a phrenic crush. In October, 1946, he developed multiple sinuses in the chest wall. He returned to Great Britain in January, 1948, and at this time thick pus was aspirated from the chest from which anaerobic *Actinomyces israeli* was cultured (Fig. R.H.1). The pleura was drained and a thoracoplasty carried out in October, 1948. The wound was healed five months later. This man has remained well with no evidence of active disease in the chest.

This case illustrates the simultaneous occurrence of two chronic granulomata; the actinomycotic infection remained confined to the pleural cavity.

EPIDEMIOLOGY AND PATHOLOGY

GEOGRAPHICAL INCIDENCE

Thoracic actinomycosis has been reported from many different countries, but particularly from Europe and the United States of America. Poncet and Bérard (1898) reported a high incidence in Germany, and Robinson and Tasker (1949) a higher incidence in southern California than in other states of America.

OCCUPATIONAL INCIDENCE

For many years the view was held that country dwellers were more prone to this condition than

town dwellers. This may be true in the case of cervico-facial disease, but it is not so for pulmonary infections. In this series there were 80 town dwellers and five country dwellers.

THORACIC INCIDENCE

All authors agree that approximately 15% of human actinomycotic infections affect the thorax (Poncet and Bérard, 1898; Bell, Mantell, Netzer, and Jaffe, 1944; Foulerton, 1913; Cope, 1930). Sokolow (1889) reported a 30% thoracic incidence from Russia, while Harbitz and Grondahl (1911) found a 23% incidence in 87 cases from Norway.

It has been thought that the majority of thoracic infections have resulted from secondary involvement from the abdomen, and Good (1930) reported 15 out of 16 thoracic cases to be secondary in origin. We have not found this to be so in the present series, in which 70 were primary infections within the chest and 15 the result of secondary spread.

AGE AND SEX INCIDENCE

Males are affected more often than females, and various figures are quoted, ranging from 4:1 (Sanford and Voelker, 1925; Schmitt and Olsen, 1941) to equal proportions (Colebrook, 1921). In the present series three times as many males as females were affected. The majority of cases occur after the age of 20 (Good, 1930); but the disease can start at any age and the youngest reported case was a child of 28 days who died from an actinomycotic lung abscess (Lemon, 1926). In the present series the youngest patient was a girl of 3½ with a lung abscess, and the oldest a man of 76 with an empyema.

	0-10	11-20	21-30	31-40	41-50	51-60	61-70	71-80
Age incidence ..	6	17	8	19	22	9	2	2
Sex	Males: 64				Females: 21			

MORBID ANATOMY AND HISTOLOGY

Pulmonary actinomycosis is a chronic disease which simulates pulmonary tuberculosis, and the morbid process is usually far advanced when the earliest symptoms become manifest. The primary lesion is either in the bronchioles, or in the peribronchial tissues, or in the lung parenchyma; it is suppurative and proceeds to abscess formation that may be extensive and is attended by interstitial pneumonia with fibrosis. The initial lesion is seldom seen save when one or more lung lobules become infected from an adjacent abscess. Then the lesion is bronchopneumonic—of the chronic suppurative type—with marginal pneumonia that

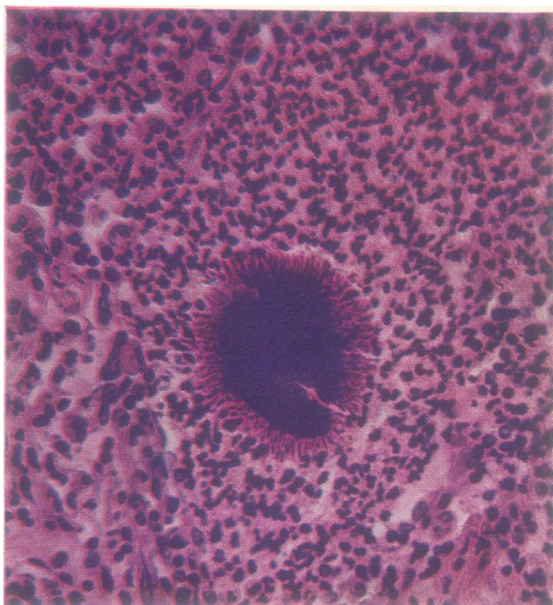


FIG. 1

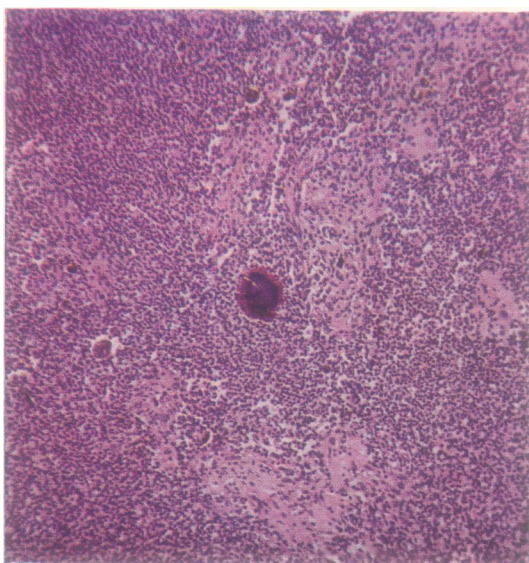


FIG. 2

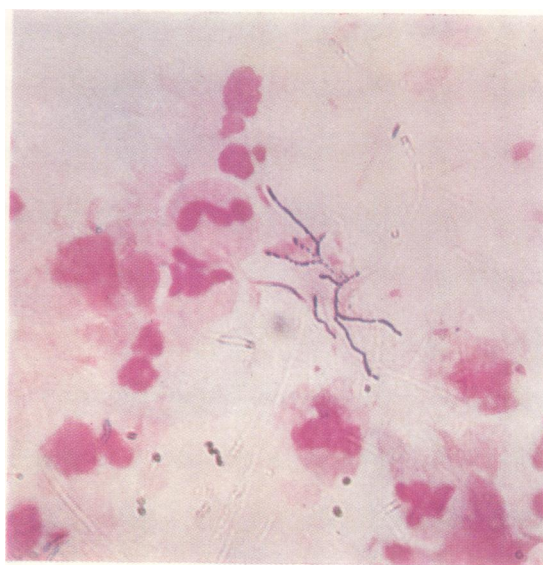


FIG. 5

FIG. 1.—A colony of actinomyces in the lung. In the centre is a dense mass of mycelial filaments; the periphery shows very distinct radially arranged "clubs" stained red. The surrounding cells are polymorphonuclear leucocytes. Haemalum and eosin, $\times 350$.

FIG. 2.—A colony of actinomyces in the margin of a suppurative focus in the lung. Most of the surrounding cells are polymorph leucocytes; a few pigmented macrophages are present. Haemalum and eosin, $\times 75$.

FIG. 5.—This sputum shown Gram-positive branching mycelial filaments among pus cells. Gram's stain, $\times 960$.

later organizes with resulting fibrosis. The disease progresses thus, from lobule to lobule, and by extension of the suppurative process by continuity, so that eventually multiple abscesses with intervening dense fibrous tissue occupy a large part of a lobe and may present as a coarse honeycomb, an appearance that is characteristic of this disease when it occurs in the liver.

Actinomycosis is described as occurring more frequently in the lower than the upper lobe, but both or all lobes of a lung may be affected and more than one segment of a lobe may be involved. Thus in the case illustrated (Fig. C.D.3) there are small subpleural chronic abscesses, with fibrosis of the lung, in the apical segment of the upper lobe and the apical segment of the lower lobe. In addition, in the posterior segment of the upper lobe there is a more extensive conglomeration of suppurative foci comprising distinct abscesses, suppurative bronchopneumonic lesions some of which are progressing to abscess formation and accompanying fibrosis. So compact was this large conglomerate that radiographically it was considered to be a tumour near the hilum.

The pleura is involved and becomes thickened and fibrosed, especially in relation to subjacent suppuration when local intrapleural abscesses or empyema may result. But even in the absence of suppuration immediately near the pleura, the latter becomes fibrosed and thickened in the same way as the fibrous tissue septa of the lung that connect with it become fibrosed from extension of the interstitial pneumonic fibrosis. The peribronchial fibrosis results from the same inflammatory process.

Histologically all the features of the disease as described are seen—the chronic suppurative foci with marginal pneumonia that later organizes with resulting fibrosis, suppurative bronchopneumonia, etc. Some of these histological features are illustrated in the accompanying photomicrographs (Figs. 1, 2, 3, 4). The pus in the abscesses is mainly polymorphonuclear, although round cells and macrophages, some with haemosiderin and other pigments, are present. The characteristic and diagnostic feature is the presence of one or more colonies of actinomyces that can be seen in routine sections, stained with haemalum and eosin, with the same ease or difficulty that attends their discovery as "sulphur granules" in pus from lung or other abscesses, or from sinus tracks. The colonial appearances are distinctive; the central loose or dense mass of branching mycelial filaments is stained blue with haemalum; the peripheral, radiate, club-like swollen outer ends of the filaments are stained red with eosin (Figs. 1, 2). The colonies

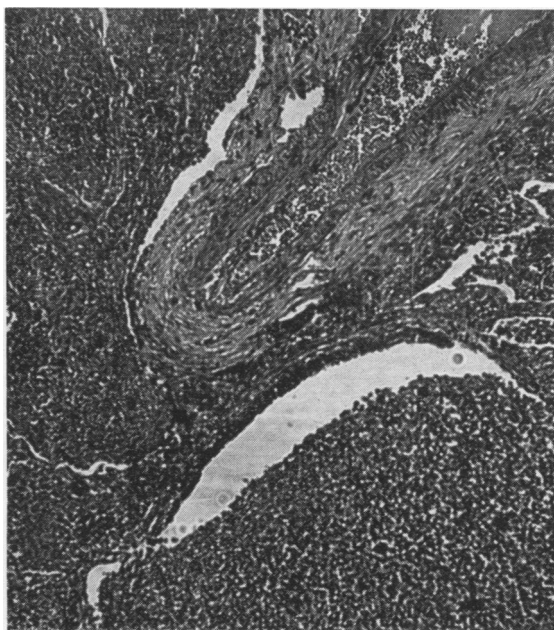


FIG. 3.—The suppurative process has destroyed all but one part of the wall of this bronchus; the columnar epithelial lining remaining is seen on the left of the lumen, which is otherwise occupied by pus cells. Adjacent alveoli show cellular exudate. The whole picture is one of suppurative bronchopneumonia. Haemalum and eosin, $\times 150$.

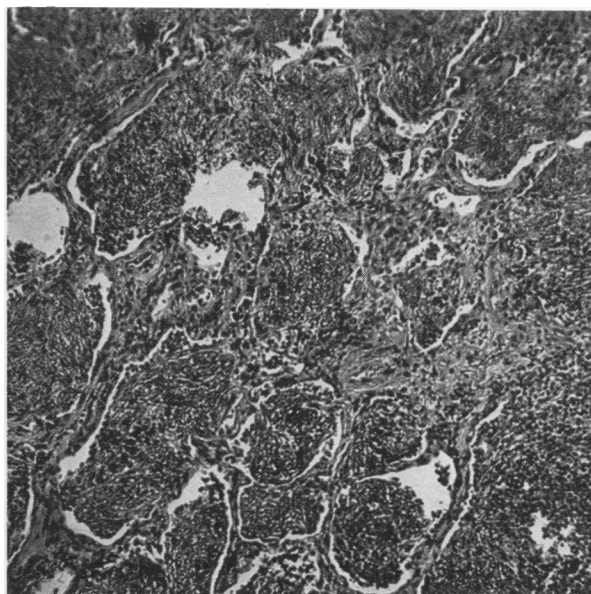


FIG. 4.—These alveoli near a suppurative focus (lower left) show the contained exudate being organized by ingrowing capillaries and fibroblasts. This granulation tissue leaves a residue of fibrous tissue which condenses to form the diffuse fibrosis around suppurative foci. Haemalum and eosin, $\times 150$.

are easily identified in Gram-stained preparations or in sections stained by a modified Ziehl-Neelsen method.

The sputum in patients suffering from pulmonary actinomycosis is often purulent and may contain colonies of the organisms as "sulphur granules"; more frequently, however, branching mycelial filaments may be found (Fig. 5).

COMPLICATIONS

Microcytic anaemia which is occasionally severe, is a common complication of thoracic actinomycosis.

Cerebral abscess and pyaemia are rare complications and the primary infection is usually in the thorax (West, 1897; Lidbeck, 1942); they are particularly liable to occur when there is cardiac involvement (Dean, 1912).

Amyloid disease develops in those patients who have a long history of thoracic actinomycosis, and occasionally may occur as an acute condition early in the disease (Tubbs and Turner, 1937).

PHYSICAL SIGNS AND SYMPTOMS

SIGNS

The only physical sign which could be described as diagnostic for this condition is the nature of the chest wall sinus. The sinus tends to heal over for a few days and then breaks down and discharges again (Fig. F.T.1). Sulphur granules can occasionally be seen with the naked eye in the discharge, and the granulation tissue around the sinus is exuberant, vascular, and painful to touch. With a chronic pyogenic empyema a sinus may appear and remain single for many years, but in thoracic actinomycosis there is generally multiple sinus formation at an early stage.

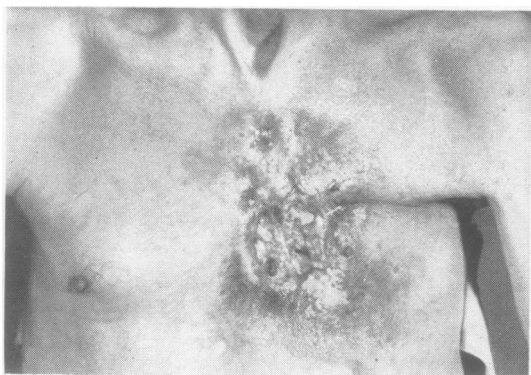

Fig. F.T.1

SYMPTOMS

Pain is the common presenting symptom, and 43 cases in this series started in this way. There are four different types of pain from which these patients suffer, depending upon the variety of the disease. Pleuropulmonary infections in which the pleural cavity is obliterated often present with rheumatic pain, while those who have an empyema may present with an acute pleurisy. The mediastinal cases complain of a continuous retrosternal aching, while the chest wall lesions are painful to touch.

Cough occurs at some stage of the disease, and is associated with purulent sputum.

Haemoptysis is unusual; but large haemoptyses can occur when a lung abscess is present.

A few cases presented with lassitude before chest symptoms developed.

DIAGNOSIS

CLINICAL

The clinical manifestations of thoracic actinomycosis are protean. The diagnosis may be simple in cases presenting with characteristic painful chest wall sinuses; sulphur granules may be seen in the discharge, bacteriological examination of which may reveal the causal organism. Biopsy from the sinus may demonstrate the characteristic tissue changes of actinomycosis. Similarly, cases presenting as empyemas may be easy to diagnose. But many present with indefinite symptoms and bizarre radiological appearances; it is in this group that diagnostic difficulties arise. It may be impossible to arrive at a definite diagnosis until material is obtained for examination at thoracotomy. Despite this, we urge that an attempt be made to reach a diagnosis before chemotherapy or antibiotics are used in treatment, because once these have been administered the difficulties of making an accurate diagnosis can be increased. This is illustrated by the following case:

A. B., a girl of 22 years (Fig. A.B.1), developed a productive cough, rapidly followed by pain in the chest and thickening in the tail of the right breast. A week later there was a hard mass in the breast and a tentative diagnosis of sarcoma was made. At this time she showed a radiological opacity in the right upper lobe. Her sputum contained no pathogenic organisms. Penicillin was given for three weeks, and after this the breast mass disappeared and the pulmonary shadow diminished. Two weeks later the breast swelling returned and an abscess discharged spontaneously; the pus from this abscess grew *Actinomyces israeli*. Further penicillin was then given, resulting in complete healing.

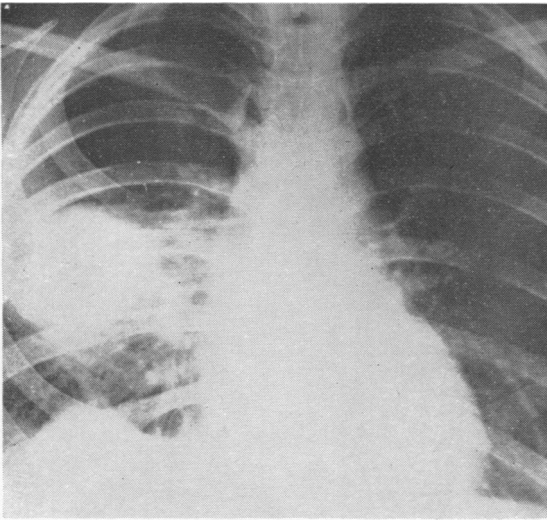


FIG. A.B.1

Thoracic actinomycosis may, by involvement or irritation of lower intercostal nerves, cause abdominal pain and simulate upper abdominal disease.

A man of 20 was admitted to hospital with acute epigastric pain, and a diagnosis of right anterior sub-phrenic abscess was made. The abdomen was explored with negative findings. After the wound had healed he developed chest pain, and radiographs showed middle lobe consolidation (Fig. D.L.1). The wound broke down and discharged foul pus from which *Actinomyces israeli* was grown. This organism was also cultured from his sputum. Lipiodol injection demonstrated that the

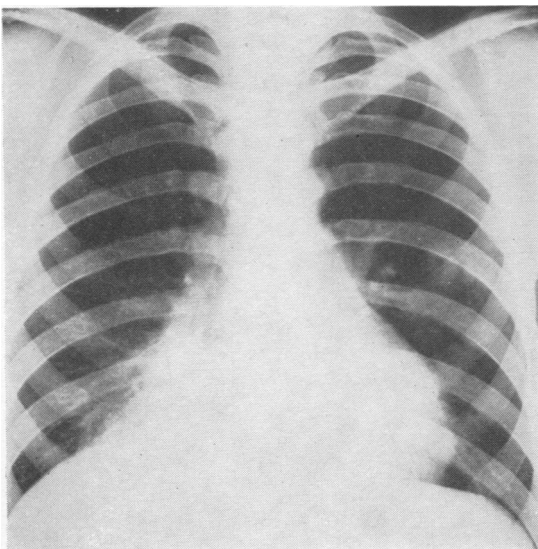


FIG. D.L.1

abdominal sinus passed through the diaphragm into the middle lobe. This man was cured by penicillin therapy.

The following case illustrates another difficulty which may be encountered.

E. M., a woman of 49, developed a morning cough, followed two months later by haemoptysis. When first seen four months after the onset of symptoms she was dyspnoeic and had lost weight. A radiograph taken in November, 1949, showed a left hilar opacity with collapse of the lingula and an ovoid right lower lobe shadow (Fig. E.M.1). Bronchoscopy was normal and sputa were negative for tubercle bacilli and malignant cells. The diagnosis made at this time was bronchial carcinoma with a metastasis in the right lower lobe. Five months later she developed chest wall abscesses. Pus aspirated from these gave a culture of *Actinomyces israeli*. She recovered completely with penicillin therapy.

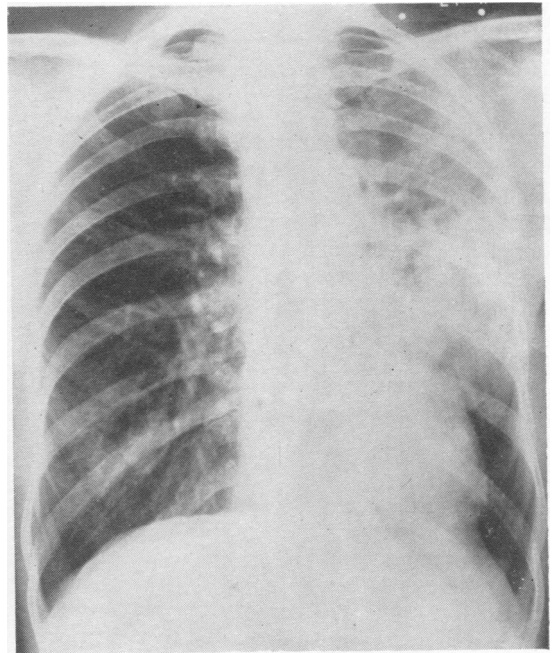


FIG. E.M.1

BACTERIOLOGICAL

The technical details of laboratory diagnosis have been described by Garrod (1952b). We are concerned in an attempt to indicate certain basic requirements necessary before a diagnosis of clinical thoracic actinomycosis can be made on the basis of bacteriological findings. The finding of actinomyces in the sputum or in bronchoscopic aspirates does not necessarily mean that the patient is suffering from actinomycosis. *Actinomyces israeli* is a normal inhabitant of many human mouths, in dental tartar,

tonsillar crypts, and carious teeth. Kay (1947) reported finding actinomyces in 109 of 240 cases of pulmonary suppuration and also stated that approximately 50% of bronchiectatics have actinomyces in their sputum. Many of these had resections carried out without untoward complications. We believe that this is a misconception of the disease and that in these patients the actinomyces played no part as pathogens. As has already been shown, the tissue response to actinomycotic infection is specific, and unless this can be demonstrated in an excised portion of tissue the diagnosis is not tenable. Garrod (1952b) has emphasized that sputum for bacteriological examination should first be washed to eliminate saliva and mouth organisms. In his series of 40 cases of pulmonary suppuration 15 yielded no actinomyces on culture from washed and unwashed material, 25 grew an actinomyces from an unwashed but not from a washed inoculum, while nine grew an organism from both. The actinomyces cultured in this series had the characteristics of the aerobic form *Actinomyces naeslundii*. Garrod goes so far as to state that unless the sputum contains actinomycotic granules it is doubtful whether a diagnosis should ever be made on sputum findings or even on bronchial aspirates. The examination of pus in bulk may reveal the sulphur granule, and by staining methods and anaerobic culture of these the specific organism *Actinomyces israeli* may be identified. In the very rare cases in which clinical pulmonary infection is due to a nocardia the organism will be grown by aerobic culture.

RADIOLOGICAL

Many radiological appearances have been described as typical of pulmonary actinomycosis. These assertions are not supported by the facts of the present study. The only characteristic radiological changes produced by thoracic actinomycosis are the result of bone change. These were first noted by Staub-Oetiker (1921), who described periostitis of several adjacent ribs in the presence of a pulmonary infection without empyema. These appearances enabled the radiologist to make a correct diagnosis in the case cited (Fig. A.E.1).

Bone involvement with actinomycosis results in bone destruction simultaneously with new bone formation. Fig. F.T.2 shows sternal involvement in a man who had suffered from actinomycosis of the chest wall for many years; he died of secondary haemorrhage from the internal mammary artery. The radiological appearance of the lungs is not diagnostic. Since 1921 several authors, including Koerth, Donaldson, and Pinson (1942) and Kirklin and Hefke (1931), have described the radiological

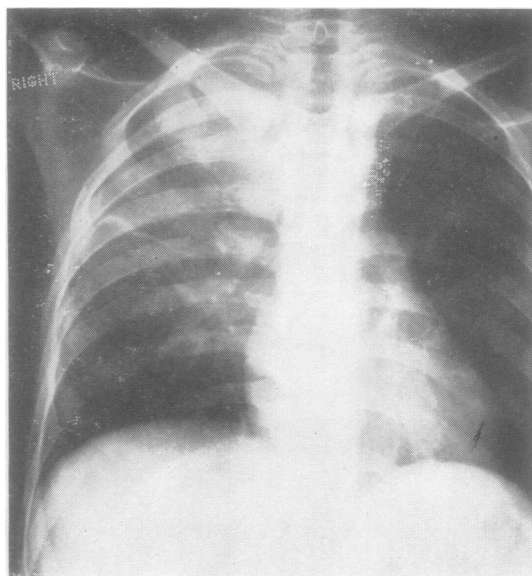


Fig. A.E.1

appearance of thoracic actinomycosis, but none has considered any appearances of diagnostic significance other than periostitis of several adjacent ribs in the absence of an empyema. With these findings we are in full accord, and would urge that the possibility of actinomycosis be kept in mind when considering the significance of puzzling shadows in chest radiographs.

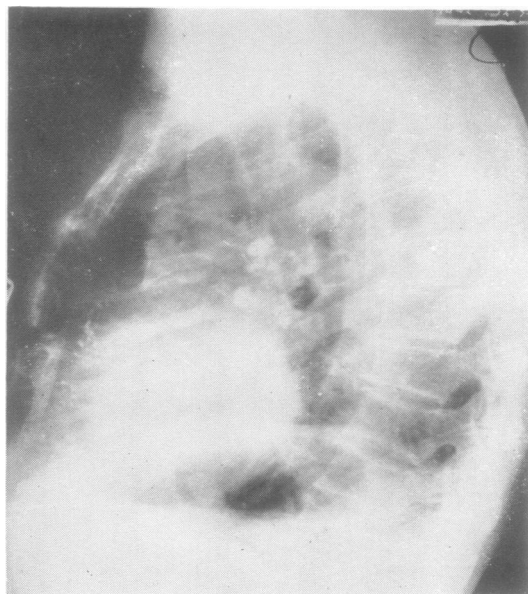


Fig. F.T.2

TREATMENT

GENERAL MEASURES

Many patients suffering from actinomycosis are in poor general condition as the result of long-continued infection and pain. They may be anaemic and have lost weight as a result of protein depletion. In the present series a haemoglobin reading of as low as 50% to 60% was commonly obtained before specific treatment was begun. Adequate protein and vitamin intake together with fresh blood transfusion or administration of iron as indicated are of importance. Pain is relieved as soon as penicillin has been administered.

SPECIFIC MEASURES

With the advent of chemotherapy and antibiotics many of the treatments previously employed have become obsolete. Various sulphonamides have been used in the treatment of thoracic actinomycosis—where one failed success was often achieved by a combination of others and particularly by simultaneous administration with penicillin. At the present time sulphonamides have been replaced by penicillin as the treatment of choice.

CHLORAMPHENICOL, AUREOMYCIN, TERRAMYCIN, AND ACHROMYCIN.—We have no experience of the use of chloramphenicol or aureomycin in treating thoracic actinomycosis. The danger and discomfort to the patient attendant on the use of these drugs over a long period make us feel that it would be unjustifiable to employ them in preference to penicillin. The same objections apply to terramycin or achromycin, both of which are liable to cause diarrhoea and possibly serious staphylococcal enteritis. Terramycin has been used as an adjunct to penicillin in two cases in the present series. In one of these the patient maintained that the chest wall sinuses remained healed for longer with this drug than with penicillin. Penicillin is the most effective agent yet produced. In the earlier cases in this series relatively small doses were used, yet many of these patients were cured. Many more, however, showed temporary improvement only and later relapsed. In the present series relapses have occurred in patients having as much as 4 mega units of penicillin daily. We feel that it is important to give a sufficient dosage for long enough to make certain of curing the patient at the first attempt. We recommend for an adult 6 mega units of crystalline penicillin daily (2 mega units eight-hourly) during the period in hospital (six weeks), followed by an out-patient course of 600,000 units daily for a similar period, making a total of 277 mega

units over a three-month period. Cases treated in this way have shown neither relapse nor sensitivity reaction. In children the dosage will require suitable modification.

STREPTOMYCIN.—We have no personal experience of the exclusive use of this drug in the treatment of actinomycosis. Studies *in vitro* by Boand and Novak (1949) demonstrated that penicillin has a greater effect on *Actinomyces israeli* than has streptomycin. These authors conclude that, in view of the long duration of antibiotic treatment necessary in actinomycosis, the risk of development of streptomycin-resistant strains would be high.

Garrod (1952a) has studied the effect of five different antibiotics *in vitro* upon 12 strains of *Actinomyces israeli*. The therapeutic response to a particular antibiotic *in vivo* is more to be relied on in the treatment of actinomycosis than its behaviour *in vitro* suggests. Again, in view of the long-continued treatment necessary, we reiterate that penicillin is the drug of choice. We do not infer that studies *in vitro* are valueless, but that they may be misleading. The development of an insensitive strain of organism during antibiotic therapy is a source of anxiety, and one case in our series demonstrates that this may happen despite adequate therapy.

D. S., a man of 17 years, had an actinomycotic subphrenic abscess drained. *Actinomyces israeli* cultured from the pus was sensitive to penicillin (inhibiting concentration 0.029 units per ml.). He was treated with penicillin (100 mega units in 10 weeks), but his condition deteriorated. Further sensitivity tests at this time showed that the organism was now approximately 10 times as resistant as it had been at the beginning of treatment. This man eventually died from acute amyloid disease and had actinomycotic abscesses in both lungs, liver, and abdominal wall.

The clinical response to penicillin may be excellent even with strains of *Actinomyces israeli* resistant *in vitro*.

SURGICAL

Thirty patients in the present series had some form of surgical treatment. In many of these the diagnosis was not known at the time of operation. The majority had empyemas (20 cases); seven patients were treated by lung resection.

EMPYEMA.—A variety of methods were employed. The majority were straightforward empyemas, but one followed pneumonectomy for a non-actinomycotic lung abscess, while two were associated with tuberculous pyothorax. There were no deaths in the cases in which penicillin was used as an adjunct to surgery. Simple drainage was employed in seven

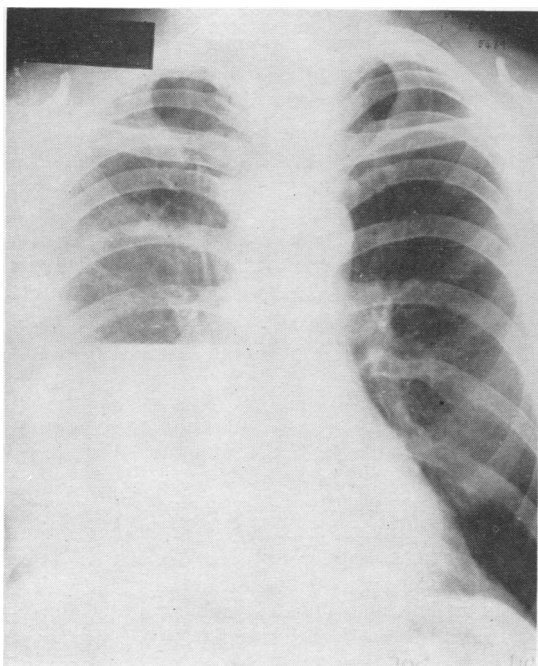


FIG. A.F.1

cases, one of which followed pneumonectomy. This man was alive and well three years after operation but cannot now be traced. Of the remainder, only two recovered, one of whom is well 13 years later. The other died of primary carcinoma of the colon five years after healing of the empyema. In the pre-penicillin era it seems likely that simple drainage of an actinomycotic empyema was curative if the lung lesion was of small extent and accessible to the oxygen available in the pleura, as for example when the empyema was due to rupture of a small subpleural lung abscess. This is exemplified by the following case.

A. F., a man of 53 years, gave a two months' history of pain in the chest, cough, and purulent sputum. He was admitted to hospital in 1942 with an encysted effusion and bronchopleural fistula (Fig. A.F.1). *Actinomyces israeli* was grown from both sputum and pleural pus. The empyema was drained and a small perforated lung abscess was seen. Final healing took place in May, 1943, seven months after drainage. In 1948 he died of carcinoma of the colon, proved by laparotomy. He had had no trouble with his chest since the healing of the empyema.

Drainage combined with penicillin was used in seven cases and is the standard method of treatment. All these patients were cured. The treatment of the empyema differed in no way from the usual.

J. McC., a man of 76 years (the oldest case in the series), was admitted in September, 1953, for incision of a chest wall abscess. Radiographs showed an encysted basal effusion with an inflammatory process in the right lung. *Actinomyces israeli* was grown from the abscess. He was treated by penicillin for four weeks and drainage of the empyema, with a good result.

ASPIRATION WITH INTRAPLEURAL PENICILLIN REPLACEMENT.—We have records of three cases of empyema treated by aspiration and intrapleural penicillin, combined with systemic penicillin. In one of them streptokinase and streptodornase were used in addition. All are classed as cured.

E. B., a man of 34 years, was first seen in 1947 with haemoptysis, which was rapidly followed by dyspnoea and chest pain. He was admitted with a total left empyema from which $4\frac{1}{2}$ pints of pus were aspirated containing *Actinomyces israeli* (Fig. E.B.1). Systemic penicillin was given for two weeks (total, 7 mega units). Eleven pleural aspirations were carried out with instillation of 300,000 units of penicillin on each occasion. He was discharged after three months in hospital. He was well in January, 1954, and was working as a brewer's drayman (Fig. E.B.2).

EXCISION OF EMPYEMA.—One case has been treated in this way, a boy, D. H., aged 12, who developed a chest illness a week after tonsillectomy and adenoidectomy. Twenty-two days after the tonsillectomy he was admitted with a localized left-sided empyema from which *Actinomyces israeli* was grown. The empyema was excised; no abnormality could be felt in the lung itself. He was given a total of 116 mega units of penicillin over 42 days and also 20 g. terramycin. He was discharged healed five weeks after the operation.

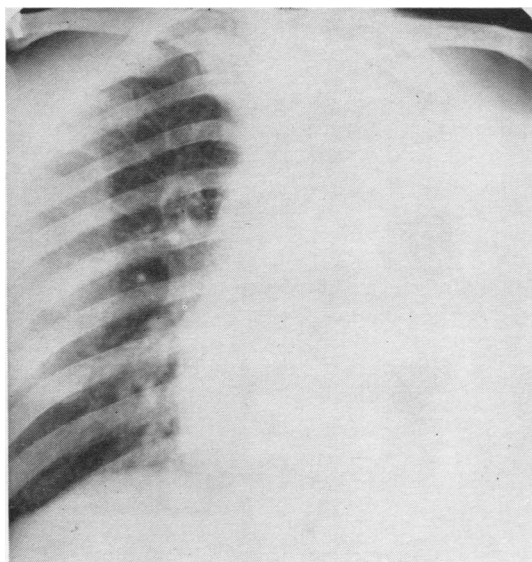


FIG. E.B.1

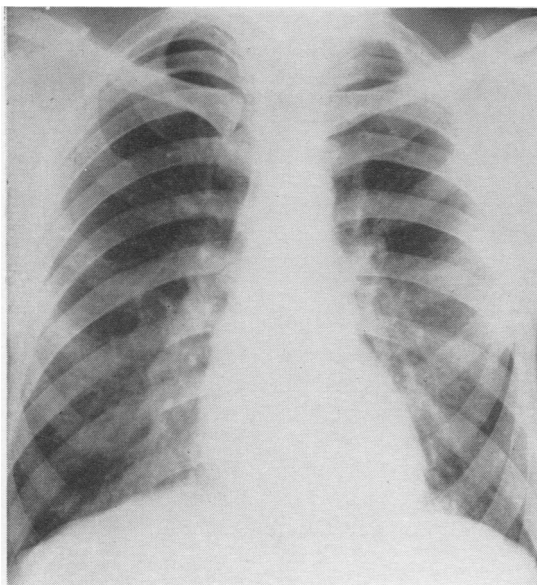


FIG. E.B.2

CASES SUBJECTED TO LUNG RESECTION.—The literature contains few references to the fate of patients with actinomycosis who have been subjected to lung resection. Kugel and others (1953) report three cases in which lobectomy or pneumonectomy was performed, all under erroneous pre-operative diagnoses: two patients were thought to suffer from bronchial carcinoma and the third from a chronic lung abscess. All three patients made a good recovery, although only one had penicillin for a significant period post-operatively. Reitter (1954) described two cases treated by lobectomy, one after prior treatment by chemotherapy, antibiotics, radiation, and drainage of lung abscess. Both patients recovered. Seven cases in this series were subjected to lung resection: in no case was a correct pre-operative diagnosis of actinomycosis made. Of these the following have been selected to illustrate some of the problems encountered in this group.

W. C., a man of 54 years, gave a history of cough and purulent blood-stained sputum for four months. Tomography demonstrated a cavity in the right upper lobe with thick, irregular walls. A diagnosis of breaking-down neoplasm was made and pneumonectomy carried out (August, 1948). Histologically the lesion was a typical actinomycotic abscess. He developed an empyema post-operatively which was treated conservatively. He remained well for over five years, but died suddenly after developing a bronchopleural fistula.

In the following case a supposed chronic lung abscess provided the indication for surgery.

C. F., a woman of 58 years, had had repeated haemoptyses of up to half a pint over a six-year period. A radiograph showed an ill-defined rounded opacity in the anterior segment of the left upper lobe. Bronchoscopy showed pus coming from the left upper lobe orifice and bronchography suggested a chronic lung abscess. At thoracotomy a densely adherent left upper lobe containing a stony, hard mass was removed (May, 1952). Her post-operative recovery was uneventful. She received 38 mega units of penicillin in the post-operative period. Histologically the removed lobe showed typical actinomycotic changes. This woman has remained free of chest symptoms for four years since operation and her chest radiograph shows no sign of disease.

Simulation of a chronic lung abscess provided the indication for surgery in the following case (the youngest in the series).

W. R., a girl of 3½ years, had a productive cough for six months with clubbing of the fingers and slight cyanosis. She was transferred from another hospital where foul pus was aspirated, allegedly from the pleura, and penicillin had also been given parenterally. She was transferred as an empyema and on admission was ill and febrile. Bronchoscopy showed evil pus pouring from the right lower lobe and bronchography considerable destruction of the right lower lobe bronchus. After a period of preparation thoracotomy was carried out in the prone position. As soon as the chest was opened and an attempt made to mobilize the densely adherent lung, respiratory obstruction necessitated bronchoscopy at which thick material was aspirated with difficulty. A middle and lower lobectomy was carried out (May, 1952). Her post-operative recovery was complicated by a wound infection and by slow expansion of the upper lobe. The child has remained well since 1952. Histologically this was an actinomycotic lesion with very dense fibrosis and several abscess cavities. A total of 7½ million units of penicillin was given over 18 days.

The following patient presented with repeated severe haemoptyses.

P. K., a youth of 19, suffered from repeated severe haemoptyses. These appeared to originate from the right middle lobe. An exploratory thoracotomy was carried out and the middle lobe removed (December, 1952). The lobe was bronchiectatic and contained an abscess cavity filled by a rugged calcified mass (Figs. P.K. 1 and 2). *Actinomyces israeli* was isolated from both the calcified material and the bronchi. The patient made an uneventful recovery.

RESULTS OF TREATMENT

The results of treatment have been difficult to assess because so few of these patients have been treated by a single method. Since 1948 most of these cases have been treated with antibiotics, combined when necessary with surgery, and the results show this method to be superior to all others.

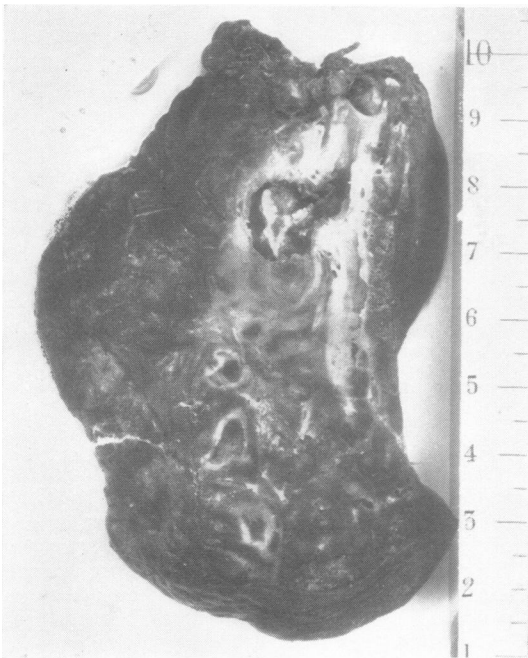

FIG. P.K.1

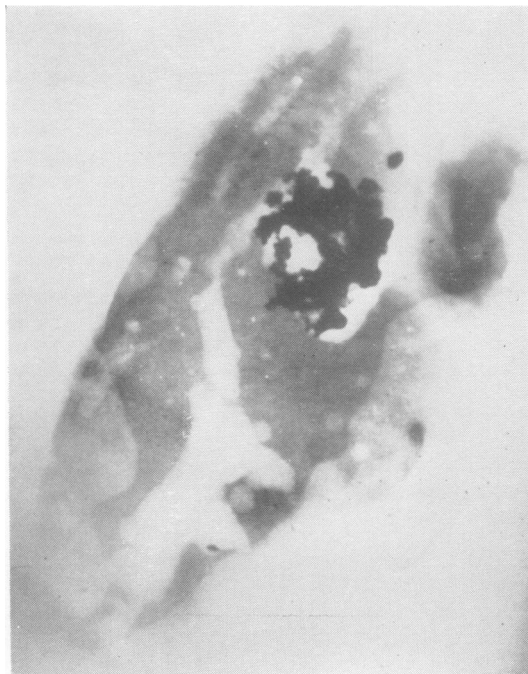


FIG. P.K.2

In assessing the results of treatment we have arbitrarily divided the patients into three groups. Those who did not receive treatment with either sulphonamides or penicillin are included in Group A. Group B comprises those patients who received less than a month's continuous sulphonamide therapy or 8 mega units of penicillin.

In the final group are included all whom we consider to have had adequate antibiotic therapy, although in many cases this has been less than we recommend.

RESULTS OF TREATMENT

<i>Pleuropulmonary</i>			
(a) Mainly pleural	18 cases	
A	7 (3 alive, 4 dead)	
B	1 (died of carcinoma colon)	
C	10 (10 alive)	
(b) Mainly pulmonary	27 cases	
A	11 (9 dead, 2 not traced)	
B	5 (5 dead)	
C	11 (8 alive, 3 dead)	
<i>Bronchopulmonary</i>			
(a) Lung abscess	7 cases	
A	3 (1 alive, 2 dead)	
B	1 (dead)	
C	3 (3 alive)	
(b) Simulating neoplasm	5 cases	
C	5 (4 alive, 1 dead)	
<i>Mediastinal</i>			
A	6 cases	
B	3 (3 dead)	
C	2 (2 dead)	
	1 (alive)	
<i>Secondary Extension from abdomen</i>			
A	13 cases	
B	3 (3 dead)	
C	4 (4 dead)	
	6 (4 alive, 2 dead)	
<i>Extension from neck</i>			
B	2 cases	
C	1 (dead)	
	1 (alive)	
<i>Metastatic Pyaemia</i>			
C	2 cases	
	2 (2 alive)	
<i>Chest wall</i>			
A	5 cases	
B	2 (2 dead)	
C	3 (3 alive)	
<i>Cardiac</i>			
..	No cases	
<i>Total cases</i>			
A	85	
	29 (4 alive, 23 dead, 2 not traced)	
B	14 (14 dead)	
C	42 (36 alive, 6 dead)	

SUMMARY AND CONCLUSIONS

This paper is based on the study of 85 cases of thoracic actinomycosis.

The course of thoracic actinomycosis is traced from its first clinical description in 1882.

Difficulties in treatment, and confusion regarding the nomenclature of this disease are described, and the name for the causative organism established as *Actinomyces israeli*.

The extensive literature on the subject is reviewed, with particular reference to the various forms of therapy.

A new classification for thoracic actinomycosis is presented.

The various aspects of the aetiology are discussed stressing the aspiration of infected material from teeth and tonsils.

Clinical cases are presented illustrating the different varieties in our classification.

The epidemiology and pathology are discussed, and the specific histological reactions produced in the lungs by *Actinomyces israeli* are illustrated.

The diagnosis is discussed under three main headings.

Penicillin is the most effective therapy, provided it is given in adequate dosage for a sufficient length of time.

The results of treatment are given for the 85 cases in this series.

We should like to thank the following physicians and surgeons who have kindly allowed us to include their cases: Mr. A. L. d'Abreu, Prof. P. Allison, Mr. Hedley Atkins, Mr. R. S. Barclay, Mr. J. R. Belcher, Sir Russell Brock, Prof. R. V. Christie, Mr. W. P. Cleland, Dr. Maurice Davidson, Mr. H. Morriston Davies, Dr. Vernon Davies, Mr. J. Dobson, Mr. A. Eckhoff, Mr. F. Ronald Edwards, Mr. A. W. Fawcett, Mr. G. Flavell, Dr. H. M. Foreman, Dr. A. W. Franklin, Mr. J. S. Glennie, Mr. Kent Harrison, Dr. E. Hayward, Mr. J. P. Hosford, Dr. L. E. Houghton, Dr. J. P. Hurford, Mr. J. Jemson, Dr. P. F. Lee Lander, Mr. G. Mason, Dr. J. Maxwell, Dr. F. H. Packer, Mr. C. Parish, Mr. Laurie Pile, Mr. W. H. C. Romanis, Prof. Sir James Paterson Ross, Dr. R. Bodley Scott, Mr. T. Holmes Sells, Dr. G. Simon, Mr. Tom Smiley, Dr. K. Tallerman, Mr. Dillwyn Thomas, Sir Clement Price Thomas, Mr. Vernon Thompson, Mr. O. S. Tubbs, Prof. A. G. Watkins.

Our special thanks are due to Mr. O. S. Tubbs, who has given us every possible help and encouragement in the preparation of this paper.

Professor L. P. Garrod has carried out the bacteriological studies on many of the patients in this series, and to him we are particularly grateful.

Dr. J. F. Heggie, of the North Middlesex Hospital, has kindly contributed the section dealing with morbid anatomy and histology.

The colour photomicrographs are the work of Mr. H. Knight, of Chase Farm Hospital.

Mr. C. M. Cook, of the Photographic Department of the Royal Society of Medicine, took the colour photograph of the pneumonectomy specimen.

We are grateful to the Edmonton Group Hospital Management Committee, and to Messrs. Glaxo Laboratories, Ltd., for contributions towards the colour reproductions.

REFERENCES

- Adamson, C. A., and Hagerman, G. (1948). *Acta med. scand.*, **131**, 23.
- Arnim, H. H. von (1949). *Beitr. Klin. Tuberk.*, **101**, 595.
- Auspaugh, A. W. (1945). *J. Okla. med. Ass.*, **38**, 368.
- Ayberk, H. (1953). *Türk. Tıp. Cem. Mec.*, **19**, 513.
- Barker, C. S. (1954). *Canad. med. Ass. J.*, **71**, 332.
- Bell, F. G., Mantell, F. J., Netzer, S., and Jaffe, B. (1944). *Med. Bull. Veterans' Adm.*, **21**, 201.
- Benbow, E. P., Smith, D. T., and Grimson, K. S. (1944). *Amer. Rev. Tuberc.*, **49**, 395.
- Bigland, A. D., and Sergeant, F. C. H. (1923). *Brit. med. J.*, **2**, 61.
- Bigard, J. D. (1939). *J. thorac. Surg.*, **8**, 570.
- Blainey, J. D., and Morris, E. O. (1953). *Brit. med. J.*, **2**, 913.
- Boand, A., and Novak, M. (1949). *J. Bact.*, **57**, 501.
- Bollinger, O. (1877). *Zbl. med. Wiss.*, **15**, 481.
- Bonnet, D. (1921). *Int. Clin.*, 31 ser., **3**, 34.
- Bostroem, E. (1890). *Beitr. path. Anat.*, **9**, 1.
- Campbell, D. A., and Bradford, B. (1948). *Arch. Surg. (Chicago)*, **57**, 202.
- Canali, L. (1882). *Riv. clin. Bologna*, p. 576.
- Capitolo, G. (1951). *Minerva chir. (Torino)*, **6**, 561.
- Christie, R. V., and Garrod, L. P. (1944). *Brit. med. J.*, **1**, 513.
- Coenegrachts, J., and Keil, C. (1954). *Rev. med. Liège*, **9**, 37.
- Colebrook, L. (1921). *Lancet*, **1**, 893.
- Cope, Z. (1915). *Brit. J. Surg.*, **3**, 55.
- (1930). *Proc. roy. Soc. Med.*, **23**, 866.
- (1938). *Actinomycosis*. Oxford Univ. Press, London.
- (1939). *Practitioner*, **142**, 319.
- (1949). *Brit. med. J.*, **2**, 1311.
- Cornell, A., and Shookhoff, H. B. (1944). *Arch. intern. med.*, **74**, 11.
- Cutler, E. C., and Gross, R. E. (1940). *Amer. Rev. Tuberc.*, **41**, 358.
- Davis, M. I. J. (1941). *Amer. J. Surg.*, **52**, 447.
- Dean, G. (1912). *Brit. med. J.*, **2**, 1303.
- Delarue, J. (1954). *Sem. Hôp. Paris*, **30**, 917.
- and Houdard, P. (1949). *J. franç. Méd. Chir. thorac.*, **3**, 211.
- Desjardins, A. U. (1928). *Radiology*, **11**, 321.
- Dobson, L., and Cutting, W. C. (1945). *J. Amer. med. Ass.*, **128**, 856.
- Holman, E., and Cutting, W. (1941). *Ibid.*, **116**, 272.
- Eppinger, H. (1890). *Beitr. path. Anat.*, **9**, 287.
- Etter, L. E., and Schumacher, F. L. (1939). *J. Amer. med. Ass.*, **113**, 1023.
- Florey, M. E., and Florey, H. W. (1943). *Lancet*, **1**, 387.
- Foulerton, A. G. (1913). *Proc. roy. Soc. Med. (Surg. Sect.)*, **6**, 132.
- Garrod, L. P. (1952a). *Brit. med. J.*, **1**, 1263.
- (1952b). *Tubercle (Lond.)*, **33**, 258.
- Good, L. P. (1930). *Arch. Surg. (Chicago)*, **21**, 786.
- (1934). *Tex. St. J. Med.*, **30**, 245.
- Harbitz, F., and Grondahl, N. B. (1911). *Amer. J. med. Sci.*, **142**, 386.
- Harris, A. M., and Priestley, J. B. (1944). *J. Lab. clin. Med.*, **29**, 815.
- Harsha, W. M. (1904). *Ann. Surg.*, **39**, 459.
- Harz, C. O. (1877). *Central Thierarzneischule zur Munchen*, p. 125.
- Heller, A. (1954). *Med. Klin.*, **49**, 1475.
- Heyerdahl, S. A. (1914). *Nord. Tidsskr. Terapi*, **12**, 169.
- Hodenpyl, E. (1890). *Med. Rec. (N.Y.)*, **38**, 653.
- Hollis, W. J., and Hargrove, M. D. (1947). *New Orleans med. surg. J.*, **99**, 499.
- Israël, J. (1878). *Virchows Arch. path. Anat.*, **74**, 15.
- (1879). *Ibid.*, **78**, 421.
- (1887). *Arch. Klin. Chir.*, **34**, 160.
- Jacob, F. H. (1944). *Brit. med. J.*, **1**, 266.
- Jones, T. E., and Brownell, T. S. (1945). *Cleveland Clin. Quart.*, **12**, 32.
- Kay, E. B. (1946). *Ann. Surg.*, **124**, 535.
- (1947). *Ann. intern. Med.*, **26**, 581.
- and Meade, R. H. (1945). *J. Amer. med. Ass.*, **129**, 200.
- Keeney, E. L., Ajello, L., and Lankford, E. (1944). *Bull. Johns Hopk. Hosp.*, **75**, 410.
- Kirklin, B. R., and Hefke, H. W. (1931). *Amer. J. Surg.*, **13**, 1.
- Koerth, C. J., Donaldson, J. M., and Pinson, C. C. (1942). *Dis. Chest*, **8**, 107.
- Kolouch, F., and Peltier, L. F. (1946). *Surgery*, **20**, 401.
- Kugel, E., Harlacher, A., and Hueck, O. (1953). *Thoraxchirurgie*, **1**, 206.
- Ladd, W. E., and Bill, A. H. (1943). *New Engl. J. Med.*, **229**, 748.
- Lawonn, H. (1953). *Z. ges. inn. Med.*, **8**, 120.
- Lemon, W. S. (1926). *Minn. Med.*, **9**, 211.
- Lidbeck, W. (1942). *West. J. Surg.*, **50**, 498.
- Littman, M. L., Paul, J. S., and Fusillo, M. H. (1952). *J. Amer. med. Ass.*, **148**, 608.
- Lynch, J. P., and Holt, R. A. (1945). *Ann. intern. Med.*, **23**, 91.
- Lyons, C., Owen, C. R., and Ayers, W. B. (1943). *Surgery*, **14**, 99.
- McHardy, G., and Browne, D. C. (1943). *Sth. med. J. (Bgham, Ala.)*, **36**, 674.
- Meurers, M. (1951). *Mtschr. Kinderheilk.*, **99**, 386.
- Mitchell, H. S. (1942). *Canad. med. Ass. J.*, **46**, 584.
- Moore, M. (1947). *Postgrad. Med.*, **1**, 281.
- Morton, H. S. (1940). *Canad. med. Ass. J.*, **42**, 231.
- Myers, H. B. (1937). *J. Amer. med. Ass.*, **108**, 1875.

- Neuber, E. (1940). *Klin. Wschr.*, **19**, 736.
- Nichols, D. R., and Herrell, W. C. (1947). *J. Lab. clin. Med.*, **32**, 1405.
- Nocard, M. E. (1888). *Ann. Inst. Pasteur*, **2**, 293.
- Nowski, S. (1953). *Ther. d. Gegenw.*, **92**, 146.
- Ocklitz, H. W. (1952). *Ibid.*, **91**, 291.
- Petříková, J., and Vaněček, R. (1953). *Cas. Lék. ces.*, **92**, 559.
- Poncet, A., and Bérard, L. (1898). *L'Actinomyose Humaine*. Masson, Paris.
- Ponfick, E. (1882). *Die Actinomykose des Menschen*. Hirschwald, Berlin.
- Poppe, J. K. (1946). *J. thorac. Surg.*, **15**, 118.
- Preston, T. W. (1928). *Brit. med. J.*, **2**, 1172.
- Pütz, L. (1954). *Medizinische*, **1**, 819.
- Pyper, R. A. (1947). *Ulster med. J.*, **16**, 132.
- Rabin, C. B., and Janowitz, H. D. (1950). *J. thorac. Surg.*, **19**, 355.
- Reitter, H. (1954). *Zbl. Chir.*, **79**, 993.
- Rivas, A. E. (1952). *Sem. méd. (B. Aires)*, **100**, 447.
- Roberts, J. E. H., Tubbs, O. S., and Bates, M. (1945). *Lancet*, **1**, 39.
- Robinson, S. S., and Tasker, S. (1949). *Ann. west. Med. Surg.*, **3**, 55.
- Rumrich, A. (1953). *Dtsch. med. Wschr.*, **78**, 854.
- Sanford, A. H., and Voelker, M. (1925). *Arch. Surg. (Chicago)*, **11**, 809.
- Scarinci, C. (1953). *Policlinico. Sez. prat.*, **60**, 814.
- Schmitt, G. F., and Olsen, A. M. (1941). *Proc. Mayo Clin.*, **16**, 506.
- Shaw, F. W., Holt, R. A., and Ray, E. S. (1946). *Va med. Mon.*, **73**, 362.
- Shulman, H. (1944). *Med. Bull. Veterans' Adm.*, **21**, 230.
- Smith, E. G. (1934). *Amer. J. Radiol.*, **31**, 823.
- Sokolow, K. V. (1889). *Vo.-sanit. Delo St. Petersburg*, **9**, 9.
- Staub-Oetiker, H. (1921). *Schweiz. med. Wschr.*, **2**, 961.
- Stewart-Harrison, R. (1934). *Brit. J. Radiol.*, **7**, 98.
- Suteev, G. O. (1949). *Khirurgija*, No. 8, p. 42.
- Sznajder, W. (1953). *Pol. Przegl. radjol.*, **17**, 95.
- Torek, F. (1926). *Arch. Surg. (Chicago)*, **12**, 385.
- Torrens, J. A., and Wood, M. W. W. (1949). *Lancet*, **1**, 1091.
- Trevithick, E. (1906). *Ibid.*, **2**, 158.
- Tubbs, O. S., and Turner, J. W. A. (1937). *St. Bart's Hosp. J.*, **44**, 184.
- Vinson, P. P., and Sutherland, C. G. (1926). *Radiology*, **6**, 63.
- Walker, J. M., and Hamilton, J. W. (1945). *Ann. Surg.*, **121**, 373.
- Wangenstein, O. H. (1932). *J. thorac. Surg.*, **1**, 612.
- (1936). *Ann. Surg.*, **104**, 752.
- Watkins, A. G. (1944). *Arch. Dis. Childh.*, **19**, 143.
- West, S. (1897). *Trans. path. Soc. Lond.*, **48**, 17.
- Wilkinson, E. E. (1941). *J. Pediat.*, **18**, 805.
- Williams, I. G. (1944). *Proc. roy. Soc. Med.*, **37**, 719.
- Wolff, M., and Israël, J. (1891). *Virchows Arch. path. Anat.*, **126**, 11.
- Wright, J. H. (1905). *J. med. Res.*, **13**, 349.
- Wynn, W. H. (1908). *Brit. med. J.*, **1**, 554.
- Zoeckler, S. J. (1951). *Circulation*, **3**, 854.